

研究成果の刊行物・別刷

Treatment Options in Patients with Prion Disease - the Role of Long Term Cerebroventricular Infusion of Pentosan Polysulphate

Nikolai G. Rainov^{1,2}, Ian R. Whittle³ and Katsumi Doh-ura⁴

¹Department of Neurological Science, The University of Liverpool, Lower Lane, Liverpool, L9 7LJ, UK ²The Walton Centre for Neurology and Neurosurgery NHS Trust, Liverpool, UK ³Department of Clinical Neuroscience, Western General Hospital, Edinburgh, UK ⁴Department of Prion Research, Tohoku University Graduate School of Medicine, Sendai, Japan
<e-mail> rainov@liv.ac.uk

Summary. Prion diseases (PrD), also known as transmissible spongiform encephalopathies, are believed to be caused by accumulation of an abnormal isoform of the prion protein (PrP^{sc}) in the central nervous system. Creutzfeldt-Jacob disease (CJD) in its sporadic and variant form is the most frequent and clinically important PrD. At present there is no proven specific or effective treatment available for any form of CJD, although some oral agents, such as quinacrine or flupirtine, are being investigated in clinical trials.

Pentosan polysulphate (PPS), a large polyglycoside molecule with weak heparin-like activity, has been shown to prolong the incubation period of PrP^{sc} infection when administered to the cerebral ventricles in a rodent scrapie model. PPS also prevents the production of further PrP^{sc} in cell culture models. However, PPS penetrates poorly the blood-brain barrier and only a minor fraction of orally administered drug may reach the CNS. These properties of PPS prompted its cerebroventricular administration in patients with vCJD and other PrD, such as iatrogenic CJD and Gerstmann-Sträussler-Scheinker syndrome (GSS). Long-term continuous infusion of PPS at doses of up to 110 $\mu\text{g}/\text{kg}/\text{d}$ did not cause serious drug-related side effects. Follow-up CT and MRI imaging demonstrated that brain atrophy may progress further during PPS administration, while the neurological status may remain stable. Proof of clinical efficacy has not been the aim of the current clinical studies of PPS, however one patient with vCJD survived for 23 months after initial symptoms and 39 months after diagnosis, while the median duration of illness with vCJD is 13 months (range 6-39).

Some lessons have been learned from the early studies of application of PPS in PrD patients. Surgery in a brain affected by PrD may result in a higher rate of surgical complications than might be expected in analogous cases with other conditions. Secondly, efficacy of PPS or any other treatment option in advanced PrD cases will be very difficult to assess, due to the lack of specific and objective criteria for measurement of response. Overall survival may remain therefore one of the few objective ways of assessing outcome in treated patients. Finally, if clinically significant benefits to patients are to be expected, PPS administration should start as early as possible in the course of the respective disease and before irreversible loss of neurological function has occurred. Further clinical, neuroradiological and laboratory investigations of cerebroventricular PPS administration in the setting of a prospective clinical study will be essential for the assessment of possible clinical benefits of PPS in PrD.

Key words. GSS syndrome, pentosan polysulphate, prion disease, sporadic CJD, transmissible spongiform encephalopathy, quinacrine, variant CJD

Introduction

Significant research interest has been attracted recently by human pathological conditions related to transmitted or intrinsically generated pathologic prion protein. Prion diseases (PrD) have thus a common and unique biological background, but a variable clinical manifestation of the presumably common pathogenetic mechanism. PrD, also known as transmissible spongiform encephalopathies (TSE), are fatal neurodegenerative disorders with different clinical forms including sporadic, inherited, and acquired diseases, the latter including transmissible and iatrogenic forms [1]. All forms of PrD have in common an abnormal metabolism of the prion protein, PrP^c, which results in the production of uncleavable, protease-resistant isoforms, PrP^{sc}, accumulating mostly in the CNS and causing neuronal dysfunction and eventually death. Prion diseases can affect both humans and animals and include such conditions as Creutzfeldt-Jakob disease (CJD), Gerstmann-Sträussler-Scheinker (GSS) syndrome, kuru, and fatal familial insomnia (FFI) in humans, bovine spongiform encephalopathy (BSE) or “mad cow disease” in cattle, scrapie in sheep, and chronic wasting disease in mule, deer, and exotic ungulates [1].

The normal physiologic isoform of the prion protein, PrP^c, is found in the body of all mammals. The *Prnp* gene encodes a polypeptide which undergoes glycosylation in the rough endoplasmic reticulum and then gly-

cosyl modification in the Golgi apparatus of the cell. Because of this glycosylation, it is expected that the glycosyl structure of the protein in different cells would be different [2]. The glycosylated PrP^c protein, associated at the C-terminus with a glycosyl phosphatidyl-inositol (GPI), is transported to the surface of the cell membrane. The half-life of PrP^c on the membrane of cells grown in culture is 3-6 hrs, after which it is internalised and degraded in the endolysosome compartment [3, 4]. A shorter peptide form of PrP^c may be recycled to the surface of the cell before lysosomal destruction. Conversion between PrP^c and PrP^{sc} occurs likely during the internalisation process. The specific physiologic function of PrP^c is largely unknown, although studies suggest it may play a role in copper binding and oxidative metabolism [5], interactions with the extracellular matrix, apoptosis, and signal transduction [6]. It is evolutionary conserved, which suggests an important physiologic role, but mice lacking PrP^c appear to grow and function normally [7].

The pathologic form of the prion protein, which is the causative agent "prion" of all PrD, is an abnormally folded isoform of the cellular prion protein PrP^c, known as PrP^{sc}. PrP^{sc} accumulates mostly in the brain of affected mammals [8, 9]. The underlying pathological process involves a post-translational conformational change PrP^c into PrP^{sc} [10, 11]. PrP^c is usually present in an α -helix conformation, in pathologic conditions only a small fraction of PrP^c is folded as α -helix, while the vast majority is present in an unfolded β conformation (β -helix PrP^{sc}). The precise molecular mechanism responsible for this unfolding process is not known, but two models are favoured (for review see [12]). One model suggests that PrP^{sc} acts like a crystal seed for the further addition of converted PrP^{sc} molecules and the subsequent formation of PrP^{sc} aggregates [13], whereas the other model postulates conversion intermediates involving a putative PrP^c-PrP^{sc} heterodimer complex [8, 14]. The claim that the PrP^{sc} is an infective agent involves the demonstration that the PrP^{sc} form can itself modify the structure of PrP^c to PrP^{sc} *in vitro*, however, this modification is inefficient [15]. Recent results suggest that single-stranded RNA molecules are necessary for PrP^{sc} amplification, and that RNA from invertebrates fails to support pathologic prion amplification *in vitro* [16].

PrP^{sc} is only found in infective animals, and mice without PrP^c production cannot become infected or infective [7]. PrP^{sc} appears to accumulate within lysosomes, growing insoluble crystalloid fragments. Initially, PrP^{sc} builds up intracellularly and then it is seen extracellularly as amyloid in histopathologic sections stained with Congo red. Microglia is activated by contact with amyloid plaques and insoluble extracellular PrP^{sc}, which results in local production and release of cytokines, reactive oxygen species, and

glutamate [17, 18]. These compounds give rise to specific local neuronal damage and apoptosis, seen as spongiform defects in the brain. Apoptosis and oxidative damage in neurons seem to follow their local exposure to cytokines [19, 20], and physiological neuronal activity is expected to be severely impaired well in advance of histopathologic changes. The progressive, slow build-up of PrP^{sc} may mean that only tissues where cells are not involved in a continuous turnover are likely to exhibit functional and morphological damage. Although cells of the immune system are also infected by PrP^{sc}, their cellular turnover is considered to prevent the body showing any immunodeficiency; whereas neurons infected with and accumulating PrP^{sc} are damaged but not replaced, and hence long term neurological deficits become clinically manifest.

While the prime target of PrP^{sc}-caused damage seems to be neuronal, massive neuronal loss is not always seen in PrD. On the other hand, activation of astrocytes occurs very early in the course of prion infection of the CNS in a consistent fashion. It can be reproduced easily in experimental models and leads to significant physiological effects such as impairment of the blood-brain barrier [21]. In addition, astrocytes are one of the few cell types capable of supporting prion replication [22]. Microglial cells are another cell type increasingly implicated in brain damage due to prion infection. Experiments indicate that activation of microglia may be essential in causing neuronal damage in PrD, and that this phenomenon is dependent on the expression of PrP^c [17]. Moreover, microglial activation and accumulation in affected brain areas precede neuronal cell death and parallel the temporal and spatial pattern of PrP^{sc} deposition [23]. Histologically, common late stage lesions in the CNS are neuronal loss, spongiosis and astrogliosis, accompanied by an accumulation of microglia and, occasionally, the presence of amyloid plaques and various small deposits of prion protein [24]. For a definitive diagnosis of human PrD, histopathologic assessment of the CNS is essential [25].

Sporadic CJD was originally described in 1921 and occurs mostly in individuals between 40-80 years of age, with an incidence of approximately one case per million per year. Patients suffering from CJD show a wide spectrum of clinical symptoms within a few distinctive forms of the disease [26]. While most of the CJD cases at present are sporadic, CJD may also occur as a familial form in no more than 10% of sporadic cases [27]. It follows an autosomal dominant pattern of transmission, with 70% of the patients having mutations in codons 178 or 200 of the *Prnp* gene.

Iatrogenic transmission of CJD has been proven in more than 200 cases in relation to corneal transplants, dura mater grafts, and hormones purified from human glands [28, 29].

FFI and GSS are also inherited by autosomal dominance. Both are very rare, with no more than 10 known families with FFI and 50 with GSS [30, 31]. GSS, unlike other PrD, may have a longer clinical course [32]. It is characterised by missense mutations of the *Prnp* gene, by specific neuropathological lesions and multicentric amyloid plaques.

The most recently recognized form of PrD in humans, new variant CJD (vCJD), was first described in 1996 as linked to BSE [33]. What distinguishes vCJD from sporadic cases is that the age of patients is much lower (vCJD age range 19-39 years, versus sCJD age range 55-70 years) and the duration of illness is longer (vCJD 7.5-22 months, versus sCJD 2.5-6.5 months). Variant CJD displays a distinct pathology characterised by abundant florid plaques surrounded by vacuolation [34]. Most cases of vCJD have been observed in the UK. In addition, all investigated cases of vCJD showed homozygosity of methionine at codon 129 [35, 36].

The clinical features of PrD are extremely heterogeneous and may include rapidly progressive dementia, psychiatric symptoms (mostly in vCJD, less in CJD), cerebellar syndrome (in kuru, GSS, CJD), movement disorders (myoclonus, dystonia, chorea, mostly in vCJD), encephalopathy (in CJD), pyramidal signs, cortical blindness, and sensory symptoms (hyperpathia, mostly in vCJD) [26, 32, 37, 38].

Treatment options in prion disease

PrD are still uniformly fatal, some within weeks to months from diagnosis, while vCJD patients may survive for more than a year, and GSS patients for up to 6 years. No specific treatments for PrD are known, although some prophylactic and neuroprotective agents have been proposed on the basis of cell culture experiments and animal studies [39-42]. Animal studies indicate that substantial neuropathological changes in PrD are already present before the onset of symptoms and are spatially related to PrP^{sc} deposits. Ideally, an effective intervention should start during the preclinical stage of disease, and be aimed at preventing PrP^{sc} neuroinvasion or propagation in the CNS. Unfortunately, no tests are available currently to detect asymptomatic PrD, except for carriers of pathogenic mutations of the *Prnp* gene.

Inhibition of PrP^{sc} formation may be achieved, at least in laboratory experiments, through one of the following strategies:

- Abrogation of PrP^c synthesis or prevention of its transport to the cell surface
- Stabilisation of the PrP^c structure to make its conformational change unfavourable

- Sequestration of PrP^{Sc}
- Reversion of PrP^{Sc} to a protease-sensitive form
- Interference with the interaction between PrP^C, PrP^{Sc}, and other macromolecules involved in the conversion process (for review see [43]).

However, most compounds that have shown some effectiveness in cell culture or in animal models of PrD only work when administered at the time of infection or shortly thereafter. The heterogeneity and complexity of PrD suggest that a combination of several compounds with different modes of action may be necessary for their prevention and treatment. Preclinical diagnostic tests for PrD are urgently needed and deemed crucial in the success of an early treatment.

Antibiotics, dyes, and NMDA receptor ligands

The polyene macrolide antibiotic, amphotericin B [44, 45], and its less toxic derivative, MS-8209 [46], have been shown to delay scrapie agent propagation and PrP^{Sc} accumulation in mice or hamsters. The amyloid-binding dye, Congo red, is able to inhibit PrP^{Sc} accumulation and replication, most likely by overstabilising the abnormal conformational isoform [47, 48]. The anthracycline 4-iodo-4-deoxy-doxorubicin has been found to delay hamster scrapie progression via binding to amyloid fibrils [49]. Suramin, a highly sulphated urea based compound, and dapsone, a sulphone, were also tested against mouse scrapie and found to increase the incubation period when given continuously [50, 51]. Porphyrins and phthalocyanins as sulphated forms also were shown to inhibit the production of PrP^{Sc} in neuroblastoma cell cultures [52, 53].

The neurotoxic effect displayed by PrP^{Sc} and its fragments was found to be prevented *in vitro* by antagonists of NMDA receptor channels, such as memantine [17, 54]. Moreover, flupirtine, a triaminopyridine compound clinically used as non-opioid analgesic drug, which acts like an NMDA receptor antagonist, but does not bind to the receptor, was found to display a strong cytoprotective effect on neurons treated with PrP^{Sc} or with a toxic fragment [54, 55]. A double-blind placebo-controlled study has been carried out in 28 CJD patients [56]. Patients treated with flupirtine showed significantly less cognitive changes (dementia) than placebo patients, which led the authors to conclude that flupirtine may have beneficial effects on the cognitive function of patients with CJD [56]. The study did not investigate other aspects of neurological deterioration in progressive CJD, the results appear therefore of limited usefulness.

Active and passive immunisation

Several studies have suggested that antibodies (Ab) might have beneficial anti-prion properties in infected cells [42, 57]. Auto-antibodies can be induced in PrP^c-expressing mice and have the potential to cure cells after prion infection [58, 59]. Furthermore, in transgenic mice expressing both PrP^c and a defined anti-PrP^c antibody, prion infectivity within the spleen is significantly reduced [60]. Peretz et al. (2001) investigated seven different recombinant antibodies raised to various parts of the normal PrP^c protein [61]. They exposed a mouse neuroblastoma cell line (ScN2a) infected with PrP^{sc} to varying concentrations of each Ab and measured the amount of PrP^{sc} protein. The most potent Ab prevented conversion of PrP^c to PrP^{sc} and also cleared pre-existing PrP^{sc} in a dose-dependent manner. Removal of Ab after 2 weeks of treatment left cultures free of prion infectivity for an additional 4 weeks [61].

Recent work by White et al. (2003) suggested that another approach, passive application of anti-PrP^c antibodies, could be effective [62]. Monoclonal antibodies (mAb) were generated in non-tolerant PrP^c-knockout mice and exhibited different specificities towards PrP^c and PrP^{sc}. Mice were infected with PrP^{sc} by the intraperitoneal (i.p.) or intracerebral routes (i.c.), and mAb were injected i.p. twice per week, starting a few weeks after infection. In mice infected with prion by the i.p. route, mAb treatment produced a dose and time dependent reduction in PrP^{sc} and prion infectivity, and a significant prolongation of survival. Interestingly, the largest effects were obtained with the mAb mainly reacting with PrP^c. However, the protective effect of mAb was only observed when prions were applied by the i.p. route, whereas prion infections caused by i.c. inoculation were not influenced by mAb treatment. This suggested that the antibody cannot cross the blood-brain barrier at a sufficient concentration to exert a protective function [62].

It remains however unclear whether the above findings in cell culture and mice are transferable to humans, given the fact that the exact mode and time point of prion infection are usually unknown. In addition, in most of the mouse studies, a very high dose of mAb was applied in a continuous fashion (for review see [42]), which may produce allergic reactions and also result in inactivating antibodies in human patients.

Quinacrine and chlorpromazine

The antimalarial drug quinacrine (mepacrine), a cyclic tetrapyrrole, and the antipsychotic chlorpromazine (Figure 1) were shown to prevent the conversion of PrP^c to PrP^{sc} in cell culture. Doh-ura et al. (2000) reported that lysosomotropic agents (e.g. quinacrine or chloroquine) inhibited protease-resistant prion protein accumulation in scrapie-infected murine neuroblastoma cells (ScNB). The inhibition occurred without apparent effects on normal PrP^c biosynthesis or turnover, and without direct interactions with prion protein molecules [63]. Similar effects of quinacrine were reported later by Korth et al. (2001). These authors cultured mouse neuroblastoma cells (ScN2a) infected with PrP^{sc} to show that 6 days of treatment with quinacrine or chlorpromazine was able to reduce the conversion of PrP^c to PrP^{sc} [64].

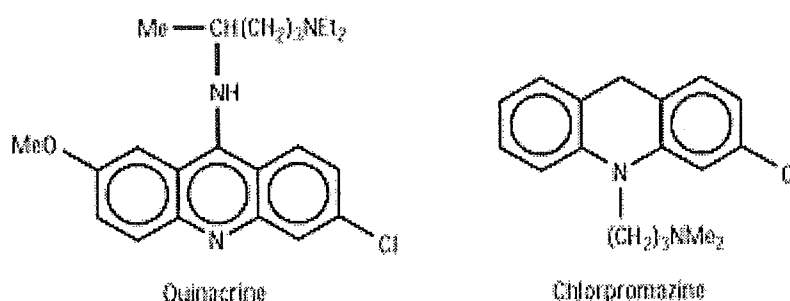


Figure 1. Chemical structure of quinacrine and chlorpromazine

Quinacrine has been used in humans for over 60 years to treat malaria, and can be administered orally at high doses on a daily basis. The currently suggested oral dose for CJD patients is however higher than the antimalarial dose and may produce significant side effects in a considerable proportion of the treated patients. Chlorpromazine, although less potent than quinacrine in cell culture, crosses the blood-brain barrier to a larger extent.

Turnbull et al. (2003) showed that quinacrine also may act as an effective antioxidant, readily scavenging hydroxyl radicals generated during incubation of toxic PrP^{sc} fragments with murine neurons [65]. Quinacrine also significantly reduced toxicity of the PrP¹⁰⁶⁻¹²⁶ peptide fragment in these cells. On the other hand, Collins et al. (2002) evaluated oral quinacrine in mice infected with PrP^{sc}, but were not able to demonstrate any significant effect of the drug on overall survival of treated animals compared to controls [66]. Barret et al. (2003) also examined the efficacy of quinacrine and chlorpromazine in different *in vitro* models and in an experimental murine

model of BSE [67]. Despite the inhibition of PrP^{sc} accumulation in ScN2a cells, quinacrine was unable to produce a detectable effect in the animal model.

Japanese researchers are carrying out an ongoing clinical study of oral quinacrine in patients with sporadic and iatrogenic CJD. Results in the first 4 patients have been published recently [68]. Quinacrine (300 mg/d) has been administered for 3 months. Improved arousal level of patients with akinetic mutism, and restored eye contact or voluntary movements in response to stimuli were described. Clinical improvement was however transient, lasting 1-2 months. Quinacrine at the above dose caused liver dysfunction and skin pigmentation in all cases [68]. Further results in a larger patient population should be presented in near future.

A prospective clinical study of quinacrine in PrD, the PRION-1 study [69], is currently enrolling patients in the UK (Figure 2). Patients aged 12 years and older with all types of PrD are eligible. The study protocol features a partially randomised design, with patients who opt for quinacrine treatment split in two arms according to their preference for immediate vs. deferred (by 24 weeks) treatment. Treated patients will receive a loading dose of quinacrine (1 g on the first day), followed by 300 mg/d as a long term dose. The primary efficacy endpoints are mortality and the proportion of responders overall and at 24 weeks. Response is defined as independently rated lack of deterioration, global impression of change (based on the Clinician's Interview Based Impression of Change, CIBIC-plus), and patients score on the Brief Psychiatric Rating Scale (BPRS). Secondary efficacy endpoints are neurological and neuropsychological changes, including changes in markers of disease activity, MRI, and EEG [69].

Routine follow-up will be identical for all patients participating in the PRION-1 trial, with the exception of patients with inherited PrD, who have longer disease duration and will be followed up less frequently. Follow-up assessments are taking place monthly for the first 6 months, then every 3 months until end of study. Assessments will include medical history, physical examination, liver function and blood clotting, neurological examination recorded on video, and a series of neurological assessments. The study accrual target is 160 patients. Currently 18 patients have been enrolled [69].

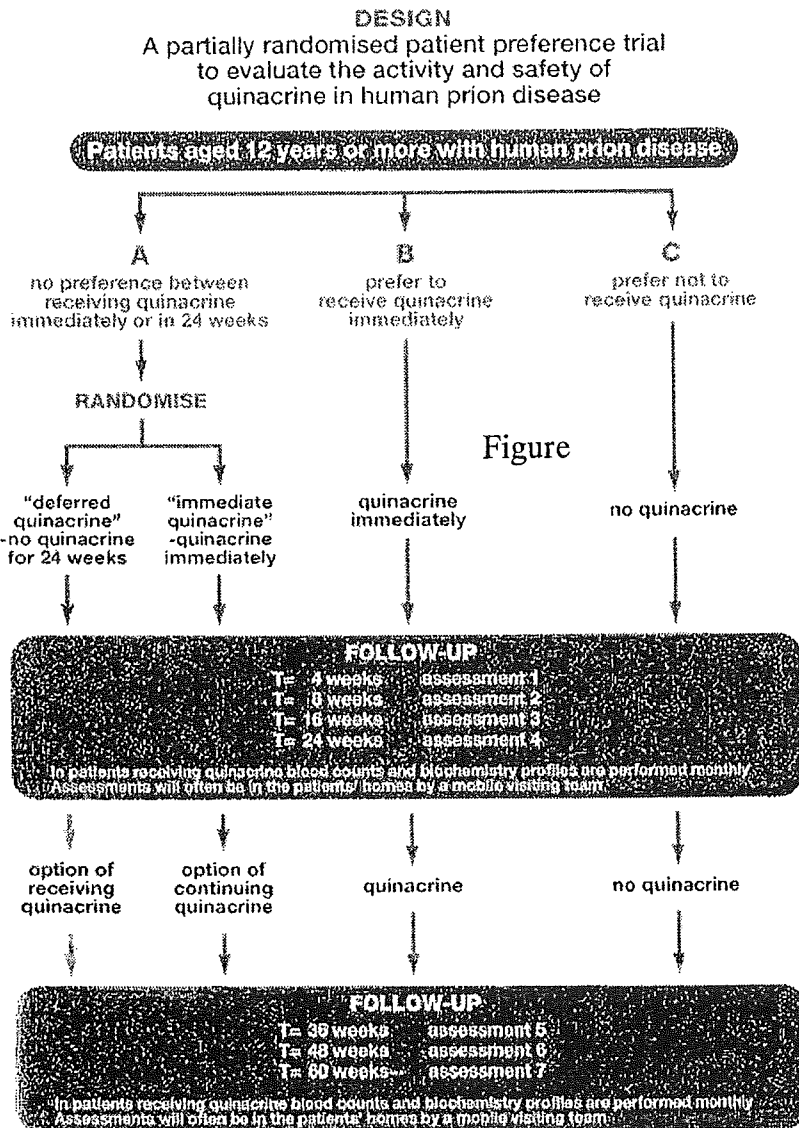


Figure 2. Flow chart of the PRION-1 trial of quinacrine in patients with PrD [69].

Polysulphonated glycosides (glycans)

Several polysulphonated polysaccharides, including pentosan polysulphate (PPS) (Figure 3) and dextran sulphate (DS), have been shown to prolong the incubation period in PrP^{Sc} infected rodents if given before infection [70-72], and to inhibit PrP^{Sc} accumulation in neuroblastoma cells [73]. The effects of these polyanions may be due to an inhibition of the formation of PrP fibrils [74] or to reduction of the amount of PrP^C on the cell surface by stimulating

endocytosis of PrP^c [52]. Sulphonated polyglycosides are not known to penetrate the CNS, and hence the first attempts to demonstrate their effects were made in peripheral organs [75].

Caughey and Raymond (1993) tested various polysulphonated glycosides (PG) and found PPS, carrageenan, and dextran sulphate 500 (DS500) to be highly active in the inhibition of PrP^{sc} production [73]. PPS was most active, showing half of its maximal activity at 1 ng/ml. Shyng et al. (1995) reported PPS and related compounds to cause a decrease of PrP^c on the surface of cultured chicken and mouse neuroblastoma cells. PPS caused a redistribution of PrP^c from the surface to the interior of the cell (intracellular late endosomes). The differences in the binding strength of PrP^c to PPS and to other PG were found to parallel their *in vivo* and *in vitro* anti-PrP^{sc} formation potency [52]. Ehlers and Diring (1984) inoculated mice i.p. or i.c. with scrapie agent and treated them systemically with DS500 [76]. None of the i.c. inoculation experiments were affected by the treatment. With i.p. inoculations, however, it was seen that DS500 did decrease (by approximately one order of magnitude) the infectivity found in the spleen at various times after single injection of the drug, and significantly prolonged incubation times. Treated mice also showed a significant increase in the mean incubation period compared with controls. It was noted that DS500 remained in the body of an inoculated mouse for up to 7 months. A maximum effect was seen when the drug was given at the same time with the infection, and no effect was seen when it was given 35 days after infection [76].

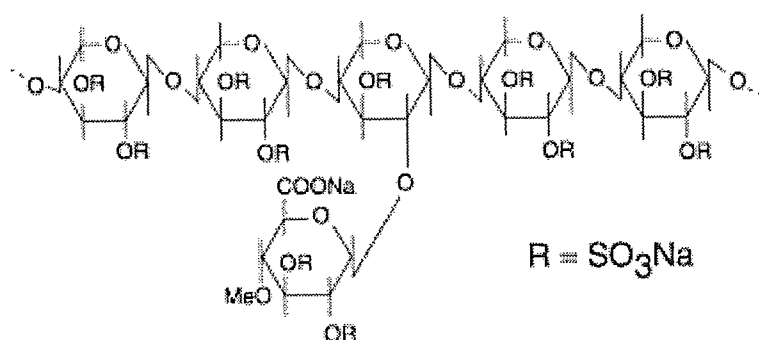


Figure 3. Chemical structure of pentosan polysulphate (PPS)

This work was followed by the study of Farquhar and Dickinson (1986), who carried out a series of murine experiments to inoculate i.p. scrapie [75]. This was associated, at various times before and after the scrapie inoculum, with various quantities of DS500 as a single i.p. injection. It was found that DS500 reliably increased the incubation period of the disease, and that this did not seem to depend on the strain of disease or the inbred strain of mouse

used. The effect seemed to be present when DS500 was given up to 4 weeks before and up to 3 weeks after the scrapie inoculum. The incubation period was extended by 5-19% at this dose, but if increased doses of DS500 were used, the incubation period could be prolonged by up to 62% [75]. Kimberlin and Walker (1986) gave various inocula of scrapie to mice either i.v. or i.p., and various drugs were tested before or after the scrapie infection [77]. DS500 proved effective in reducing the titre of the scrapie inoculum. Little effect was seen with heparin, dextran, or DEAE dextran. Diringler and Ehlers (1991) inoculated mice i.p. with scrapie and administered PPS i.p. on different days (84 to 50) before the PrP^{sc} infection. PPS increased the incubation period of mice by up to 75% [70]. Hamsters were also inoculated i.p. with various quantities of DS500 or PPS and with scrapie, separated by 2 to 24 hrs [78]. As the dose of DS500 increased, the incubation period also increased, but the maximum achieved with non-toxic doses of the drug was 21%. It was noted that a single i.p. administration of PPS increased the incubation period of i.c. inoculated scrapie by around 18% [78]. Farquhar et al. (1999) injected i.p. PPS immediately after scrapie infection of mice. Depending on mouse strain, a single PPS dose of 250 mg increased the scrapie incubation period by up to 66%. A single 1 mg i.p. dose of PPS protected mice completely from simultaneous scrapie infection. On the other hand, oral PPS was ineffective in delaying disease [79].

Doh-ura et al. (2004) recently infected transgenic mice (Tg7) expressing hamster prion protein with i.c. scrapie, and different agents were infused cerebroventricularly starting on day 10 or day 35 after infection [80]. The infusion was continued for 4 weeks. Infused drugs included lysosomotropic chemicals, such as E-64d cysteine protease inhibitor, chloroquine, quina-crine, amphotericin B, and PPS. Lysosomotropic agents demonstrated marginal effects in prolonging the incubation time when administered on day 35 after infection, and either no effect or less effect at the earlier stage (day 10 after infection). Amphotericin B and PPS demonstrated remarkable effects either early or late in the disease course. Amphotericin B resulted in around 30% prolongation of the incubation time when administered at the early stage, and 12% prolongation at the late stage. PPS showed more beneficial effects than amphotericin B, and mice which received PPS at the early stage survived 173% longer, and at the late stage 92% longer. Maximal effects of PPS at a later stage (day 42 of infection) were obtained at 230 $\mu\text{g}/\text{kg}/\text{day}$. Analysis of detailed relationship between the initiation time of the infusion of PPS and the outcome revealed that the effects of PPS were quite dependent on the timing of infusion initiation, with earlier initiation of treatment rendering a better prognosis [80]. Analysis by either immunohistochemistry or immunoblotting demonstrated that PPS potently inhibited PrP^{sc} deposition in the brain. It also showed that amount or dis-

tribution of deposited PrP^{sc} in the brain of mice treated with PPS was modified and did not return to the same level observed in the control animals, even when they were at a terminal stage. Immunohistochemical analysis demonstrated that mice treated with PPS from the early stage did not show any PrP^{sc} deposits in the brain on day 52. On the other hand, control animals demonstrated PrP^{sc} deposits in the parahippocampal white matter on day 35, and later also in the thalamus. No notable adverse effects were observed in experimental mice treated with up to 230 $\mu\text{g}/\text{kg}/\text{day}$ intraventricular PPS for two months. In a separate set of experiments in normal dogs, higher doses, such as 345 $\mu\text{g}/\text{kg}/\text{day}$ and 460 $\mu\text{g}/\text{kg}/\text{day}$, did show adverse effects such as partial or generalized epileptic seizures, which began within 24 hours after PPS infusion at the above high doses was initiated [80].

Both heparin and PPS are rapidly taken up into RES cells by a saturatable pathway. Low doses are cleared quickly into the RES, whereas higher doses saturate the RES and are excreted in urine [81]. PPS is metabolised by cellular non-specific desulphation in many organs and tissues, including vascular endothelium [82]. Renal excretion of desulphated PPS from plasma takes place over 6 days following a single dose, which also involves partial polyxylose chain breakdown. PPS can be administered orally, but only a low proportion (0.5-4%) of the drug is detected in the blood circulation [83, 84]. When PPS is given orally, anti-inflammatory effects are seen in the bladder after long-term administration [85]. It is considered that this is due to accumulation of the drug in cells of the RES with slow break-down and excretion. When used for anticoagulation and given s.c. or i.v., PPS may cause an early, benign, reversible thrombocytopenia and a rise in lipoprotein lipase activity [83]. Similarly to heparin, a rare, immune, severe form of thrombocytopenia has been also reported [86]. No significant neurological symptoms or signs have been reported in humans or animals treated orally or parenterally with PPS.

There has been no penetration in the CNS demonstrated with peripherally administered PPS, which is not surprising with the hydrophilic nature of the drug. On the other hand, direct intracerebral administration of PPS may afford high compartmental concentrations of the drug in the CNS, but no pharmacokinetics is available for this specific mode of administration. Direct administration of PPS to the CNS would be expected to allow PPS to concentrate inside cells, entering them via ubiquitous heparan-binding sites, and to exert biological effects on those cells infected by PrP^{sc}. In analogy to other therapeutic molecules, e.g. recombinant proteins delivered directly into the primate and human brain [87, 88], it is considered likely that cerebroventricular infusion of PPS may have the highest ratio of local versus systemic drug concentration.

Rationale for local administration of drugs to the CSF

The clinical and late preclinical phase of PrD with PrP^{sc} formation in the brain requires drugs that can cross into brain parenchyma and be present in the brain in a biologically active concentration [32, 42, 43]. However, in the early stages of PrD, with an intact blood-brain barrier (BBB), there is severe limitation of the penetration of drugs from blood into brain interstitium, and from there into glial and neuronal cells. Even at late stages of the disease, tight junctions of the brain capillaries may remain at least partially intact and therefore selectively limiting the entry of most molecules.

Compounds that are highly lipid soluble, such as alcohol, barbiturates, and some anticonvulsants, may easily pass through the endothelial cells forming the inner layer of the BBB. Lipid solubility is measured by the oil/water (octanol/water) partition coefficient, and molecules with a high coefficient usually permeate efficiently the BBB (for review see [89]). Such highly lipid soluble compounds with a high partition coefficient are phenytoin and methadone, and they cross the BBB in large quantities under normal conditions. Not all lipid soluble molecules, however, easily traverse the BBB. Compounds highly bound to plasma proteins have restricted access to the brain. For these substances, the degree of dissociation of the protein complex in transit through the capillary bed determines the degree of penetration across the BBB. Furthermore, there are special transport systems responsible for enhanced passage of certain compounds with low lipid solubility across the BBB, such as the physiologically important molecules D-glucose and phenylalanine [90]. The BBB can be subjected to pharmacological or osmotic modifications aimed at temporarily increasing its permeability to certain therapeutic molecules. These approaches are however invasive and have the potential for serious side effects [91, 92].

The CSF-brain barrier (CBB) seems to be more permeable because of its anatomical structure lacking tight junctions between the neuroependymal cells lining the cerebral ventricles. Substances administered to the CSF have been shown to penetrate into brain tissue by diffusion. The physical process of diffusion is gradient-driven, and penetration of the CBB will be enhanced by higher concentration of a molecule in one compartment [93, 94]. This fact points at an important advantage of the local application of drugs to the CSF - high local concentration in the CNS compartments, as opposed to negligible systemic concentration due to low reabsorption in the blood stream.

Continuous CSF circulation is physiologic process which lends itself to dissemination of substances throughout the CNS. CSF is continuously produced and completely replaced in the brain approximately every 8 hours.

In normal adults, the rate of CSF removal by reabsorption is equal to the rate of CSF production by filtration of blood through the intraventricular choroid plexus. CSF circulates from the sites of production, the lateral ventricles and third ventricle, into the cerebral aqueduct and into the fourth ventricle. From there CSF escapes the internal ventricular system of the brain by the foramina of Luschka and Magendie into the subarachnoid space around the brain and the spinal cord. Arachnoid granulations and dural sinuses are the route for CSF reabsorption to the blood circulation [95].

Animal models support findings in humans. In a model of cerebroventricular infusion in rats, radioactive sucrose was infused into one lateral ventricle. Within minutes after infusion, sucrose moved into the third ventricle, the aqueduct, fourth ventricle, and the subarachnoid space of the quadrigeminal, ambient and interpeduncular cisterns. About 15% of the injected sucrose entered these large cisterns. In contrast to most other CSF-brain interfaces, little sucrose moved from CSF into the medulla next to the lateral recesses and tissues adjacent to the large CSF cisterns. A thick, multilayered *glia limitans* visible on electron micrographs seemed to form a CSF-brain barrier at these interfaces [96].

Evidence exists also for the bulk flow of brain interstitial fluid via preferential pathways through the brain, which is closely related to CSF. This bulk flow of interstitial fluid has implications for drug delivery, drug distribution, and drug clearance [97].

Preliminary results with continuous long-term cerebroventricular administration of PPS in human PrD

The first objective of cerebroventricular PPS administration in PrD patients was to evaluate the short and long term safety and tolerability of escalating doses of PPS administered by continuous long term infusion. A secondary objective was to assess efficacy of PPS in delaying disease progression and improving existing neurological deficits. Patients with probable sporadic, iatrogenic, or variant CJD, or with hereditary syndromes such as GSS or FFI were eligible to receive PPS infusion. Informed consent was obtained where possible. If patients were not fit and able to consent, a legally appointed representative signed the consent forms. The primary endpoint of PPS administration studies was maximum tolerated dose of PPS as assessed by occurrence of serious toxicity resulting from PPS administration. Dose-limiting toxicity (DLT) was defined as any one of the following occurring in two or more patients:

- Any grade 4 toxicity attributed to PPS

- Grade 3 toxicity for neurological symptoms or for symptoms in other organ systems lasting longer than 5 days and attributed to PPS

Patients considered for PPS administration had to have a probable diagnosis of one of the above PrD in accordance to WHO criteria. Normal haematological, renal, and liver function was also a requirement. Because of the surgical procedure for implantation of the ventricular catheter and subcutaneous pump and infusion system, ongoing treatment with anticoagulants such as warfarin, heparin, clopidogrel, or aspirin was not allowed. Also the presence of any active infection or any viral syndrome within two weeks prior to treatment was an exclusion criterion.

Patients undergoing surgery had standard ventricular catheters placed in the anterior horn of the right lateral ventricle or in a few cases in both frontal horns, unless clinical reasons dictated another point of access to the ventricular system. In the first case with PPS administration, the catheter was connected initially to an external pump for trial administration of PPS, and later attached to a subcutaneously programmable pump (Synchromed EL, 18 ml reservoir, with side port, Medtronic Inc.) (Figure 4) permanently implanted in the abdominal wall. Later cases had simultaneous implantation of the catheter system and the infusion pump in the same surgical session. After a period of time after the surgical procedure (3-14 days) in which the pump was not active and scar tissue formation was expected to occur, PPS infusion commenced at a low dose level. The decision to proceed to the next higher dose level was based on the absence of clinical side effects and on normal findings on non-enhanced CT scans (e.g. exclusion of hydrocephalus or intracranial blood).

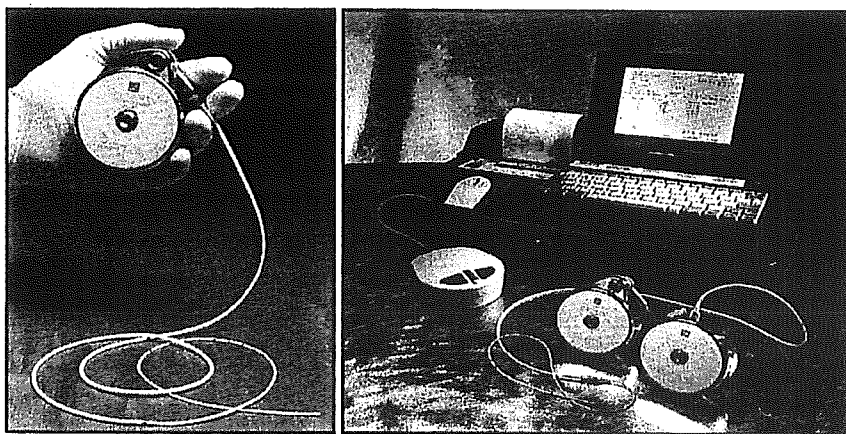


Figure 4. The implantable externally programmable pump (Synchromed EL with side port, Medtronic Inc., Minneapolis, MN) is shown with attached catheter (A). (B) shows a portable pump programming unit (telemetry unit) with printer.

There are no previously published data on a safe or potentially effective dose of cerebroventricularly infused PPS in human patients with PrD. Based on preclinical animal work, a dose escalation schedule was set up starting at 1 $\mu\text{g}/\text{kg}/\text{d}$ and escalating on a daily basis until a target dose of 11 $\mu\text{g}/\text{kg}/\text{d}$ was reached. This represented a 10-fold dose reduction, based on body surface area and weight differences, from the lowest effective PPS dose used in scrapie-infected mice in a preclinical study of intraventricular PPS [80]. The maximum daily dose of cerebroventricular PPS administered to the first 6 patients on a long term basis was 11 $\mu\text{g}/\text{kg}/\text{day}$. All further cases have received a maximum dose of 110 $\mu\text{g}/\text{kg}/\text{d}$ in 10-20 $\mu\text{g}/\text{kg}/\text{d}$ escalation steps, but long term follow up with this dose is still limited (Table 1).

The clinical source of PPS is *Pentosanpolysulfat SP54* in sterile 1 ml vials, supplied by the pharmaceutical company Bene Arzneimittel GmbH (Germany). Each vial contains 100 mg of Sodium-PPS (100 mg/ml) with 1% sodium-4-oxopentanoate as a stabiliser. For filling of the pump reservoir, PPS SP54 100 mg/ml is diluted with 0.9% NaCl to a final concentration of 1-10 mg/ml. The pump is then programmed to deliver the total daily dose in a continuous simple infusion mode (constant volume and infusion rate over time).

There are no standardised or widely accepted criteria for assessment of treatment efficacy in PrD. Surrogate criteria for efficacy were thus adopted and included overall survival, speed of disease progression before PPS infusion compared with disease progression after start of PPS, neuro-radiological imaging, and changes in the general and neurological condition of the patients.

The first patient to receive PPS infusion was a young man suffering from vCJD [98]. He presented initially with subjective signs of behavioural disturbance, followed a few months later by progressive ataxia, pyramidal signs and myoclonus, which led to the clinical diagnosis of possible vCJD. The clinical picture combined with abnormal MR findings in the FLAIR sequence (pulvinar sign) and positive tonsil biopsy allowed the diagnosis of probable vCJD 8 months after the occurrence of initial clinical symptoms. At the time of first administration of PPS, the patient had symptoms of advanced vCJD, such as ataxia, dementia, dysphagia, dysphasia, myoclonus, and was confined to bed and unable to care for himself. He was fed via percutaneous gastrostomy. The initial PPS dose of 1 $\mu\text{g}/\text{kg}/\text{d}$ was escalated without drug-related complications to the target dose of 11 $\mu\text{g}/\text{kg}/\text{d}$. Continuous infusion of PPS for 23 months has not caused any drug-related side effects. Cerebroventricular PPS at the above dose did not have any measurable systemic anticoagulant activity in serum, as confirmed by unchanged INR (international normalised ratio) before and during PPS infu-

sion. Follow-up CT scans demonstrated no intracerebral haemorrhage, and there were no seizures. Subdural fluid collections first over the right hemisphere and subsequently over the left hemisphere necessitated surgical (burr hole) evacuation of fluid. Repeated surgical revisions of the fluid collections were necessary (Figure 5).

This first patient is currently alive and in a stable condition. Although there were no major improvements in the neurological and general condition, there were a few notable changes. The patient is now able to fix his eyes on persons, to obey simple one stage commands, and to make verbalization attempts in response to stimuli. The sleep/wake cycle and the reflex swallow are restored and the myoclonus is reduced. The patient has gained 5 kg of weight compared to pre-PPS baseline, while on the same nutritional regime. Regular follow-up CT scans have shown progressive brain atrophy during PPS administration, which could not be correlated to any worsening of the clinical condition (Figure 5).

Since January 2003, a total of 13 patients with PrD have undergone surgery and continuous cerebroventricular administration of PPS. Anonymised clinical and follow-up data are presented in Table 1. The most important clinical finding is the safety of PPS administration to the cerebral ventricles. The maximum tolerated dose of PPS has not been reached. There were no cases with side effects attributable to PPS, even in patients receiving 110 $\mu\text{g}/\text{kg}/\text{d}$ of PPS.

Focal seizures have been observed in one patient on 11 $\mu\text{g}/\text{kg}/\text{d}$, and generalised tonic-clonic seizures in one patient with 110 $\mu\text{g}/\text{kg}/\text{d}$. It remains to be clarified if these seizures were a side effect of PPS or of surgery, since in both cases they occurred months after start of PPS and during infusion with a stable dose of PPS.

It is currently unclear if a higher dose of PPS has a stronger effect, and if dose escalation should be continued above 110 $\mu\text{g}/\text{kg}/\text{d}$. In most cases it seems that PPS administration results in a temporary halt of disease progression, but this conclusion is not based on hard evidence or objective measurements. PPS administration seems not able to reverse the clinical course of advanced disease and to achieve functional recovery of established neurological deficits.

Furthermore, surgery in the brain affected by PrD may result in a higher rate of surgical complications than usually encountered in comparable non-PrD cases. Brain atrophy may progress while PPS is administered, and there is no apparent correlation between degree of atrophy and clinical status of the patients. Therefore, in accordance with results from the pre-clinical animal studies [80], cerebroventricular infusion of PPS should be commenced as early as possible after disease diagnosis and, if possible, before the occurrence of fixed neurological deficits.

In conclusion, despite the encouraging preliminary results in PrD patients receiving long term cerebroventricular PPS, further clinical, neuro-radiological and laboratory investigations in the context of a prospective clinical study will be essential for the evaluation of genuine clinical benefits of PPS administration.

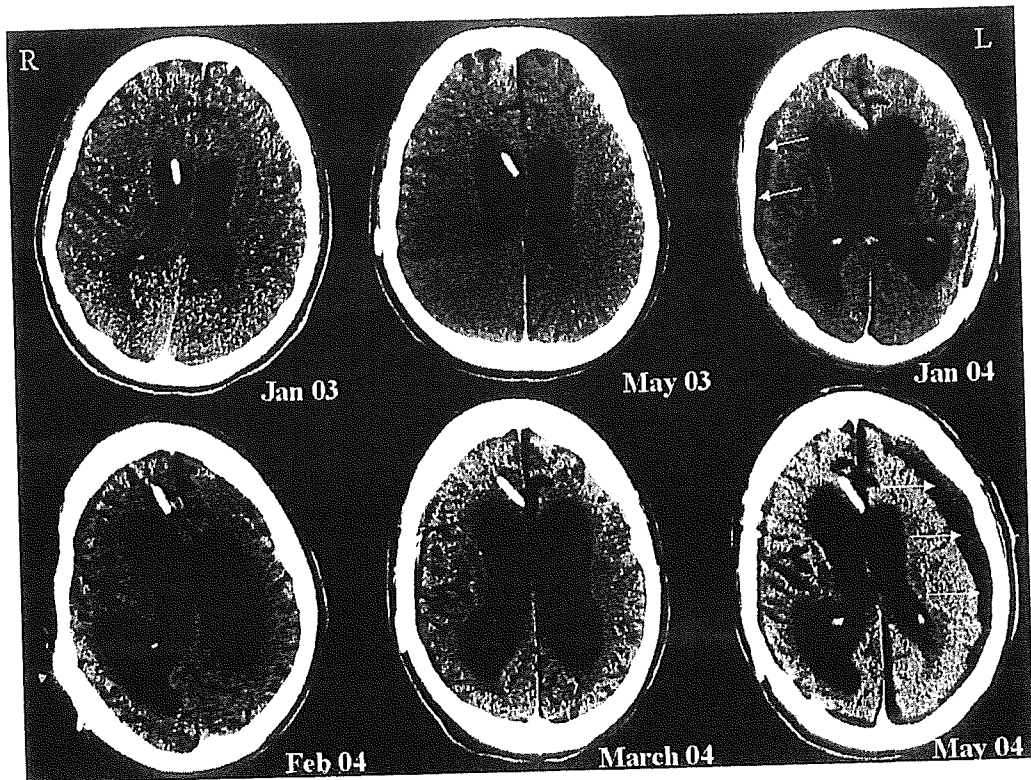


Figure 5. Serial CT scans of patient #1 demonstrating sequential occurrence of right parietal subdural fluid collection (upper right, arrows) and left parietal subdural collection (lower right, arrows). Note the progression of brain atrophy over time.