

veins from segment V or VIII in the liver graft were anastomosed to the inferior vena cava using autologous venous grafts when the diameter of those drainage veins was more than 7 mm. Reconstruction of the hepatic arteries was performed with end-to-end anastomosis using a surgical microscope. The bile duct was reconstructed with duct-to-duct anastomosis in 30 patients; hepaticojejunostomy was used in the 2 patients with primary sclerosing cholangitis.

### Immunosuppression

The immunosuppression protocol consisted of tacrolimus and low-dose steroids. The target trough level for tacrolimus in whole blood was 10–15 ng/mL during the 1st 2 weeks, approximately 10 ng/mL during next 2 weeks, and 5–10 ng/mL thereafter. Methylprednisolone, 10 mg/kg of body weight, was administered intravenously immediately before perfusion of the graft portal vein. Methylprednisolone, 1 mg/kg intravenously, was given on postoperative days (PODs) 1–3, followed by .5 mg/kg per day on PODs 4–6. The steroid was then switched to oral prednisolone .5 mg/kg per day on POD 7, and the dose reduced to .1 mg/kg per day at 1 month. If a patient's liver function was stable, they were weaned off steroids at around 3–6 months postoperatively.

### Monitoring of PVP

A 16-gauge antithrombotic catheter (Medicut UK-LCV Kit; Nippon Sherwood Medical Industries, Tokyo, Japan) was inserted via the inferior mesenteric vein before the recipient's liver was removed. The tip of the catheter was positioned in the recipient's portal vein or splenic vein and fixed in place by ligation and 2 rubber bands. The other end was drawn outside the body via the surgical wound as described elsewhere.<sup>7</sup> A transducer was used to continuously monitor PVP during the operation and while patients were in the intensive care unit. We divided the 32 recipients into 2 groups based on their mean PVP during the 1st 3 days after LDLT: a higher PVP group, with PVP  $\geq$  20 mm of Hg (H Group;  $n = 17$ ), and a lower PVP group, with PVP  $<$  20 mm of Hg (L Group;  $n = 15$ ). We removed the catheter on the ward 7 days after LDLT. If systemic infection related to catheterization was suspected, we withdrew it immediately.

### Computed Tomography Volumetry of Liver Graft

Helical computed tomography studies were conducted with a High Speed Advantage QX-I (GE Medical Systems, Tokyo, Japan). The scanning parameters were 120 kV, 200 mA, collimation 5 mm, and a table speed of 15 mm/rotation, with reconstruction increments of 5 mm. Contrast-enhanced images were not acquired after LDLT in all patients. Graft volume (GV) was calculated with volumetric computed tomography for recipients approximately 1, 2, 3, and 4 weeks, and 3 and 6 months after LDLT. The standard liver volume (SLV) was calculated according to the formula as described by Urata et al.<sup>17</sup>

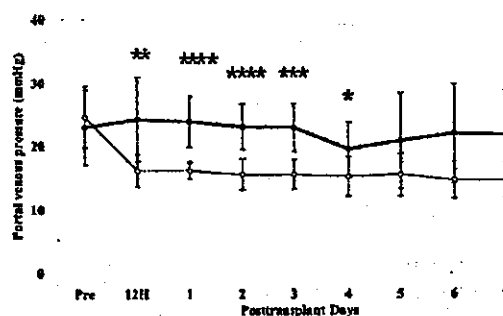


Figure 1. Serial changes of portal venous pressure of both groups. Open circles and closed circles represent GV/SLV of L Group and H Group, respectively. \* $P < .05$  vs. L Group; \*\* $P < .0005$  vs. L Group; \*\*\* $P < .000005$  vs. L Group; \*\*\*\* $P < .0000005$  vs. L Group. Abbreviations: H, hours; Pre, pretransplantation; GV, graft volume; SLV, standard liver volume.

### Measurement of Serum Transaminases, Bilirubin, International Normalized Ratio, Hepatocyte Growth Factor, and Vascular Endothelial Growth Factor

Serum aspartate aminotransferase, alanine transaminase, bilirubin, and international normalized ratio were measured daily, and blood samples were obtained from a peripheral vein at 6 and 12 hours, and 1, 3, 5, 7, and 14 days after portal reperfusion. Portal venous blood was collected from the portal vein catheter 6 and 12 hours, and 1, 3, 5, and 7 days after portal reperfusion. Samples were collected into a serum separator tube and centrifuged for 10 minutes at 3,000g, and serum was stored at  $-80^{\circ}\text{C}$  until assayed. Hepatocyte growth factor (HGF) and vascular endothelial growth factor (VEGF) concentrations were measured with HGF and VEGF enzyme-linked immunosorbent assay (ELISA kit; R&D Systems, Minneapolis, MN) according to the manufacturer's instructions.

### Statistical Analyses

All statistical calculations were carried out using StatView-J 5.0 statistical software (SAS Institute, Cary, NC). Values are presented as mean  $\pm$  standard deviation unless stated otherwise. Discontinuous data were analyzed by Mann-Whitney tests, continuous data by Student's  $t$ -test, categorical data by chi-squared tests, and Kaplan-Meier survival curves by Cox-Mantel tests.  $P$  values  $< .05$  were considered statistically significant.

### Results

Changes in mean PVP in both groups during the week after LDLT are shown in Figure 1. PVP was significantly higher during the 1st 4 days after the operation in the H Group. Mean PVP during the 3 days after LDLT

Table 1. Recipient Characteristics by Group Before and During Operation

Characteristics	H Group (N = 17)	L Group (N = 15)	P value
Median age years (range)	53 (20-64)	53 (68-42)	.2770
Gender (male/female)	10 / 7	11 / 4	.4566
Mean MELD score $\pm$ SD	17.9 $\pm$ 12.9	10.7 $\pm$ 6.7	.6610
Mean graft weight (gm) $\pm$ SD	687 $\pm$ 174	651 $\pm$ 105	.4766
Mean GV / SLV at transplantation $\pm$ SD	.638 $\pm$ .159	.633 $\pm$ .199	.9414
Mean cold ischemia time (minutes) $\pm$ SD	115 $\pm$ 68	113 $\pm$ 102	.5325
Mean warm ischemia time (minutes) $\pm$ SD	49 $\pm$ 21	46 $\pm$ 11	.7184
Mean blood loss (gm) $\pm$ SD	16,130 $\pm$ 19,050	18,819 $\pm$ 22,455	.9414
Median donor age years (range)	30 (18-58)	43 (19-62)	.1120

Abbreviations: MELD, model for end-stage liver disease; GV, graft volume; SLV, standard liver volume.

was 15.4 mm of Hg (range: 13.0-17.6 mm of Hg) in the L Group and 23.7 mm of Hg (range: 20.0-31.0 mm of Hg) in the H Group. Sixteen of 17 recipients in the H Group and all 15 in the L Group had clinical evidence of portal hypertension, such as esophageal varices, splenomegaly, or hypersplenism prior to transplant. One patient with acute liver failure did not have any clinical evidence of portal hypertension.

PVP elevation to 20 mm of Hg or more was associated with poor survival (1-year survival: L: 92.9%, H: 58.8%;  $P = .0261$ ). Seven patients in the H Group died; with deep fungal infection on PODs 56 and 76 ( $n = 2$ ), sepsis on POD 9 ( $n = 1$ ), graft failure on POD 54 ( $n = 1$ ), cerebral hemorrhage on POD 41 ( $n = 1$ ), iatrogenic cardiac tamponade on POD 14 ( $n = 1$ ), and multiple organ failure secondary to hemorrhagic shock caused by rupture of a splenic aneurysm on POD 62 ( $n = 1$ ). One patient in the L Group died with pneumonia on POD 54 ( $n = 1$ ).

There were 2 cases in the H Group and 1 case in the L Group of intraabdominal hemorrhage; 2 on POD 1, and 1 on POD 2. There was 1 case in the H Group and 2 in the L Group of stenosis of hepatic venous anastomoses of the grafts on PODs 9, 13, and 18, which were successfully treated with stent insertions to the hepatic veins, avoiding any progression of graft dysfunction. There were 2 cases of bile duct complications in the L Group. In the L Group, 1 patient developed biliary anastomotic stenosis on POD 89, which was managed successfully with percutaneous transhepatic balloon dilatation. Another patient in the L Group with biliary leakage on POD 17 made a successful recovery with the aid of percutaneous drainage.

Table 1 shows the preoperative and intraoperative characteristics of the recipients in both groups. Recipi-

ent age, gender, and the Model for End-Stage Liver Disease score at the time of LDLT were similar between groups. There were no significant differences between the groups in graft weight (GV / SLV), donor age, mean blood loss, cold ischemic time, or warm ischemic time. Etiology of the liver diseases in the L Group consisted of hepatitis C related cirrhosis in 8 cases, hepatitis B related cirrhosis in 3, alcoholic liver cirrhosis in 3, and primary biliary cirrhosis in 1 case. On the other hand, those in the H Group consisted of hepatitis C related cirrhosis in 9 cases, hepatitis B related cirrhosis in 1, primary biliary cirrhosis in 3, primary sclerosing cholangitis in 2, and acute liver failure in 2 cases. There was no significant difference between the groups regarding the etiology of the liver disease.

#### Liver Regeneration

The changes in GV / SLV ratio during the 6 months after LDLT are shown in Figure 2. One week after LDLT, GV / SLV in both groups almost reached 1.0. GV / SLV in the L Group peaked at 1 week, whereas in the H Group it peaked above 1.2 at 2 weeks after LDLT but decreased to below .95 at 6 months after LDLT. At 3 and 4 weeks and 3 months after LDLT, GV / SLV was significantly higher in the H Group (H / L at 2, 3, and 4 weeks and 3 months:  $1.24 \pm .20 / 1.02 \pm .18$ ,  $1.16 \pm .16 / .916 \pm .111$ ,  $1.27 \pm .22 / .975 \pm .136$  and  $1.29 \pm .24 / .943 \pm .091$ , respectively;  $P = .0208$ ,  $P = .00067$ ,  $P = .00042$ ,  $P = .0043$ , respectively). The difference between the groups at 6 months after LDLT was not significant (H / L:  $.940 \pm .151 / .963 \pm .132$ ;  $P = .850$ ).

Table 2 shows the serial changes in peripheral and portal venous blood HGF levels after LDLT in both

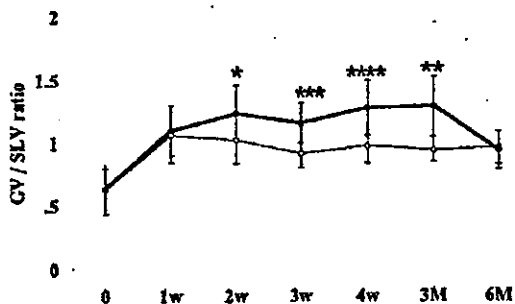


Figure 2. The courses of GV / SLV during the 6 months after transplantation. Open circles and closed circles represent GV / SLV of L Group and H Group, respectively. \**P* < .05; \*\**P* < .005 vs. H Group; \*\*\**P* < .001 vs. H Group; \*\*\*\**P* < .0005 vs. H Group. Abbreviations: 0, at LDLT; w, weeks; M, months.

groups. The preoperative peripheral venous blood HGF level in the H Group was significantly higher than in the L Group (H: 5,730 ± 3,997 pg/mL, L: 2,096 ± 1,398 pg/mL; *P* = .00816). Preoperative high levels of HGF in the H Group were reflected by a remarkably high level of HGF in 2 cases with acute liver failure. The HGF level in the H Group decreased rapidly within 6 hours after reperfusion, but it gradually increased from day 1 to day 14 after LDLT to a higher level than in the L Group; the mean peripheral venous blood HGF level on POD 7 was significantly higher than in the L Group (H: 3,151 ± 2,339 pg/mL, L: 1,356 ± 547 pg/mL; *P* = .0398). The preoperative portal venous blood HGF level in the H Group was also significantly higher than in the L Group (H: 3,622 ± 1,720 pg/mL, L: 2,170 ± 1,157 pg/mL; *P* = .0385). The peak peripheral blood HGF level during the 1st 2 weeks after LDLT was significantly higher in the H Group (H: 3,696 ± 2,002 pg/mL, L: 1,730 ± 745 pg/mL; *P* = .00964). The portal venous blood HGF levels in both groups decreased immediately 12 hours after reperfusion, and there were no significant differences between the groups during the week after LDLT.

Table 3 shows the serial changes in VEGF levels in the peripheral and portal venous blood of both groups. In the L Group, the peripheral venous blood VEGF level increased gradually during the 7 days after LDLT, but remained unchanged in the H Group. On POD 7, the peripheral VEGF level in the L Group was significantly higher than in the H Group (L: 205 ± 142 pg/mL, H: 71 ± 65 pg/mL; *P* = .0177). The portal venous blood VEGF level in the L Group gradually increased, whereas it gradually decreased in the H Group. The mean portal venous VEGF of the L Group

Table 2. Serial Changes in Peripheral and Portal Venous Blood HGF Levels (pg/mL) After LDLT of Both Groups

	Pre-LDLT	6 Hours	12 Hours	1 Day	3 Days	5 Days	7 Days	14 Days
Peripheral								
H Group	5,730 ± 3,997*	2,748 ± 3,853	989 ± 379§	1,614 ± 1,039§	1,237 ± 625§	1,895 ± 1,663‡	3,151 ± 2,339*	2,671 ± 1,543†
L Group	2,096 ± 1,398	1,932 ± 1,431	1,191 ± 466	1,325 ± 889	1,190 ± 547	1,118 ± 350	1,356 ± 547	1,299 ± 546
Portal								
H Group	3,622 ± 1,720*	1,714 ± 1,496†	1,027 ± 460	696 ± 338#	805 ± 526§	1,832 ± 2,520‡	1,946 ± 2,449*	
L Group	2,170 ± 1,157	926 ± 371**	1,236 ± 1,096	906 ± 528**	852 ± 526**	782 ± 280**	1,244 ± 922	

\**P* < .05 versus L Group.  
†*P* < .05 versus pretransplantation in the H Group.  
‡*P* < .01 versus pretransplantation in the H Group.  
§*P* < .005 versus pretransplantation in the H Group.  
||*P* < .0005 versus pretransplantation in the H Group.  
#*P* < .0001 versus pretransplantation in the H Group.  
\**P* < .00005 versus pretransplantation in the H Group.  
\*\**P* < .05 versus pretransplantation in the L Group.

Table 3. Serial Changes in Peripheral and Portal Venous Blood VEGF Levels (pg/ml) After LDLT of Both Groups

	Pre-LDLT	6 Hours	12 Hours	1 Day	3 Days	5 Days	7 Days	14 Days
Peripheral								
H Group	96 ± 173	46 ± 50	48 ± 51	57 ± 45	35 ± 34	50 ± 47	71 ± 65	151 ± 199
L Group	53 ± 81	32 ± 38	46 ± 47	76 ± 83	83 ± 85	115 ± 107	205 ± 142*†	230 ± 220
Portal								
H Group	125 ± 141	73 ± 59	68 ± 49	71 ± 49	64 ± 62	64 ± 21	33 ± 23†	
L Group	115 ± 163	64 ± 31	79 ± 80	172 ± 289	249 ± 251	351 ± 318*	228 ± 284	

\**P* < 0.05 versus H group.  
†*P* < 0.05 versus pretransplantation in the H group.  
‡*P* < 0.05 versus pretransplantation in the L group.

on POD 5 was significantly higher than that of the Group H (L: 351 ± 318 pg/mL, H: 64 ± 21 pg/mL; *P* = .0382). The peak portal VEGF level during the 1st week was significantly higher in the L Group (L: 433 ± 297 pg/mL, H: 92 ± 48 pg/mL; *P* = .0137).

#### Graft Damage

Table 4 shows peak aspartate aminotransferase, alanine transaminase, and bilirubin levels in recipients during the 1st 2 weeks after LDLT, international normalized ratio values on PODs 3 and 7, and the mean daily ascitic fluid volume during the 1st 3 days after LDLT. The peak serum aspartate aminotransferase, alanine transaminase, and bilirubin levels were significantly higher in the H Group. The timing of the peak bilirubin level was 6.1 ± 3.1 days after transplantation in the H Group and 9.2 ± 8.8 in the L Group. On POD 3, the international normalized ratio was significantly higher in the H Group, but there was no difference at 1 week. Mean ascitic fluid volume during the 3 days after LDLT was 1,131 ± 908 mL/day in the L Group, and it was significantly greater, 1,919 ± 1,069 mL/day, in the

H Group. Ongoing ascites needed drainage in 3 cases in the H Group and 1 case in the L Group.

#### Discussion

Regeneration of a segmental liver graft in LDLT or split-liver transplantation is essential for a successful outcome in adult patients. It has been hypothesized that an increase in PVP or portal venous flow is necessary for liver regeneration to occur after hepatectomy and portal vein embolization,<sup>2-4</sup> so we have deliberately increased the portal venous flow and PVP after LDLT to induce graft regeneration and improve graft function. On the other hand, several recent reports have hypothesized that excessive portal hypertension and overperfusion can injure the graft and lead to graft dysfunction.<sup>5-14</sup> In 2002, Boillot et al.<sup>5</sup> reported a case in which a recipient transplanted with a small-for-size graft was successfully treated by performing a mesocaval shunt that reduced portal venous inflow to the graft. Portal overperfusion of small-for-size grafts in which portal inflow per unit volume is elevated is thought to be one of the main causes of posttransplant graft dysfunction.<sup>10</sup> Ito et al.<sup>7</sup>

Table 4. Postoperative Profiles of the Recipients

	H Group	L Group	<i>P</i> Value
Peak AST (U/L)	451 ± 345	221 ± 131	.0183
Peak ALT (U/L)	410 ± 348	201 ± 120	.0430
Peak Bilirubin (mg/dL)	15.0 ± 10.4	6.8 ± 3.5	.0071
INR (3rd postoperative day)	1.49 ± .24	1.28 ± .20	.0142
INR (7th postoperative day)	1.17 ± .15	1.09 ± .12	.1484
Ascitic fluid volume (mL/day)	1,919 ± 1,069	1,131 ± 908	.0486

Abbreviations: AST, aspartate aminotransferase; ALT, alanine transaminase; INR, international normalized ratio.

reported that elevation of PVP to more than 20 mm of Hg in the early postoperative phase is strongly associated with poor graft and recipient survival, prolonged cholestasis, bacteremia, poor synthetic function, and early development of ascites,<sup>7</sup> and their findings are compatible with our own. Although several reports have hypothesized graft hyperperfusion in small-for-size grafts is the main factor leading to graft dysfunction and poor survival,<sup>5-14</sup> little information has been provided on the impact of PVP on graft regeneration in terms of changes in graft volume and expression of the regeneration factors.

In our study, elevation of PVP to 20 mm of Hg or more in the early postoperative phase after LDLT was strongly associated with a rapid increase in the size of the graft, a higher peripheral blood HGF level, and a lower portal VEGF level. Although shear stress has been hypothesized to be involved in the regenerative process after hepatectomy,<sup>2</sup> little evidence has been provided in support of this hypothesis. Wang et al.<sup>18</sup> detected the appearance of proliferation factors by *in vitro* bioassay after hepatectomy in rats, which was fully blocked by the nitrous oxide synthase inhibitor N(G)-nitro-L-arginine methyl ester and restored by L-arginine; they hypothesized that release of nitrous oxide induced by the vascular shear stress following hepatectomy is the primary trigger of the regeneration process. Kawai et al.<sup>4</sup> showed that changes in portal hemodynamics that expose the hepatic vasculature to stretch stress after portal venous embolization may contribute to interleukin-6 release and lead to regeneration of the nonembolized lobe.

HGF is a heterodimeric protein that was identified as a liver sinusoidal endothelial cell-derived paracrine mediator<sup>19</sup> in liver regeneration, and is the most potent known complete mitogen for hepatocytes in culture. HGF is also produced by fibroblasts, hemocytes, and endothelial cells *in vitro*.<sup>20</sup> Tsubouchi et al.<sup>21</sup> reported increased serum HGF levels in patients with acute hepatitis or acute liver failure, which decreased rapidly in the recovery phase compared to the levels on admission. Thus HGF levels of acute hepatitis patients reflect liver regeneration, whereas HGF levels of irreversible acute liver failure patients reflect failure of liver regeneration.<sup>22</sup> The increase in HGF concentration in liver disease may be attributable to both an increase in production of HGF and decrease in clearance by the damaged liver.<sup>23</sup> Milki et al.<sup>24</sup> reported persistently high HGF levels in orthotopic liver transplantation recipients with compromised grafts, whereas the HGF levels of patients with well-functioning grafts after liver transplantation decreased rapidly and remained low 4 hours after reper-

fusion. Surviving patients with reversible primary graft dysfunction had low HGF levels 48 hours after reperfusion that preceded the decrease in aspartate aminotransferase concentration. Peripheral HGF levels not only yielded graft regeneration details but also information for evaluation of early graft function. Ninomiya et al.<sup>25</sup> showed that small-for-size grafts regenerated faster and were associated with significantly higher peripheral HGF levels 1 day after LDLT than non-small-for-size grafts. In our study, HGF levels in the H Group were higher than in the L Group. We hypothesized that sinusoidal microcirculatory disturbances caused PVP elevation and damage to the hepatocytes, and hepatocytes cannot consume HGF produced by sinusoidal endothelial cells; thus, HGF levels in the H Group were higher than in the L Group. There were 2 cases of acute liver failure in the H Group that showed remarkably higher HGF levels; this group showed higher levels of HGF preoperatively than the L Group. Ninomiya et al.,<sup>25</sup> in consideration of Appasamy et al.<sup>26</sup> showing that HGF is cleared by liver, adrenal, spleen, and kidney, and that its half life is estimated to be less than 10 minutes, reported that preoperative serum HGF levels have little influence on postoperative levels.

VEGF is a glycoprotein that selectively induces endothelial proliferation, angiogenesis, and capillary hyperpermeability, and is essential for healing of injured tissue and proliferation of carcinoma cells.<sup>27,28</sup> The results of Northern blot analysis showed that VEGF messenger ribonucleic acid is highly expressed in human fetal lung, kidney, and spleen, and moderately expressed in fetal heart, adrenal, pancreas, intestine, liver, testis, skin, muscle, and brain.<sup>29,30</sup> VEGF also plays an important role in liver regeneration. The proliferation and survival of liver sinusoidal endothelial cells has been shown *in vitro* to be regulated by VEGF secreted by hepatocytes.<sup>31</sup> Taniguchi et al.<sup>32</sup> reported mainly detecting VEGF expression in periportal hepatocytes of regenerated liver tissue after hepatectomy in rats. Granot et al.<sup>33</sup> showed that VEGF is secreted by HepG<sub>2</sub> cells *in vitro* and is dependent on the HGF level, and they hypothesized that liver sinusoidal endothelial cell recovery might depend on prior hepatocyte regeneration. However, in our study, VEGF levels in the H Group with more compromised grafts were lower than in the L Group; although HGF levels were higher in the H Group. Akiyoshi et al.<sup>34</sup> showed that patients with acute liver failure had significantly lower serum VEGF levels and significantly higher levels of HGF than healthy individuals, and that the serum VEGF levels of survivors of acute liver failure are significantly higher, concomitant with the decreased level of HGF in the

recovery phase compared to that seen on admission. We hypothesized that hepatocytes in the H Group, which were apt to be damaged by sinusoidal microcirculatory disturbances, could not produce enough VEGF in spite of the increased HGF.

On the other hand, since our own results showed that the portal venous VEGF level was higher than the peripheral venous VEGF level, we hypothesized that portal venous VEGF secreted by the stomach, spleen, or intestine, as well as hepatocyte-derived VEGF, also plays an important role in graft regeneration. VEGF messenger ribonucleic acid expression was also found in the spleen and gastric mucosa, and in enterocytes.<sup>29,30,35,36</sup> Tsugawa et al.<sup>36</sup> reported that portal hypertension decreases oxygenation of stomach tissue, and the percentage of VEGF expression in the stomach tissue of the rats was found to be higher than in the control gastric mucosa. They hypothesized that hypoxia of stomach tissue triggered by portal hypertension induced hypoxia-inducible factor 1, and hypoxia-inducible factor 1 induced expression of VEGF in stomach tissue. Scharfe et al.<sup>35</sup> demonstrated that proinflammatory cytokines activate the hypoxia-inducible factor 1 pathway and increase expression of VEGF in rat enterocytes *in vitro*. In contrast, Assy et al.<sup>37</sup> reported a significantly lower serum VEGF level in patients with cirrhosis with portal hypertension than that in patients with cirrhosis without portal hypertension, findings that are compatible with our own. We therefore hypothesized that excessive portal hypertension stressed both hepatocytes and enterocytes and led to poor VEGF release in both peripheral and portal venous blood. In our study, portal and peripheral VEGF levels in the L Group peaked on PODs 5 and 7, respectively. Portal VEGF was mainly secreted by intestine, stomach, or spleen, while peripheral VEGF was reflected by secretions from intestine, stomach, spleen, and liver, and by consumption in the liver; so portal and peripheral VEGF levels in the L Group peaked at different postoperative days. We also hypothesized that the late peak of peripheral VEGF may be reflected by increased secretion from hepatocytes in the regenerating liver.

Because liver regeneration depends on coordinated proliferation of hepatocytes and liver sinusoidal endothelial cells, HGF and VEGF are both important. We do not think that graft hypertrophy in response to graft damage induced by portal hypertension can be considered true "graft regeneration." In an experimental study of a small-for-size graft model in animals, reduction of portal venous inflow by a portocaval shunt improved outcome and graft function.<sup>11,13</sup> For clinical cases, several reports have claimed that modulation of portal

inflow, for example by a portocaval shunt<sup>5,14</sup> and splenic artery ligation,<sup>10</sup> has been effective in reducing PVP after transplantation of a small-for-size graft. Further evaluation of adequate PVP or portal venous flow for true graft regeneration after LDLT is necessary.

In conclusion, elevation of PVP to 20 mm of Hg or more in the early postoperative phase after LDLT was associated with rapid graft hypertrophy, a higher peripheral venous blood HGF level, and a lower portal venous VEGF level; however, it was also associated with poor recipient outcome, graft dysfunction with hyperbilirubinemia, coagulopathy, and severe ascites. Increased PVP reflects changes in the hepatic microcirculation, and elevated PVP may be a result of the injury to the liver rather than the cause. Further evaluation is necessary to determine the level of portal pressure that is adequate for true graft regeneration and a reduction of the graft injury; also, a safer method for true graft regeneration after LDLT needs to be established.

## References

1. Kiuchi T, Kasahara M, Uryuhara K, Inomata Y, Uemoto S, Asonuma K, et al. Impact of graft size mismatching on graft prognosis in liver transplantation from living donors. *Transplantation* 1999;67:321-327.
2. Sato Y, Koyama S, Tsukada K, Hatakeyama K. Acute portal hypertension reflecting shear stress as a trigger of liver regeneration following partial hepatectomy. *Surg Today* 1997;27:518-526.
3. Niya T, Murakami M, Aoki T, Murai N, Shimizu Y, Kusano M. Immediate increase of portal pressure, reflecting sinusoidal shear stress, induced liver regeneration after partial hepatectomy. *J Hepatobiliary Pancreat Surg* 1999;6:275-280.
4. Kawai M, Naruse K, Komatsu S, Kobayashi S, Nagino M, Nimura Y, Sokabe M. Mechanical stress-dependent secretion of interleukin 6 by endothelial cells after portal vein embolization: clinical and experimental studies. *J Hepatol* 2002;37:240-246.
5. Boillot O, Delafosse B, Mechet I, Boucaud C, Pouyer M. Small-for-size partial liver graft in an adult recipient; a new transplant technique. *Lancet* 2002;359:406-407.
6. Shimamura T, Taniguchi M, Jin MB, Suzuki T, Matsushita M, Furukawa H, Todo S. Excessive portal venous inflow as a cause of allograft dysfunction in small-for-size living donor liver transplantation. *Transplant Proc* 2001;33:1331.
7. Ito T, Kiuchi T, Yamamoto H, Oike F, Ogura Y, Fujimoto Y, et al. Changes in portal venous pressure in the early phase after living donor liver transplantation: pathogenesis and clinical implications. *Transplantation* 2003;75:1313-1317.
8. Lo CM, Liu CL, Fan ST. Portal hyperperfusion injury as the cause of primary nonfunction in a small-for-size liver graft: successful treatment with splenic artery ligation. *Liver Transpl* 2003;9:626-628.
9. Troisi R, de Hempinne B. Clinical relevance of adapting portal vein flow in living donor liver transplantation in adult patients. *Liver Transpl* 2003;9:S36-S41.
10. Troisi R, Cammu G, Militerno G, De Baerdemacker L, Decruyenaere J, Hoste E, et al. Modulation of portal graft inflow: a

- necessity in adult living-donor liver transplantation? *Ann Surg* 2003;237:429-436.
11. Boillot O, Mechet I, Le Derf Y, Bernard P, Figueiredo P, Berger F, et al. Portomesenteric disconnection for small-for-size grafts in liver transplantation: preclinical studies in pigs. *Liver Transpl* 2003;9:S42-S46.
  12. Koyama S, Sato Y, Hatakeyama K. The subcutaneous splenic transposition prevents liver injury induced by excessive portal pressure after massive hepatectomy. *Hepatogastroenterology* 2003;50:37-42.
  13. Smyrnioris VE, Kostopanagiotou G, Theodoraki K, Gamaletsos E, Kondi-Pafiti A, Mystakidou K, Arkadopoulos N. Effect of mesocaval shunt on survival of small-for-size liver grafts: experimental study in pigs. *Transplantation* 2003;75:1737-1740.
  14. Takada Y, Ueda M, Ishikawa Y, Fujimoto Y, Miyauchi H, Ogura Y, et al. End-to-side portocaval shunting for a small-for-size graft in living donor liver transplantation. *Liver Transpl* 2004;10:807-810.
  15. Tanaka K, Uemoto S, Tokunaga Y, Fujita S, Sano K, Nishizawa T, et al. Surgical techniques and innovations in living related liver transplantation. *Ann Surg* 1993;217:82-91.
  16. Inomata Y, Uemoto S, Asotsuma K, Egawa H. Right lobe graft in living donor liver transplantation. *Transplantation* 2000;69:258-264.
  17. Urata K, Kawasaki S, Matsunami H, Hashikura Y, Ikegami T, Ishizone S, et al. Calculation of child and adult standard liver volume for liver transplantation. *Hepatology* 1995;21:1317-1321.
  18. Wang HH, Lauth WW. Evidence of nitric oxide, a flow-dependent factor, being a trigger of liver regeneration in rats. *Can J Physiol Pharmacol* 1998;76:1072-1079.
  19. LeCouter J, Moritz DR, Li B, Phillips GL, Liang XH, Gerber HP, Hillan KJ, et al. Angiogenesis-independent endothelial protection of liver: role of VEGFR-1. *Science* 2003;299:890-893.
  20. Matsumoto K, Tajima H, Okazaki H, Nakamura T. Negative regulation of hepatocyte growth factor gene expression in human lung fibroblasts and leukemic cells by transforming growth factor-beta 1 and glucocorticoids. *J Biol Chem* 1992;267:24917-24920.
  21. Tsubouchi H, Niitani Y, Hirono S, Nakayama H, Gohda E, Arakaki N, et al. Levels of the human hepatocyte growth factor in serum of patients with various liver diseases determined by an enzyme-linked immunosorbent assay. *Hepatology* 1991;13:1-5.
  22. Arakaki N, Kawakami S, Nakamura O, Ohnishi T, Miyazaki H, Ishii T, et al. Evidence for the presence of an inactive precursor of human hepatocyte growth factor in plasma and sera of patients with liver diseases. *Hepatology* 1995;22:1728-1734.
  23. Tsubouchi H, Kawakami S, Hirono S, Miyazaki H, Kimoto M, Arima T, et al. Prediction of outcome in fulminant hepatic failure by serum human hepatocyte growth factor. *Lancet* 1992;340:307.
  24. Miki C, Iniyama K, Strain A, Harrison JD, Hirono S, Gunson BK, et al. Clinical significance of serum hepatocyte growth factor in orthotopic liver transplantation. *Surgery* 1996;119:505-510.
  25. Ninomiya M, Harada N, Shiotani S, Hiroshige S, Minagawa R, Soejima Y, et al. Hepatocyte growth factor and transforming growth factor beta1 contribute to regeneration of small-for-size liver graft immediately after transplantation. *Transpl Int* 2003;16:814-819.
  26. Appasamy R, Tanabe M, Murase N, Zarnegar R, Venkataraman R, Van Thiel DH, Michalopoulos GK. Hepatocyte growth factor, blood clearance, organ uptake, and biliary excretion in normal and partially hepatectomized rats. *Lab Invest* 1993;68:270-276.
  27. Plate KH, Breier G, Weich HA, Risau W. Vascular endothelial growth factor is a potential tumour angiogenesis factor in human gliomas in vivo. *Nature* 1992;359:845-848.
  28. Shweiki D, Itin A, Soffer D, Keshet E. Vascular endothelial growth factor induced by hypoxia may mediate hypoxia-initiated angiogenesis. *Nature* 1992;359:843-845.
  29. Bense B, Brown LF, Van de Water L, Dvorak HF, Senger DR. Vascular permeability factor (vascular endothelial growth factor) gene is expressed differentially in normal tissues, macrophages, and tumors. *Mol Biol Cell* 1992;3:211-220.
  30. Shifren JL, Doldi N, Ferrara N, Mesiano S, Jaffe RB. In the human fetus, vascular endothelial growth factor is expressed in epithelial cells and myocytes, but not vascular endothelium: implications for mode of action. *J Clin Endocrinol Metab* 1994;79:316-322.
  31. Monacci WT, Merrill MJ, Oldfield EH. Expression of vascular permeability factor / vascular endothelial growth factor in normal rat tissues. *Am J Physiol* 1993;264:C995-C1002.
  32. Taniguchi E, Sakisaka S, Matsuo K, Tanikawa K, Sata M. Expression and role of vascular endothelial growth factor in liver regeneration after partial hepatectomy in rats. *J Histochem Cytochem* 2001;49:121-130.
  33. Granot E, Boros P, Miller CM. Differential effect of hepatocyte growth factor and tumor growth factor-beta on early release of vascular endothelial growth factor from HepG2 cells: possible implications in post-transplant liver regeneration. *Transplant Proc* 2001;33:2926-2928.
  34. Akiyoshi F, Sata M, Suzuki H, Uchimura Y, Mitsuyama K, Matsuo K, Tanikawa K. Serum vascular endothelial growth factor levels in various liver diseases. *Dig Dis Sci* 1998;43:41-45.
  35. Scharte M, Han X, Berges DJ, Fink MP, Delude RL. Cytokines induce HIF-1 DNA binding and the expression of HIF-1-dependent genes in cultured rat enterocytes. *Am J Physiol Gastrointest Liver Physiol* 2003;284:G373-G384.
  36. Tsugawa K, Hashizume M, Tomikawa M, Migou S, Kawanaka H, Shiraishi S, et al. Immunohistochemical localization of vascular endothelial growth factor in the rat portal hypertensive gastropathy. *J Gastroenterol Hepatol* 2001;16:429-437.
  37. Assy N, Paizi M, Gaitini D, Baruch Y, Spira G. Clinical implication of VEGF serum levels in cirrhotic patients with or without portal hypertension. *World J Gastroenterol* 1999;5:296-300.

# Are the Results of Surgical Treatment of Hepatocellular Carcinoma Poor if the Tumor has Spontaneously Ruptured?

S. Mizuno, K. Yamagiwa, T. Ogawa, M. Tabata, H. Yokoi, S. Isaji & S. Uemoto  
First Dept. of Surgery, Mie University School of Medicine, Tsu, Mie, Japan

Mizuno S, Yamagiwa K, Ogawa T, Tabata M, Yokoi H, Isaji S, Uemoto S. Are the results of surgical treatment of hepatocellular carcinoma poor if the tumor has spontaneously ruptured? *Scand J Gastroenterol* 2004;39:567-570.

**Background:** The aim of this study was to clarify whether the results of surgical treatment of ruptured hepatocellular carcinoma (HCC) are poorer than the results of surgical treatment of non-ruptured HCC. **Methods:** Out of a total of 224 HCC patients, the 6 patients with ruptured HCC were compared with 15 patients with non-ruptured HCC based on TNM stage IVA and having a Cancer of the Liver Italian Program (CLIP) score of 1 or 2. **Results:** There were no significant differences in clinical and pathological features between the two groups. The 1-year and 3-year overall survival rates were 69.3% and 21.2%, respectively, in the ruptured HCC group and 51.3% and 20.5%, respectively, in the non-ruptured HCC group. The 1-year and 3-year disease-free survival rates were 33.0% and 0%, respectively, in the ruptured HCC group and 38.9% and 15.6%, respectively, in the non-ruptured HCC group. The differences in survival rates between these two groups did not reach statistical significance. **Conclusion:** Hepatic resection as definitive treatment after recovery from the initial insult of the rupture of HCC yields results similar to those obtained by surgical treatment of non-ruptured HCC at the same tumor stage and with the same degree of liver damage.

**Key words:** Cancer of the Liver Italian Program (CLIP) prognostic score; ruptured hepatocellular carcinoma; TNM staging system

Shugo Mizuno, M.D., First Dept. of Surgery, Mie University School of Medicine, 2-174 Edobashi, Tsu, Mie, Japan (fax. +81 59 232 8095, e-mail. mizuno-s@clin.medic.mie-u.ac.jp)

Hepatocellular carcinoma (HCC) can present with a variety of symptoms depending on the stage of the disease, with spontaneous rupture of an HCC representing a life-threatening condition. In Japan, spontaneous rupture is the cause of death in 10% of all patients with HCC (1). In Asian and African countries, where the incidence of this neoplasm is relatively high, about 15% of HCC patients present with this complication (2, 3). While it is commonly agreed that spontaneous HCC rupture is a catastrophic presentation and associated with a poor outcome, surgical treatment cannot be performed in most of these cases, and there are few reports based on disease stage or liver function that describe negative effects of rupture on the surgical results compared with the results in patients without HCC rupture.

The tumor lymph-node-metastasis (TNM) staging system (4) is widely recognized as the standard basis for making the prognosis in most solid tumor systems. The current TNM staging system for HCC uses tumor size, presence of vascular invasion, and distribution of the tumor as criteria for T staging, and because of its poor outcome, ruptured HCC is classified as stage T4 and as stage IV based on the TNM staging system, whether liver function is good or not.

On the other hand, another prognostic index has recently

been devised by the Cancer of the Liver Italian Program (CLIP) investigators (5). Based on 435 cases from 16 centers, the investigators found that Child-Pugh grading, the distribution of the tumor,  $\alpha$ -fetoprotein (AFP) level, and portal vein thrombosis were independent predictive factors for survival. This scoring system is expected to be useful to both internal physicians and surgeons.

We report our findings based on a comparative study of the surgical outcome of ruptured HCC and non-ruptured HCC based on both the TNM stage and CLIP scores. The aim of this study was to determine whether the results of surgical treatment were poorer in the patients with ruptured HCC than in the patients with non-ruptured HCC.

## Patients and Methods

Among the 224 patients with HCC who underwent hepatic resection in Department of Surgery I of Mie University Hospital between May 1977 and December 2002, six (2.7%) were entered into this study as the ruptured HCC group. Since the tumor bleeding was controlled by transcatheter arterial embolization (TAE) in all six patients, they were given routine preoperative examinations and treated by elective surgery. The ruptured HCC group consisted of 3 men and 3



Table I. Clinical features

Parameter	Ruptured HCC (n = 6)	Non-ruptured HCC (n = 15)
Male/female	3/3	15/0
Age	53.8 ± 15.2	60.6 ± 9.3
HBs Ag-positive	3 (50.0%)	3 (20.0%)
HCV Ab-positive	1 (16.7%)	10 (66.7%)
AFP >400	3 (50.0%)	5 (33.3%)
Child-Pugh		
A	5 (83.3%)	13 (86.7%)
B	1 (16.7%)	2 (13.3%)
C	0	0

HBs Ag = hepatitis B surface antigen; HCV Ab = hepatitis C antibody; AFP =  $\alpha$ -fetoprotein.

women, and their ages ranged from 36 to 77 years (mean 55.6). On admission, all 6 patients had abdominal pain, tenderness, and were hypotensive. All 6 patients in the ruptured HCC group were classified according to the CLIP scoring system: 3 patients had a CLIP score of 1, and the other 3 had a CLIP score of 2. According to the TNM staging system, all 6 cases were stage IVA because of the occurrence of rupture and the absence of extrahepatic metastasis. In our hospital, the total number of non-ruptured Stage IVA patients was 34. 34 patients classified according to the CLIP scoring system: 8 patients had a CLIP score of 1, 7 had a CLIP score of 2, 13 patients had a CLIP score of 3, and 6 had a CLIP score of 4.

To assess the clinical features and long-term prognosis of ruptured HCC, we conducted a comparative study of a ruptured HCC group and 15 patients with non-ruptured HCC whose TNM stage was stage IVA and CLIP score was 1 or 2, and who had undergone hepatic resection during the same period, because all of the patients in the ruptured HCC group had CLIP scores of 1 or 2 (Table I). There were no statistically significant differences between the groups in age, percentage positive for hepatitis B surface antigen, percentage positive for hepatitis C, AFP levels, tumor size, or percentage with extrahepatic metastasis. All patients were periodically followed-up, and ultrasonography and a CT scan were performed at least once every 3 months.

Statistical analysis of differences between groups was performed by using either the paired Student's *t* test or the Fisher exact test. Survival rates were estimated by the Kaplan-Meier survival method. Statistical analysis was performed with the help of SPSS for Windows computer software (SPSS, Inc., Chicago, Ill., USA). All *P* values of less than 0.05 were considered statistically significant.

## Results

### Pathological features of the resected tumors

The pathological features of the resected specimens are summarized in Table II. All of the ruptured HCCs had a fibrous capsule and the difference was not significant, and there were no significant differences between the two groups

Table II. Pathological features of the resected tumors

Parameter	Ruptured HCC (n = 6)	Non-ruptured HCC (n = 15)
Tumor size (cm)	5.5 ± 1.3	3.9 ± 2.6
Fibrous capsule (%)	6 (100%)	11 (73.3%)
Capsule invasion/capsule (+)	100%	81.8%
Intrahepatic metastasis (%)	3 (50.0%)	5 (33.3%)
Venous invasion (%)	5 (83.3%)	6 (40.0%)

HCC = hepatocellular carcinoma.

in capsule invasion, intrahepatic metastasis, or venous invasion.

### Overall survival rates in the ruptured HCC group and the non-ruptured HCC group

The 1-year and 3-year overall survival rates were 69.3% and 21.2%, respectively, in the ruptured HCC group and 51.3% and 20.5%, respectively, in the non-ruptured HCC group; the differences in survival rates between the two groups did not reach statistical significance (*P* = 0.624) (Fig. 1).

### Disease-free survival rates in the ruptured HCC group and non-ruptured HCC group

The 1-year, and 3-year disease-free survival rates were 33.0% and 0%, respectively, in the ruptured HCC group and 38.9% and 15.6%, respectively, in the non-ruptured HCC group; the differences between the two groups in disease-free survival rates did not reach statistical significance (*P* = 0.712) (Fig. 2).

All 6 patients in the ruptured HCC group and 13 of the patients in the non-ruptured group experienced recurrence. In the ruptured HCC group, the recurrence was in a distant

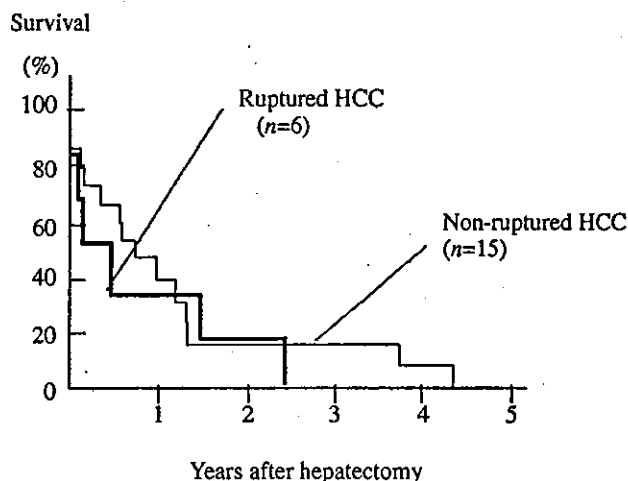


Fig. 1. Overall survival rates of the ruptured hepatocellular carcinoma (HCC) group and non-ruptured HCC group with TNM stage IVA disease and a Cancer of the Liver Italian Program (CLIP) score of 1 or 2 after surgery.

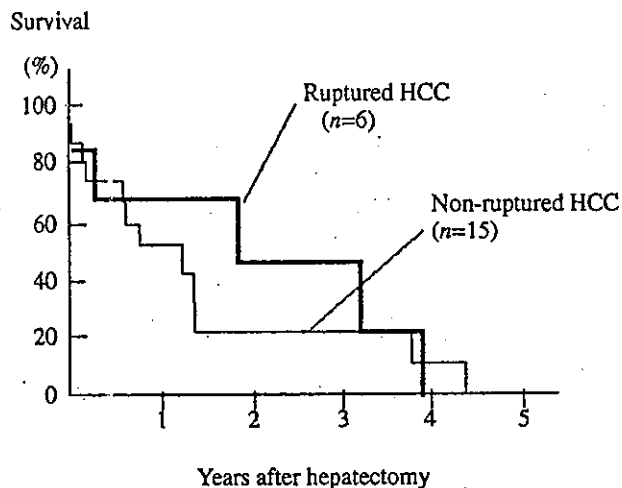


Fig. 2. Disease-free survival rates of the ruptured hepatocellular carcinoma (HCC) group and the non-ruptured HCC group with TNM stage IVA disease and a Cancer of the Liver Italian Program (CLIP) score of 1 or 2 after surgery.

region (lung) in 2 patients, occurred in the form of peritoneal dissemination in 3 patients, and occurred in the remnant liver in 6 patients. Similarly, in the non-ruptured group, the recurrence occurred in the form of peritoneal dissemination in 1 patient, in a distant region (lung, bone) in 3 patients, and in the remnant liver in 13 patients.

## Discussion

Although HCC can present with a variety of symptoms depending on the stage of the disease, spontaneous rupture is perhaps the most catastrophic presentation. About 15% of HCC patients develop this complication, and the highest incidences are seen in non-Western countries (2, 3). However, in our institution, 2.7% of HCC patients complained of ruptured HCC, because our institution is a university hospital and there were so many patients who were referred from another clinic for further examination or treatment, and there were few patients for emergency operations such as ruptured HCC.

The outcome of ruptured HCC has been reported to be poor because many patients harbor advanced disease at the time of presentation, the incidence of concomitant cirrhosis is high, diagnosis is often delayed, and malignant cells sometimes disseminate into the peritoneal cavity (6). The mortality of patients with ruptured HCC is claimed to be largely determined by the pre-rupture disease stage, liver function at the time of rupture, and the severity of bleeding from the rupture site (7). Nevertheless, comparisons between the long-term survival rate of patients with ruptured HCC and patients with non-ruptured HCC in terms of TNM stage of the disease and the severity of functional liver impairment have been rare (6). We believe this to be the first report on the surgical results in ruptured HCC in relation to TNM stage and the CLIP score.

Liu et al. (7) reported significantly poorer survival out-

comes among patients with ruptured HCC who underwent hepatectomy than the median survival of 49.2 months for patients with no history of tumor rupture who underwent hepatic resection for HCC during the same period. However, their study was not based on cases with the same background factors in terms of disease stage or liver function, such as TNM stage or CLIP score.

The UICC TNM classification is one of the most widely used staging systems for HCC, and a good correlation between overall and disease-free survival according to the Kaplan-Meier method and the pTNM stage of HCC has been reported. Poon et al. (8) found that the overall survival of 106 stage IVA patients was significantly worse than that of stage I, II, or III patients, with the 1- 3- and 5-year survival rates of the stage IVA patients being 59.0%, 28.1%, and 17.8%, respectively. Ikai et al. (9) reported a 5-year survival rate of 15% after resection in stage IVA cases, a significantly poorer rate than that of the stage I to III patients. The 1- and 3-year overall survival rates in the ruptured HCC group and non-ruptured HCC group in TNM stage IVA in the present study showed similar results.

Recently, however, Usatoff et al. (10) reported poor survival rates after resection of stage IVA HCC in patients with cirrhosis (3-year survival rate: 0%), and the researchers responsible for that report concluded that hepatic resection for stage IVA HCC should be avoided in cirrhotic patients. Their report suggests that liver damage should also be considered in evaluating the surgical results in stage IV HCC patients.

The CLIP scoring system includes four parameters (Child-Pugh grading, distribution of tumor, AFP level, and portal vein thrombosis) and it has been confirmed to provide more accurate prognostic information and to have greater predictive power for survival (5, 11). However, few reports have used the CLIP score for HCC patients after resection and then assessed its prognostic value, because CLIP scores are based on the prognostic parameters of patients with unresectable lesions. Zhao et al. (12) suggested that CLIP scores are significantly associated with early and late recurrence, whereas TNM stages are associated with early recurrence alone; in other words, that the risk of early recurrence depends on primary tumor factors, whereas the risk of late recurrence depends on underlying liver status.

The most important task is to determine whether the results of surgical treatment of patients with ruptured HCC are poorer than the results of surgical treatment of patients with non-ruptured HCC. In the present study, no statistically significant difference was found between the overall surgical survival rates of patients with ruptured and non-ruptured HCC who had TNM stage IVA disease and a CLIP score of 1 or 2. Nor was there any statistically significant difference between the overall surgical survival rates of patients with ruptured and non-ruptured HCC with the same tumor stage and the same liver damage. These results suggest that the outcome of the patients with ruptured HCC was as good as that of the patients with non-ruptured HCC who had the same tumor

stage lesions and the same liver damage in cases in which the surgical treatment of ruptured HCC was performed after improving their condition by conservative treatment, such as TAE.

In conclusion, hepatic resection as the definitive treatment after recovery from the initial insult of HCC rupture yields results equivalent to those obtained by surgical treatment of non-ruptured HCC in patients with the same tumor stage and the same liver damage.

References

1. The Liver Cancer Study Group of Japan: Primary liver cancer in Japan: clinicopathologic features and results of surgical treatment. *Ann Surg* 1990;211:277-87.
2. Ong GB, Chu EPH, Yu F, Lee TC. Spontaneous rupture of hepatocellular carcinoma. *Br J Surg* 1965;52:132-29.
3. Chearanai O, Plengvanit U, Asavanich C, Damrongsak D, Sindhvananda K, Boonyapisit S. Spontaneous rupture of primary hepatoma: report of 63 cases with particular reference to the pathogenesis and rationale treatment by hepatic artery ligation. *Cancer* 1983;51:1532-6.
4. Sobin LH, Wittekind C, editors. *TNM classification of malignant tumors*. 5th ed. New York: John Wiley & Sons; 1997.

5. Cancer of the Liver Italian Program (CLIP) Investigators. A new prognostic system for hepatocellular carcinoma: a retrospective study of 435 patients. *Hepatology* 1998;28:751-5.
6. Zhu LX, Wang GS, Fan ST. Spontaneous ruptured hepatocellular carcinoma. *Br J Surg* 1996;83:602-7.
7. Liu CL, Fan ST, Lo CM, Tso WK, Poon RT, Lam CH, et al. Management of spontaneous rupture of hepatocellular carcinoma: single-center experience. *J Clin Oncol* 2001;19:3725-32.
8. Poon RT, Fan ST, Ng IO, Wong J. Prognosis after hepatic resection for Stage IVA hepatocellular carcinoma. *Ann Surg* 2003; 237:376-83.
9. Ikai I, Yamaoka Y, Yamamoto Y, Ozaki N, Sakai Y, Satoh S, et al. Surgical intervention for patients with stage IV-A hepatocellular carcinoma without lymph node metastasis. Proposal as a standard therapy. *Ann Surg* 1998;227:433-9.
10. Usatoff V, Isla AM, Habib NA. Liver resection in advanced hepatocellular carcinoma. *Hepato-Gastroenterology* 2001;48:46-50.
11. Cancer of the Liver Italian Program (CLIP) Investigators. Prospective validation of the CLIP score: a new prognostic system for patients with cirrhosis and hepatocellular carcinoma. *Hepatology* 2000;31:840-5.
12. Zhao WH, Ma ZM, Zhou XR, Feng YZ, Fang BS. Prediction of recurrence and prognosis in patients with hepatocellular carcinoma after resection by use of CLIP score. *World J Gastroenterol* 2002;8:237-42.

Received 3 October 2003  
 Accepted 4 February 2004

## Early graft hemodynamics in living related liver transplantation evaluated by Doppler ultrasonography

SHIGEO NAKANISHI<sup>1</sup>, KATSUYA SHIRAKI<sup>1</sup>, KOUJI YAMAMOTO<sup>1</sup>, YUKIKO SAITOU<sup>1</sup>,  
SHIGERU OHMORI<sup>1</sup>, TAKESHI NAKANO<sup>1</sup>, SHUGO MIZUNO<sup>2</sup>, MASAMI TABATA<sup>2</sup>,  
KENTAROU YAMAGIWA<sup>2</sup>, HAJIME YOKOI<sup>2</sup>, SHUJI ISAJI<sup>2</sup> and SHINJI UEMOTO<sup>2</sup>

<sup>1</sup>First Department of Internal Medicine, <sup>2</sup>First Department of Surgery,  
Mie University School of Medicine, Tsu, Mie 514-8507, Japan

Received November 25, 2003; Accepted January 20, 2004

**Abstract.** The aim of this study was to clarify the perioperative hemodynamics of liver grafts without vascular complications during and early after liver transplantation from living donors. This study was carried out in 4 child recipients (lateral segment left lobe grafts) and 6 adult recipients (right lobe grafts) of liver transplantation from living donors. The hemodynamics of the hepatic artery, portal vein, and hepatic vein of the grafts during and until 7 days after surgery were studied by Doppler ultrasonography. The maximum flow velocity of the hepatic artery, mean portal blood flow velocity, and pulsatility index (PI) of the hepatic artery increased in all 10 grafts with no vascular complication after vascular anastomosis. After surgery, the mean portal blood flow velocity showed a peak 3 days after surgery and reached a nadir 7 days after surgery in both the lateral segment left lobe grafts in children and the right lobe grafts in adults, but it was significantly higher in the right lobe grafts in adults (mean  $\pm$  SD 31.0 $\pm$ 6.3 vs. 22.4 $\pm$ 0.9 cm/sec). Also, as the hepatic artery blood flow velocity increased the portal blood flow velocity decreased, the hepatic blood flow during liver regeneration was suggested to be controlled by both the artery and portal vein. The range of PI of the hepatic artery was 0.60-1.86. The mean hepatic venous blood flow was stable throughout the observation period (30.4 $\pm$ 8.8 cm/sec). Although the hepatic venous flow waves changed widely from pulsed waves to a flat flow, its changes did not suggest a vascular complication. Evaluation of changes by Doppler ultrasonography in the hemodynamics of the liver grafts without vascular complications during and early after liver transplantation from living donors is considered to be useful for accurate monitoring of the hemodynamics during liver regeneration and early detection of abnormalities.

### Introduction

In an early period of liver transplantation from living donors, the lateral segment of the liver or the left lobe was grafted primarily to children, but liver transplantation to adults from living donors using left lobe grafts came to be performed later, and liver transplantation to adults using right lobe grafts began to be performed to alleviate the effect of an insufficient graft volume. The use of right lobe grafts and improvements in the surgical technique have led to increases in the number of adult cases of liver transplantation from living donors, which now exceeds the number of pediatric cases of liver transplantation in Japan.

The survival rate after liver transplantation from living donors has improved annually, and the 5-year survival rate is over 80% today. This is a result of improvements in the skill of liver transplantation from living donors and improvements in perioperative management by means of immunosuppressants, and measures to prevent infections and vascular complications. According to recent reports, the incidence of hepatic artery thrombosis has decreased due to the spread of microsurgery to less than 10% in adults who received liver transplantation from brain-dead donors and to about 10% in children (1-3). Also, the incidence of hepatic artery thrombosis has been reported to be high in children aged less than 1 year and markedly atherosclerotic elderly patients (4,5). Vascular complications are likely to occur early after partial liver transplantation from living donors, because the vessels that are anastomosed such as the hepatic artery and portal vein are smaller, and because displacement of hepatic venous anastomoses are more likely to occur, than in whole liver transplantation. Intraoperative and post-operative vascular complications (particularly hepatic artery thrombosis, portal thrombosis) are often fatal. The incidences of early and late hepatic artery thromboses are not significantly different, being 1.9-5.4%, but the mortality due to early thrombosis is high at 55.6% compared with 15.0-22.6% due to late thrombosis (1,2). Therefore, greater caution is needed in the management of vascular complications early after grafting.

Early diagnosis of vascular complications facilitates their treatment. Therefore, it is important to examine each blood

*Correspondence to:* Dr Katsuya Shiraki, First Department of Internal Medicine, Mie University School of Medicine, 2-174 Edobashi, Tsu, Mie 514-8507, Japan  
E-mail: katsuyas@clin.medic.mie-u.ac.jp

**Key words:** graft hemodynamics, liver transplantation, Doppler ultrasonography

Table I. Summaries of recipients of the living related liver transplantation.

Recipients	Age	Sex	Underlying disease	Graft of transplantation	Weight of graft (g)	GRWR
1	61	F	PBC	RG	660	1.57
2	42	M	LC(C)	RG	650	1.33
3	2	M	BA	LLG	250	2.00
4	47	F	PBC	RG	660	0.88
5	51	M	LC(C) + HCC	RG	650	1.02
6	1	F	BA	LLG	270	3.68
7	5	F	BA	LLG	260	1.53
8	5	F	BA	LLG	260	1.53
9	51	M	LC(NBNC) + HCC	RG	670	0.92
10	55	M	LC(C) + HCC	RG	480	0.91

F, female; M, male; PBC, primary biliary cirrhosis; LC(C), liver cirrhosis of the C type; HCC, hepatocellular carcinoma; BA, biliary atresia; LC(NBNC), liver cirrhosis of the non-C and non-B type; GRWR, graft recipient weight ratio; RG, right graft; LLG, left lateral graft.

vessel during and after surgery and diagnose complications early by the use of pulsed Doppler ultrasonography (Doppler US), which is easy to perform and non-invasive. To predict early hemodynamic abnormalities, knowledge of the hemodynamics of grafts without vascular complications is important. Most of the reports of evaluation of the hepatic vascular hemodynamics after liver transplantation from living donors by Doppler US are about abnormal changes in the hemodynamics in liver grafts with vascular complications, and there have been few detailed reports of the hemodynamics of the hepatic artery, portal vein, and hepatic vein in liver grafts from living donors without vascular complications during and early after liver transplantation. In this study, therefore, we evaluated the hemodynamics of the hepatic artery, portal vein, and hepatic vein of liver grafts from living donors without vascular complications early after transplantation (during and until 7 days after surgery) by Doppler ultrasonography to clarify the hemodynamics of liver grafts from living donors early after transplantation.

### Materials and methods

The subjects were 10 recipients of partial liver transplantation from living donors performed at Mie University School of Medicine between March and October 2002 consisting of 4 children and 6 adults. The patients, 5 males and 5 females, were aged 1-61 years. The diseases of the recipients were biliary atresia (BA) in 4, primary biliary cirrhosis (PBC) in 2, and type C liver cirrhosis (C-LC) in 4 including 3 patients with type C liver cirrhosis complicated by hepatocellular carcinoma (C-LC + HCC). Lateral segment left lobe grafts (LLG) were transplanted to the 4 children (aged 1-5 years), and right lobe grafts (RG) were transplanted to the 6 adults (aged 51-61 years). The graft recipient weight ratio (GRWR) was greater than 0.8%, a widely accepted criteria, in all patients (Table I). The hemodynamics of the graft livers were studied by ultrasonography using an ALOKA SSD5500.

Evaluation was made at 5 points: immediately after vascular anastomosis during operation (DOP), immediately after

operation (JPO), 1 day after operation (1POD), 3 days after operation (3POD), and 7 days after operation (7POD). The evaluation items at each point were the maximum hepatic artery blood flow velocity (HA Vmax cm/sec), hepatic artery pulsatility index (HAPI), mean portal blood flow velocity (PV Vmean cm/sec), mean hepatic vein blood flow velocity (HV Vmean cm/sec), and hepatic vein blood flow waves. An intraoperative linear probe (central frequency 7.5 MHz) was used during surgery, and a convex type probe (central frequency 3.5 MHz) was used at JPO and thereafter.

During surgery, the intraoperative probe was brought into direct contact with the liver, and the measurements were performed at sites closer to the anastomosed part in the hepatic artery and portal vein and at a site closer to the origin of the inferior vena cava in the hepatic vein. After surgery, the measurements were made by right intercostal scanning at the same sites as the intraoperative measurements as much as possible.

The blood flow was measured by setting the sample volume at a level slightly narrower than the diameter of the vessel to be measured to avoid noise due to the vessel. The incidence angle of ultrasound relative to the blood vessel was set at 60° or less to minimize errors of measurement. Doppler signals obtained during a short period were selected, Doppler shifts were calculated using a fast Fourier transformation apparatus, the shifted frequency spectra were visualized, and flow waves were displayed. Two to three of the flow waves were traced, and the maximum flow velocity, minimum flow velocity, and mean flow velocity were calculated automatically. As an index of the peripheral vascular resistance of the hepatic artery, PI was calculated automatically by the formula (maximum flow velocity - minimum flow velocity/mean flow velocity). Hepatic vein blood flow waves were classified into triphasic waves in which a retrograde flow was observed in the first phase followed by antegrade flows in the subsequent two phases, biphasic waves in which no retrograde flow was observed in the first phase and only an antegrade flow of the second phase was observed, and a flow flow that showed no pulsation.

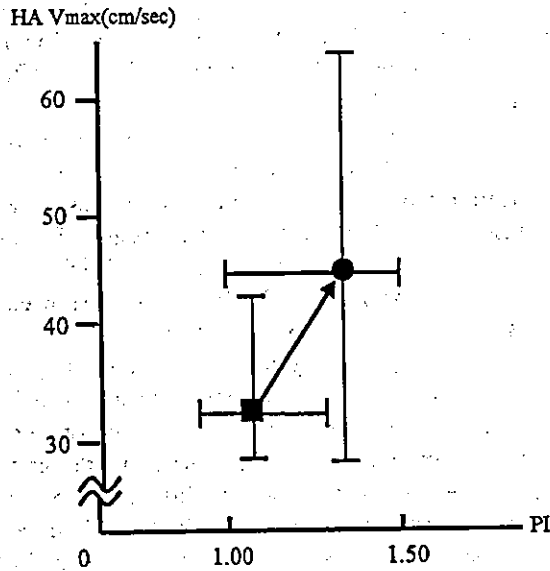


Figure 1. Changes in peak systolic velocity and pulsatility index of hepatic artery without arterial or other complications. HA Vmax, peak systolic velocity of hepatic artery; PI, pulsatility index of hepatic artery; ■, during operation; ●, just post-operation.

**Results**

**Doppler US of the hepatic artery.** The hemodynamics of the hepatic artery of the liver grafts were evaluated. The peak blood flow velocity of the hepatic artery (HA Vmax; mean ± SD; cm/sec) and hepatic artery pulsatility index (HAPI; mean ± SD) were 34.0±8.7 and 1.04±0.22, respectively, during operation (DOP) but increased to 44.0±22.8 and 1.40±0.34, respectively, immediately after operation (JPO) in the recipients of both right lobe grafts (RG group) and those of lateral segment left lobe grafts (LLG group) (Fig. 1). Therefore, the end of operation was suggested to cause marked changes in HA Vmax and HAPI.

HA Vmax in the recipients of RG group and those of LLG group were 34.0±8.7 and 29.8±17.3 at DOP, 44.0±22.8 and 38.9±13.6 at JPO, 55.1±26.6 and 51.0±12.9 at IPOD, 65.3±37.4 and 28.9±4.7 at 3POD, and 61.9±25.5 and 41.7±9.1 at 7POD, respectively. In the RG group, HA Vmax increased until 3POD and decreased slightly at 7POD, but no significant difference was observed between 3POD and 7POD. In the LLG group, it increased until IPOD, decreased at 3POD, but increased again at 7POD. HAPI in the RG and LLG groups were 1.04±0.22 and 1.34±0.28 at DOP, 1.40±0.34 and 1.33±0.23 at JPO, 1.52±0.41 and 0.96±0.14 at IPOD, 1.21±0.42 and 1.08±0.13 at 3POD, and 1.12±0.32 and 0.85±0.19 at 7POD, respectively. In the RG group, HAPI reached a peak at IPOD and decreased progressively until 7POD. In the LLG group, it decreased slightly from JPO to IPOD but showed no significant change and remained nearly stable thereafter (Fig. 2).

**Doppler US of the portal vein.** The portal hemodynamics of the liver grafts were evaluated. The mean portal blood flow velocity (PV Vmean; mean ± SD; cm/sec) increased from 32.6±10.9 at DOP to 64.3±23.9 at JPO similarly to HA Vmax. However, it decreased with time after operation to

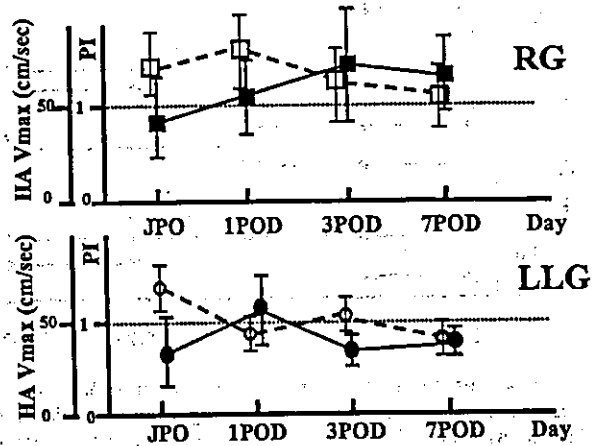


Figure 2. Peak systolic velocity and mean PI without arterial or other complications after surgery. HA Vmax, peak systolic velocity of hepatic artery; HA PI, pulsatility index of hepatic artery; JPO, just post-operative; POD, post-operative day; LLG, left lateral graft; RG, right graft; ■, HA Vmax of RG; □, PI of RG; ●, HA Vmax of LLG; ○, PI of LLG.

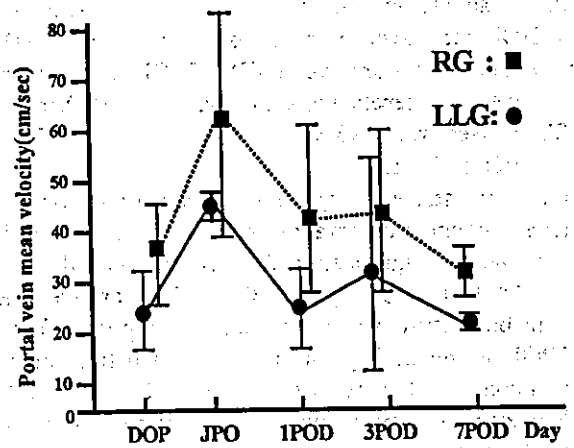


Figure 3. Portal vein mean velocity without arterial or other complications during operation and after surgery. DOP, during operation; JPO, just post-operative; POD, post-operative day; RG, right graft; LLG, left lateral graft.

47.0±19.3 at IPOD, 42.2±16.3 at 3POD, and 26.3±4.1 at 7POD with decreases in variation unlike HA Vmax. Also, it increased from DOP to JPO in both the RG and LLG groups from 34.0±10.9 and 24.15±7.7 to 63.0±25.1 and 35.2±7.9, respectively. While it decreased after JPO in the RG group to 31.0±6.3 at 7POD, it decreased to 20.8±12.9 at IPOD, increased to 32.9±2.4 at 3POD, and decreased again to 22.4±0.9 at 7POD in the LLG group (Fig. 3). Thus, changes in PV Vmean were opposite to those in HA Vmax in the LLG group, suggesting dual control of the hepatic hemodynamics by the portal vein and hepatic artery.

**Doppler US of the hepatic vein.** Finally, the hepatic vein blood flow waves and mean hepatic vein blood flow velocity of the liver grafts were evaluated. The hepatic vein blood flow waves were consistently biphasic from DOP to 7POD in the 4 patients of the LLG group. In the RG group, they were triphasic in 2 patients and biphasic in 2, and a flat flow with no pulsation in 2 at DOP. In the 4 patients who showed

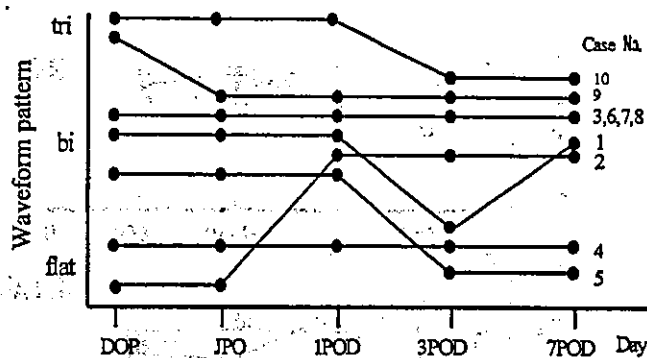


Figure 4. Changes in waveform pattern of intra hepatic vein without complications during operation and after surgery. tri, triphasic; bi, biphasic; flat, flat waveform; DOP, during operation; JPO, just post-operation; POD, post-operation day.

triphasic or biphasic waves at DOP, some changes in the waveform, which ranged from pulsed waves to a constant flow, were noted in the subsequent course, and the pattern became biphasic in 3 and a constant flow in 1 at 7POD. Of the 2 patients who showed a constant flow without pulsation at DOP, the waveform changed to biphasic at 7POD in 1, but it remained constant from DOP to 7POD in the other (Fig. 4).

The mean hepatic blood flow velocity (HV Vmean; mean  $\pm$  SD; cm/sec) was  $30.8 \pm 8.0$  at DOP,  $28.1 \pm 8.7$  at JPO,  $31.9 \pm 8.9$  at IPOD,  $29.5 \pm 3.1$  at 3POD, and  $32.1 \pm 11.2$  at 7POD, remaining stable throughout the observation period. The mean ( $\pm$  SD) of entire observation period was  $30.4 \pm 8.8$  in all patients and was not significantly different between the LLG group ( $30.4 \pm 11.0$ ) and RG group ( $30.5 \pm 8.1$ ). Moreover, the hepatic vein blood flow waveform remained biphasic from DOP to 7POD in the LLG group, but it changed from pulsed waves to a constant flow between DOP and 7POD in the RG group. However, HV Vmean was nearly constant despite changes in the blood flow wave pattern.

## Discussion

In liver grafts from living donors, vascular complications are likely to occur because of the small diameters of the anastomosed vessels, particularly the arteries, and they may be fatal once they occur. Therefore, caution is needed early after grafting. In this study, we evaluated the hemodynamics of liver grafts early after transplantation by Doppler ultrasonography to obtain basic data for early detection of intraoperative and post-operative vascular complications.

Measures to facilitate scanning with the probe such as lifting or twisting the graft were needed in the Doppler study at DOP. When the Doppler study was performed again after placing the graft at an appropriate place and closing the laparotomy, the portal blood flow velocity increased with the hepatic artery blood flow velocity and PI, but no significant change was observed in the hepatic vein blood flow velocity. Fujimoto *et al* reported that appropriate adjustment of the position of the graft during operation resolved twisting of the base of the hepatic artery and increased the hepatic artery blood flow velocity and PI (7). Therefore, closing of laparotomy is a factor that affects the blood flow velocity, and Doppler ultrasonography is needed both immediately after anastomosis of

blood vessels and on closing of laparotomy. We evaluated the effect of closing of laparotomy by carrying out Doppler studies both after suturing of blood vessels (DOP) and after closing of laparotomy (JPO).

There have not been many reports on the hemodynamics of liver grafts not having vascular complications in an early perioperative period. In our child cases (4 cases), HA Vmax increased from DOP to JPO, reached a peak at IPOD, showed a nadir at 3POD, and increased again at 7POD. In addition, PV Vmean increased from DOP to JPO but showed opposite changes thereafter compared with HA Vmax. The liver is known to be supplied by both the hepatic artery and portal vein. However, no report has indicated dual supply of liver grafts from living donors without vascular complications by the hepatic artery and portal vein during or after graft surgery. We obtained results that indicate dual supply by the hepatic artery and portal vein particularly in the 4 child cases. Also, PV Vmean (mean  $\pm$  SD; cm/sec) was higher at  $31.0 \pm 6.3$  in the adults than  $22.4 \pm 0.9$  in the children at 7POD, probably because many adult patients had liver cirrhosis, and a hyperdynamic state persisted in them for a period after surgery (11-13).

In our adult patients, HA Vmax (mean  $\pm$  SD; cm/sec) showed a nadir ( $34.0 \pm 8.7$ ) at DOP and a peak at 3POD and decreased slightly at 7POD. HAPI reached a peak at IPOD and a nadir at 7POD in the adults but showed a peak at JPO and decreased at 7POD in the children. Data concerning HA Vmax and PI have been reported by Fujimoto *et al* in 92 children over 12 months from operation (7) and by Sameda *et al* in 43 children over 14 days from operation (8). According to these reports, HA Vmax (mean  $\pm$  SD; cm/sec) was highest at DOP ( $52 \pm 21$  and  $53 \pm 16$ , respectively) and decreased until 7POD ( $44 \pm 15$  and  $39 \pm 12$ , respectively). However, HAPI was maximum at IPOD ( $1.81 \pm 0.72$  and  $1.59 \pm 0.68$ , respectively) and minimum at 7POD ( $1.44 \pm 0.46$  and  $1.26 \pm 0.39$ ). Cheng *et al* (9) also reported intraoperative values of HA Vmax and PI in 5 adults and 19 children. According to this report, HA Vmax and PI (mean  $\pm$  SD; cm/sec) were  $61.2 \pm 16.2$  and  $1.67 \pm 0.31$  in the adults and  $50.4 \pm 11.5$  and  $1.55 \pm 0.32$  in the children, respectively, both being higher in the adults. In our child patients, HAPI showed a peak at the end of operation, slightly earlier than in the cases of Cheng *et al* (9), but a nadir at 7POD similarly to their report. Intraoperative and post-operative changes in HAPI exclusively in adults have not been reported. The intraoperative values of HA Vmax and PI in adult patients reported by Cheng *et al* (9) were higher than ours. However, while the adult patients of Cheng *et al* (9) received whole liver transplantation, our adult patients received partial right lobe grafts from living donors.

HAPI is widely used as an index of the vascular resistance. For example, a high PI indicates strong vascular resistance and a low PI indicates weak vascular resistance. We measured the hepatic artery blood flow velocity at a point distal to the anastomosed part of the hepatic artery. Therefore, if there is obstruction or stenosis at the anastomosis site, the maximum blood flow velocity of the hepatic artery decreases at the measurement point distal to the stenosed area, and the time until the peak blood flow velocity is prolonged, causing a decrease in PI. However, if obstruction or stenosis occurs distally to the measurement point, the maximum flow velocity

is unchanged or reduced, and the minimum blood flow velocity markedly decreases, causing an increase in PI. Therefore, a marked increase in PI suggests obstruction or stenosis at a site distal to the measurement point, and the range of PI (0.60-1.86) is considered to have the greatest significance.

According to our measurements, the hepatic vein blood flow velocity at the end of operation was  $28.1 \pm 8.7$  cm/sec in children and  $30.4 \pm 11.4$  cm/sec in adults with no significant difference. Cheng *et al* (9) reported intraoperative hepatic vein blood flow velocities of  $25.3 \pm 7.2$  cm/sec for children and  $28.0 \pm 11.9$  cm/sec for adults with no significant difference between children and adults similarly to our results. Also, the mean  $\pm$  SD of HV Vmean during the entire observation period from during operation to 7POD was  $30.4 \pm 11.1$  cm/sec in children and  $30.5 \pm 8.1$  cm/sec in adults, and no significant difference was observed between the two groups or among the measurement points in each group. Someda *et al* (8) reported a mean  $\pm$  SD of  $24.3 \pm 8.8$  cm/sec ( $20.7 \pm 7.6$  at DOP,  $25.4 \pm 10.6$  at IPOD, and  $24.3 \pm 7.6$  at 7POD) in 46 children. Although the values were slightly smaller than ours, they noted no significant difference among measurement points similarly to us. Also, according to our evaluation, hepatic vein blood flow pattern was consistently biphasic in the children. In the adults, the blood flow pattern was pulsed biphasic or triphasic waves in 5 of the 6 patients at DOP, and it changed to pulsed patterns in 4 of the 5 patients and to a flat pattern in 1 at 7POD. In 1 adult, the pattern remained flat from DOP to 7POD. According to Someda *et al* (8), the flow waveform was pulsed (biphasic or triphasic) in 95% and flat in 5% of the 46 children at DOP. However, they reported that a flat pattern was observed 55% and pulsed patterns were observed in 45% at 7POD (9). Britton *et al* (13) reported hepatic vein waveforms during acute rejection after liver transplantation in 50 children. According to their report, when rejection occurred, a decrease in pulsation of the hepatic vein blood flow was noted before biochemical or clinical manifestations in 10 patients. However, they also reported pulsation in 2 patients and regular triphasic waves in 1 despite rejection (13). Moreover, Cheng *et al* reported that a decrease in hepatic vein Vmax (to 10 cm/sec or less) followed by a decrease in the portal blood flow as an indication of abnormality (9).

The hepatic vein blood flow forms triphasic waves in which the first phase is a retrograde flow during atrial systole associated with closing of the tricuspid valve, and the second and third phases are antegrade flows corresponding to the 2 periods of atrial dilation. As hepatic vein outflow disorder becomes severe, the outflow waveform is flattened, and the flow velocity decreases. These changes are caused by extension, flexion, or twisting of the anastomosis site of the hepatic vein due to graft displacement and intraperitoneal hematoma. We observed a change from a pulsed pattern to a flat pattern in 1 adult and persistence of a flat pattern throughout the observation period in 1 adult, but there was no difference in the hepatic vein blood flow velocity between these patients and the other patients who showed pulsed patterns (range 17.5-32.3 cm/sec), and no rejection or decrease in pulsation of the hepatic vein blood flow described by Britton *et al* (13) was observed. Therefore, abnormal outflow waveforms of the hepatic vein associated with rejection are considered to accompany a decrease in the hepatic vein blood

flow velocity as well as flattening of the hepatic vein blood flow pattern. Furthermore, Cheng *et al* (9) evaluated the hepatic vein blood flow velocity according to Vmax. We however, evaluated the hepatic vein blood flow velocity according to Vmean to facilitate detection of differences in the blood flow velocity according to changes in the waveform. As a result, vascular complication was suggested to be unlikely if the mean flow velocity is  $30.4 \pm 8.8$  cm/sec even when the waveform is flat.

Thus, in this study, dual supply of the hepatic blood flow was confirmed also in the liver regeneration period after grafting, and the importance of the range of HAPI was suggested. Also, changes in the hepatic vein blood flow pattern alone are not considered to suggest vascular complications. Evaluation of changes in the blood flow after liver transplantation from living donors is considered to be extremely important for monitoring of the state of regeneration of the graft liver and early detection of complications.

## References

- Oh CK, Pelletier SJ, Sawyer RG, Dacus AR, McCullough CS, Pruett TL and Sanfey HA: Uni and multi-variate analysis of risk factors for early and late hepatic artery thrombosis after liver transplantation. *Transplantation* 71: 767-772, 2001.
- Bhattacharjya S, Gunson BK, Mirza DF, Mayer DA, Buckels JA, McMaster P and Neuberger JM: Delayed hepatic artery thrombosis in adult orthotopic liver transplantation - a 12-year experience. *Transplantation* 71: 1592-1596, 2001.
- Madalosso C, De Souza NF Jr, Ilstrup DM, Wiesner RH and Krom RA: Cytomegalovirus and its association with hepatic artery thrombosis after liver transplantation. *Transplantation* 66: 294-297, 1998.
- Stevens LH, Emond JB, Heffron TG, Thistlethwaite JR Jr, Whittington PF and Broelsch CE: Hepatic artery thrombosis in infants: a comparison of whole livers, reduced-size allograft and allograft from living-related donors. *Transplantation* 53: 396-399, 1992.
- Deba Key ME, Lawrie GM and Glaeser DH: Patterns of atherosclerosis and their surgical significance. *Ann Surg* 201: 115-131, 1985.
- Saad S, Tanaka K, Inomata Y, Uemoto S, Ozaki N, Okazima H, Egawa H and Yamaoka Y: Portal vein reconstruction in pediatric liver transplantation from living donors. *Ann Surg* 227: 275-281, 1998.
- Fujimoto M, Moriyasu F, Nada T, Inomoto T, Tanaka K and Yamaoka Y: Hepatic arterial complications in pediatric segmental liver transplantations from living donors: assessment with color Doppler ultrasonography. *Clin Transplant* 11: 380-386, 1997.
- Someda H, Moriyasu F, Fujimoto M, Hamato N, Nabeshima M, Nishikawa K, Okuma M, Tanaka K and Ozawa K: Vascular complications in living related liver transplantation detected with intraoperative and postoperative Doppler US. *J Hepatol* 22: 623-632, 1995.
- Cheng YF, Huang TL, Chen CL, Lee TY, Chen TY, Chen YS, Liu PP, Chiang YC, Eng HL, Wang CC, Cheung HK, Jawan B and Goto S: Intraoperative Doppler ultrasound in liver transplantation. *Clin Transplant* 12: 292-299, 1998.
- Herold C, Reck T, Ott R, *et al*: Changes in hepatic hemodynamics after orthotopic liver transplantation: color Doppler sonography. *Abdom Imaging* 26: 32-35, 2001.
- Henderson JM, Gilmore GT, Mackay GJ, *et al*: Hemodynamics during liver transplantation; the interactions between cardiac output and portal venous and hepatic arterial flows. *Hepatology* 16: 715-718, 1992.
- Asakura T, Ohkohchi N, Katoh H, *et al*: Doppler ultrasonography in living-related liver transplantation. *Transplant Proc* 30: 3190-3194, 1998.
- Britton PD, Lomas DJ, Coultren RA, *et al*: The role of hepatic vein Doppler in diagnosing acute rejection following pediatric liver transplantation. *Clin Radiol* 45: 228-232, 1992.



# Outflow block secondary to stenosis of the inferior vena cava following living-donor liver transplantation?

Mizuno S, Yokoi H, Yamagiwa K, Tabata M, Isaji S, Yamakado K, Takeda K, Uemoto S. Outflow block secondary to stenosis of the inferior vena cava following living-donor liver transplantation?  
 Clin Transplant 2004 DOI: 10.1111/j.1399-0012.2004.00321.x  
 © Blackwell Munksgaard, 2004

Shugo Mizuno<sup>a</sup>, Hajime Yokoi<sup>a</sup>, Kentaro Yamagiwa<sup>a</sup>, Masami Tabata<sup>a</sup>, Shuji Isaji<sup>a</sup>, Koichiro Yamakado<sup>b</sup>, Kan Takeda<sup>b</sup> and Shinji Uemoto<sup>a</sup>

<sup>a</sup> First Department of Surgery and <sup>b</sup> Department of Radiology, Mie University School of Medicine, Mie, Japan

**Abstract:** Although it is well known that outflow block is caused by stenosis or occlusion of hepatic vein anastomoses following living donor liver transplantation (LDLT), there have been few reports on inferior vena cava (IVC) stenosis following LDLT. In this paper, we report two cases of IVC stenosis and hepatic vein outflow block following right hepatic LDLT in the absence of stenosis of any of the anastomoses. Both patients presented with liver dysfunction, an ascitic fluid volume of approximately 2000 mL, and congestion in their biopsy specimens, and venocavography demonstrated IVC stenosis with gradients of more than 10 mmHg in patients with a dominant inferior right hepatic vein (IRHV) anastomosis. After a Gianturco expandable metallic stent successfully implanted in the IVC, the patient's liver function recovered and the volume of ascitic fluid decreased. The pathogenesis of hepatic vein outflow block secondary to IVC stenosis following LDLT may involve the anastomosis with the IRHV, which is the dominant draining vein of the graft and larger than the RHV, caudal to the IVC stenosis and a significant IVC pressure gradient that results in increased IRHV pressure. In conclusion, it is important to include hepatic vein outflow block in the differential diagnosis when patients who have undergone right hepatic LDLT in which anastomosis of the large IRHV has been performed develop manifestations of liver dysfunction.

**Key words:** Gianturco Z stent - inferior vena cava stenosis - living-donor liver transplantation - outflow block

Corresponding author: Shugo Mizuno, First Department of Surgery, Mie University School of Medicine, 2-174 Edobashi, Tsu, Mie, 514-0001, Japan.  
 Tel.: +81 59 232 1111 (ext. 6470);  
 fax: +81 59 232 8095;  
 e-mail: mizuno-s@clin.medic.mie-u.ac.jp

Accepted for publication 27 October 2004

Outflow block or Budd-Chiari syndrome after orthotopic liver transplantation (OLT) develops as a result of anastomotic stenosis or occlusion of the inferior vena cava (IVC), whereas almost all cases of outflow block syndrome after living donor liver transplantation (LDLT) are the result of stenosis or occlusion of the hepatic vein anastomosis. These potentially lethal complications are manifested by deteriorating hepatic and renal function, hypotension, declining cardiac output, edema of the lower extremities, and massive ascites (1, 2). However, there have been few reports of outflow block syndrome in patients who developed IVC stenosis with a pressure gradient greater than 10 mmHg after LDLT in the absence of stenosis or occlusion of the hepatic vein anastomosis. We

report two cases of IVC stenosis and outflow block syndrome that developed following right hepatic LDLT with dominant inferior right hepatic vein (IRHV) anastomosis in which the outflow block syndrome was treated by insertion of a Gianturco expandable metallic stent.

## Patients and methods

### Patients

Between March 2002 and July 2004 we performed 44 adult-to-adult LDLT procedures (including two re-transplantations) at our hospital. The 39 patients (27 men, 12 women; 41 operations) who received a right liver graft were the subjects of the

present study. The patient's ages ranged from 20 to 68 yr old (median age = 53 yr). The indications for LDLT were hepatocellular carcinoma (n = 17), hepatitis C viral cirrhosis (n = 10), primary biliary cirrhosis (n = 4), hepatitis B viral cirrhosis (n = 2), cryptogenic cirrhosis (n = 2), fulminant hepatic failure (n = 2), chronic rejection (n = 2), primary sclerosing cholangitis (n = 1), and biliary atresia (n = 1).

#### Donors

The donors were 20 men and 21 women, and their ages ranged from 18 to 63 yr old (median age = 36 yr). According to their relation to the patient they consisted of 17 children, 15 spouses, five sibling, two parents, one nephew, and one grandchild. Right liver volume was preoperatively estimated by computed tomography (CT). Candidates whose right liver comprised more than 70% of their whole liver were rejected as prospective donors. An estimated graft-to-recipient weight ratio (GRWR) of 0.8 was the lower limit for right liver transplantation. Right liver grafts without the middle hepatic vein (MHV) were harvested; however, when the remnant left liver was estimated to account for more than 35% of the whole liver volume, harvesting an extended right liver graft was considered. We reconstructed all MHV tributaries that measured more than 5 mm in diameter with interpositional vascular grafts such as the recipient's inferior mesenteric vein, left portal vein, umbilical vein, or other veins.

#### Hepatic vein reconstructions procedure

The anastomoses between the graft vein and IVC were created in end-to-side fashion with 5-0 or 6-0 prolene stitches as described previously (3). The RHV anastomoses were performed by incising the IVC at the caudal corner of the RHV orifice and removing a piece of the anterior IVC wall to make the orifice oval-shaped. For the other anastomoses, a new hole was made by removing a small part of the IVC wall.

#### Results

##### Morbidity and mortality related to venous reconstruction

No patients died of complications of the venous reconstructions after LDLT. Four patients (9.7%) experienced complications of the venous reconstructions in the form of outflow block syndrome, and all were successfully treated with metallic

stents. Stenosis of the hepatic vein anastomosis developed as a complication in one of these patients, and a rare complication, totuous intrahepatic stenosis of the hepatic venous trunk, occurred in another patient (4). The remaining two cases of outflow block syndrome were suspected of being secondary to stenosis of the IVC with a pressure gradient greater than 10 mmHg, and they were described below.

#### Case 1

The patient was a 51-yr-old man with a history of liver dysfunction secondary to hepatitis C since 1990. LDLT of the right hepatic lobe of the patient's cousin was performed in July 2003, and the RHV and IRHV of the graft were anastomosed to the IVC of the recipient. The recipient's umbilical vein was used as an interpositional vascular graft between the major hepatic vein from segment VIII (V8) and the IVC. The diameter of the RHV, IRHV, and V8 was 15, 35, and 11 mm respectively. The GRWR was 1.15. Intraoperative Doppler ultrasound examinations did not reveal any evidence of stenosis or obstruction of hepatic venous, portal venous, or hepatic arterial blood flow. The patient's aspartate transaminase (AST), alanine aminotransferase (ALT), and total bilirubin (T-bil) levels had increased to 179, 215 IU/mL, and 14.9 mg/dL, respectively, on postoperative day (POD) 10, and daily measurements of ascitic fluid volume from a percutaneous drainage tube showed an increase to more than 1000 mL from POD 6 onwards. Doppler ultrasound examinations on POD 10 revealed flat waveforms and slightly low flow velocities in the RHV, IRHV, and V8 of 30, 18, and 9 cm/s, respectively, and a slightly low flow velocity of 15 cm/s in the right main portal vein. There were no areas of congestion on a CT scan. Hepatic venography and venacavography were performed on POD 10 because of clinical suspicion that hepatic venous obstruction had developed. The hepatic venograph showed no evidence of stenosis and no pressure gradients across any of the hepatic vein anastomoses. However, IVC stenosis was visualized by venacavography, and manometric venous pressure data from the infrahepatic IVC to the suprahepatic IVC obtained by drawing a catheter through the vessel revealed a pressure gradient of 11 mmHg across the IVC stenosis (Fig. 1A,B). The large IRHV anastomosis with no stenosis was located caudal to the site of stenosis (Fig. 1C). A 30 mm diameter, 5 cm long Gianturco Z stent (Cook, Bloomington, IN, USA) was placed in the

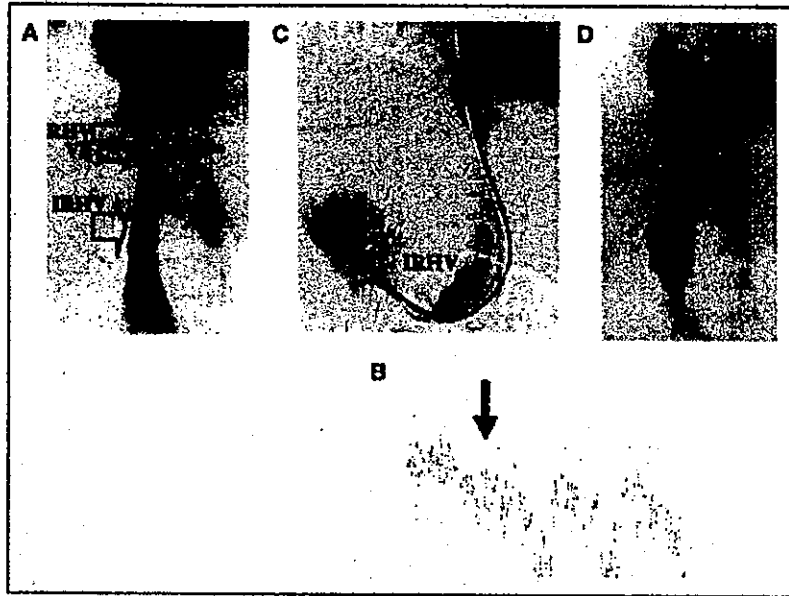


Fig. 1. (A) Venacavography in case 1, showing IVC stenosis associated with an 11 mmHg gradient (black arrow). The locations of the right hepatic vein (RHV), major hepatic vein from segment VIII (V8), and inferior right hepatic vein (IRHV) anastomoses are demonstrated. (B) Manometric venous pressure data showing a pressure gradient of 11 mmHg across the IVC stenosis (the black arrow indicates the same site as in A). (C) Hepatic venography of the IRHV revealing no evidence of stenosis or narrowing of the anastomosis. (D) After deployment of the IVC stent, there is ample IVC patency and only a 1 mmHg residual pressure gradient.

IVC, and the venous pressure gradient immediately decreased to 1 mmHg (Fig. 1D). The reason for choosing this stent is that the Z stent has wide interstices that minimize interference with hepatic vein outflow. Liver function also gradually improved after stent placement, and the daily ascitic fluid volume decreased to < 500 mL from POD 16 onwards (Fig. 2). Stent placement was successful, and the patency of the stent remains good. The patient was discharged on POD 43, and his course has been favorable over the 14 months since the operation.

Case 2

The patient was a 54-yr-old man with liver failure secondary to hepatitis C and was referred to our department for LDLT in April 2003. LDLT of the right hepatic lobe of the patient's son was performed, and the RHV of the graft was anastomosed to the IVC of the recipient in end-to-side fashion. The IRHV and the major hepatic veins from segment V (V5) and V8 were anastomosed to the side of the recipient's IVC. The recipient's left portal vein was used as an interpositional vascular

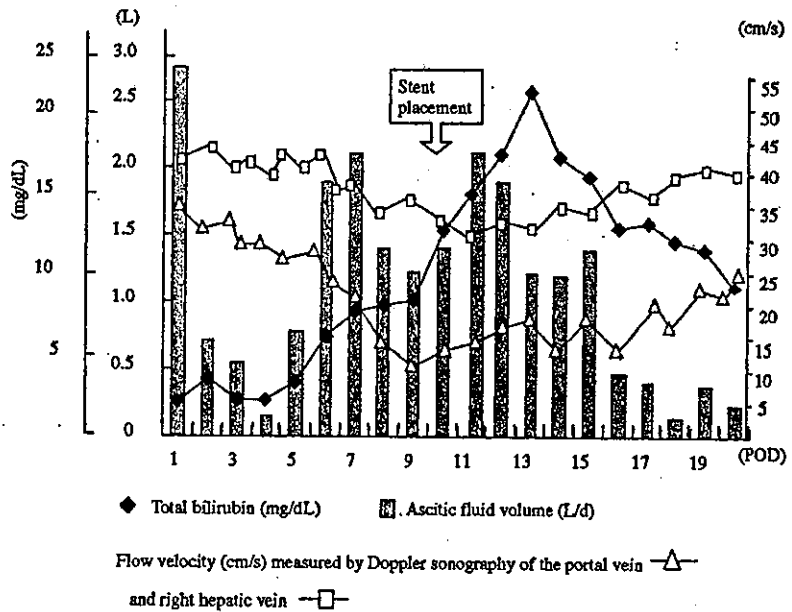


Fig. 2. Clinical course in case 1 before and after stenting. The closed squares represent serum total bilirubin (mg/dL). The shaped bars represent daily ascitic fluid (L). The open triangles and open squares represent flow velocity (cm/s) measured by Doppler ultrasound in the portal vein and the right hepatic vein respectively.

graft for the V5 anastomosis, and the recipient's inferior mesenteric vein was used as an interpositional graft for the V8 anastomosis. The diameter of the RHV, IRHV, V5, and V8 was 25, 10, 11, and 28 mm respectively. The GRWR was 1.12. Intraoperative Doppler ultrasound examinations did not reveal any evidence of stenosis or obstructions in the hepatic venous, portal venous, or hepatic arterial blood flow. The patient's AST, ALT, and T-bil levels had increased to 228, 196 IU/mL, and 36.5 mg/dL, respectively, on POD 15. Daily ascitic fluid volume from the percutaneous drainage tube increased from below 1000 mL to more than 2000 mL from POD 14 onwards. Ascitic fluid cultures were negative. Doppler ultrasound examinations revealed flat waveforms, flow velocity in the RHV, IRHV, V8, and V5 of 31, 28, 11, and 13 cm/s, respectively, and a flow velocity of 21 cm/s in the right main portal vein. No areas of congestion were visible on a CT scan. Steroid pulse therapy was started, because of strong suspicion of acute rejection, but there was no improvement in the liver dysfunction. A liver biopsy demonstrated centrilobular congestion, and hepatic venography was performed on POD 20 because of clinical suspicion that hepatic venous obstruction had developed. The hepatic venograph showed no evidence of stenosis and no pressure gradients across any of the hepatic vein anastomoses. However, IVC stenosis was visualized by venacavography, and manometric venous pressure data from the infrahepatic IVC to the suprahepatic IVC obtained by drawing a catheter through the vessel revealed a pressure gradient of 13 mmHg across

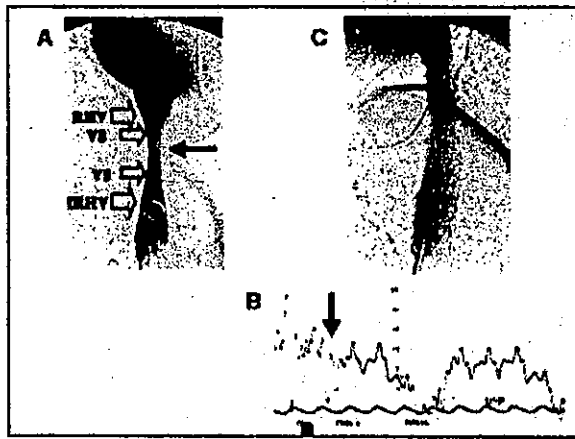


Fig. 3. (A) Venacavography in case 2, showing IVC stenosis associated with 13 mmHg gradient (black arrow). The locations of the anastomoses with RHV, V5, V8 and, IRHV are demonstrated. (B) Manometric venous pressure data showing a pressure gradient of 13 mmHg across the IVC stenosis (the black arrow indicates the same site as in A). (C) After deployment of the IVC stent, there is ample IVC patency and a residual 3 mmHg pressure gradient.

the IVC stenosis (Fig. 3A,B). A 35-mm diameter, 5-cm long Gianturco Z stent was placed in the IVC. The venous pressure gradient immediately decreased to 3 mmHg (Fig. 3C), and liver function gradually improved. The AST, ALT, and T-bil levels had decreased to 45, 64 IU/L, and 9.6 mg/dL, respectively, on POD 40. Daily ascitic fluid volume decreased to <1000 mL from POD 40 onwards, and continued to decrease to <500 mL from POD 46 onwards (Fig. 4). Unfortunately the

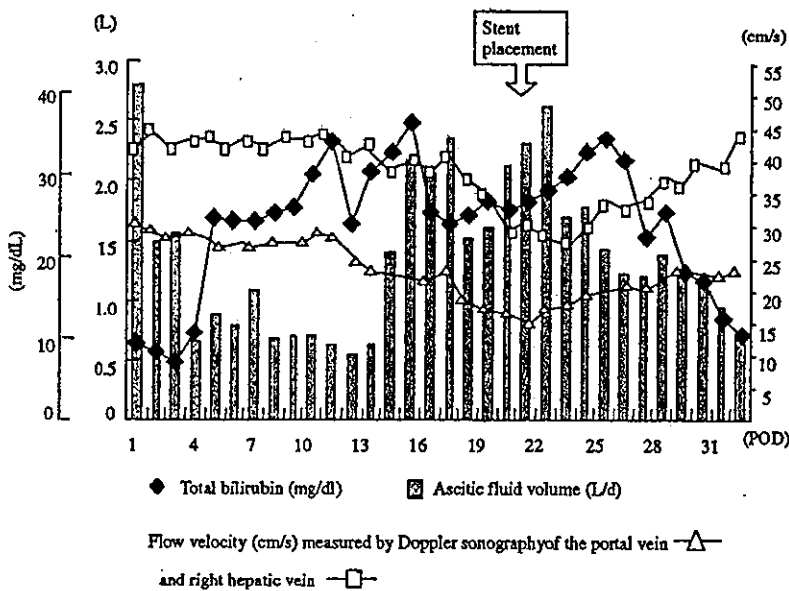


Fig. 4. Clinical course in case 2 before and after stenting. The closed squares represent serum total bilirubin (mg/dL). The shaped bars represent daily ascitic fluid volume (L). The open triangles and open squares mean represent flow velocity (cm/s) measured by Doppler ultrasound of the portal vein and the right hepatic vein respectively.