

- in living donor liver transplantation. *Transplantation* 2000 ; 69 : 258.
- 3) Kiuchi T, Kasahara M, Uryuhara K et al. Impact of graft-size mismatching on graft prognosis in liver transplantation from living donors. *Transplantation* 1999 ; 67 : 634
  - 4) Wicks C, Somasundaram S, Bjarnason I et al. Comparison of enteral feeding and total parenteral nutrition after liver transplantation. *Lancet* 1994 ; 344 : 837
  - 5) Hasse JM, Blue LS, Liepa GU et al. Early enteral nutrition support in patients undergoing liver transplantation. *JPEN* 1995 ; 19 : 437
  - 6) Mehta PL, Alaka KJ, Filo RS, Leapman SB, Migrom ML, Pescovitz MD. Nutrition support following liver transplantation : comparison of jejunal versus parenteral routes. *Clin Transplantation* 1995 ; 9 : 364
  - 7) Wiesner R, Edwards E, Freeman R et al. Model for end-stage liver disease (MELD) and allocation of donor livers. *Gastroenterology* 2003 ; 124 : 91
  - 8) Inomata Y, Tanaka K, Egawa H, Uemoto S, Ozaki N, Okajima H. The evolution of immunosuppression with FK506 in pediatric living related liver transplantation. *Transplantation* 1996 ; 61 : 247
  - 9) Tanabe M, Shimazu M, Wakabayashi G et al. Intraportal infusion therapy as a novel approach to adult ABO-incompatible liver transplantation. *Transplantation* 2002 ; 73 : 1959
  - 10) Lowell JA. Liver transplant recipients and enteral feeding. *Surgery* 1996 ; 119 : 357
  - 11) Pescovits MD, Mehta PL, Leapman SB, Milgrom ML, Jindal RM, Filo RS. Tube jejunostomy in liver transplant recipients. *Surgery* 1995 ; 117 : 642
  - 12) Rayes N, Seehofer D, Hansen S et al. Early enteral supply of lactobacillus and fiber versus selective bowel decontamination : a controlled trial in liver transplant recipients. *Transplantation* 2002 ; 74 : 123
  - 13) Ito T, Kiuchi T, Yamamoto H et al. Changes in portal venous pressure in the early phase after living donor liver transplantation : pathogenesis and clinical implications. *Transplantation* 2003 ; 75 : 1313

# Noninvasive Evaluation of Graft Steatosis in Living Donor Liver Transplantation

Minoru Iwasaki,<sup>1,6</sup> Yasutsugu Takada,<sup>1</sup> Michihiro Hayashi,<sup>2</sup> Sachiko Minamiguchi,<sup>3</sup> Hironori Haga,<sup>3</sup> Yoji Maetani,<sup>4</sup> Kazuhiro Fujii,<sup>1</sup> Tetsuya Kiuchi,<sup>5</sup> and Koichi Tanaka<sup>1</sup>

**Background.** Hepatic steatosis affects graft function as well as postoperative recovery of donors in living donor liver transplantation. Liver macrovesicular steatosis in living donors was assessed using quantitative X-ray computed tomography (CT) analysis and histological examination of intraoperative liver biopsy.

**Methods.** A total of 266 living donors with complete pretransplant CT data and intraoperative "time 0" biopsy were included in the study. Liver biopsy specimen obtained during donor operation was examined for macrovesicular steatosis and was classified as none (<30%); mild (30%–60%); or severe (>60%). Liver-to-spleen CT attenuation values ratio (L/S ratio) on noncontrast-CT was evaluated for its usefulness as an index of hepatic steatosis in comparison with other parameters including body mass index (BMI) and serum liver function tests (gamma-glutamyl transpeptidase, alanine aminotransferase, aspartate aminotransferase, cholinesterase, and total cholesterol) using receiver operating characteristic (ROC) analysis.

**Results.** Histological grade of macrovesicular steatosis was none in 198 patients (74.4%), mild in 50 (18.8%), moderate in 15 (5.7%), and severe in 3 (1.1%). The median L/S ratios for the respective histological grades were 1.20 (range: 1.00–1.46), 1.12 (0.83–1.37), 1.01 (0.74–1.21), and 0.90 (0.70–0.99) ( $P < 0.0001$ ). The ROC curve for L/S ratio was located closest to the upper left corner, and the area under the curve of L/S ratio was significantly larger than that of any other preoperative variables.

**Conclusion.** L/S ratio calculated from preoperative CT can be a useful tool to discriminate hepatic macrovesicular steatosis. Based on the present results, the optimal cut-off value for L/S ratio to exclude more than moderate steatosis would be 1.1.

**Keywords:** Liver-to-spleen CT attenuation values ratio, Receiver operating characteristic analysis, Macrovesicular steatosis, Living donor liver transplantation.

(*Transplantation* 2004;78: 1501–1505)

In cadaveric liver transplantation (CLT), fatty infiltration of the liver is common among the brain-dead donor population. Most centers will use cadaveric grafts with up to 30% macrosteatosis (1), and there are reports of successful CLT with extensive hepatic microsteatosis (2). However, the presence of significant macrosteatosis (>60%) has been associated with primary nonfunction (PNF) of the graft liver, a condition that is catastrophic to liver transplant recipients (3–5). In living donor liver transplantation (LDLT), graft steatosis is one of the risk factors for graft dysfunction, and it is thought that the presence of severe macrovesicular steatosis is an absolute contraindication for the use of that organ for

transplantation (6). In addition, hepatic steatosis affects postoperative recovery of the living donor (7). It is therefore very important to accurately diagnose the grade of donor hepatic steatosis in preoperative donor evaluation.

Several methods, including abdominal ultrasonography (US), computed tomography (CT), magnetic resonance imaging (MRI), body mass index (BMI) [kilograms/(height in meters)], waist/hip ratio, and liver function tests, have been used for evaluating hepatic steatosis (8–10). While these modalities are useful for investigating liver diseases, liver biopsy is still essential for diagnosis of hepatic steatosis and is the gold standard for the majority of patients (11, 12). Although liver needle biopsy is considered a relatively safe procedure, it has been reported that up to 5% of patients require hospitalization after the procedure and the incidence of significant bleeding is 1% with a fatal outcome in 1 of 10,000 patients (13, 14). To minimize such complications of needle biopsy, a noninvasive method would be required to evaluate hepatic steatosis in living donors before donor surgery.

Noncontrast-CT is currently one of the best radiological techniques for diagnosing of hepatic steatosis. The purpose of this study was to evaluate the accuracy of liver-to-spleen CT attenuation values ratio (L/S ratio) on noncontrast-CT in comparison with BMI or serum liver function tests for predicting hepatic steatosis.

## PATIENTS AND METHODS

### Donor Selection

Selection criteria for living donors in our institute were in principal based on age (20 to 60 years), ABO-blood type

This work was supported in part by a grant-in-aid for Scientific Research from the Ministry of Education, and by a Grant for Immunology, Allergy and Organ Transplantation from the Ministry of Health and Welfare, Japan.

<sup>1</sup> Department of Transplantation and Immunology, Kyoto University Graduate School of Medicine, Kyoto, Japan.

<sup>2</sup> Department of Gastroenterological Surgery, Osaka Medical College, Osaka, Japan.

<sup>3</sup> Laboratory of Anatomic Pathology, Kyoto University Hospital, Kyoto, Japan.

<sup>4</sup> Department of Radiology, Kyoto University Hospital, Kyoto, Japan.

<sup>5</sup> Department of Endocrine and Transplantation, Nagoya University Graduate School of Medicine, Nagoya, Japan.

<sup>6</sup> Address correspondence to: Minoru Iwasaki, M.D., Department of Transplantation and Immunology, Kyoto University Graduate School of Medicine, 54 Kawara-cho, Shogoin, Sakyo-ku, Kyoto, 606–8507, Japan. E-mail: iwasaki@kuhp.kyoto-u.ac.jp.

Received 17 March 2004. Accepted 7 June 2004.

Copyright © 2004 by Lippincott Williams & Wilkins

ISSN 0041-1337/04/7810-1501

DOI: 10.1097/01.TP.0000140499.23683.0D

compatibility, estimated graft size (greater than 1.0% of recipient body weight), and estimated residual liver volume (greater than 30% of the whole liver). Donor candidates with suspicion of hepatic steatosis were put on a diet and exercise program and later reevaluated.

### Donor and Recipient Profiles

A total of 266 living donors with complete pretransplant CT data and histological assessment of intraoperative "time 0" liver biopsy was included in this study. There were 137 male and 129 female donors. Donor age, body weight, and BMI were 19–66 (median 38) years, 39–108 (median 61.3) kg, and 17.4–34.3 (median 22.6) kg/m<sup>2</sup>, respectively. Selected graft types were left lateral segment in 122 donors, left lobe in 62, and right lobe in 82. Graft-to-recipient weight ratios (GRWR) for each graft types were 2.60 (range: 0.89–6.87), 0.96 (range: 0.61–1.56), and 1.14 (range: 0.66–3.18), respectively. Age and body weight of the recipients were 0.3–68.9 (median 11.1) years and 4.3–108 (median 28) kg. Primary disease of the recipients consisted of cholestatic disease in 138 patients, liver cirrhosis in 42, fulminant hepatic failure in 23, liver tumor in 23, metabolic liver disease in 20, retransplant in 12, and others in 8.

### Donor Biopsy and Histological Assessment

During donor surgery, after confirming that there was no abnormal finding in the peritoneal cavity on gross examination, the "time 0" wedge biopsy was taken from the liver. When graft livers were left lateral segment, left lobe, or right lobe, biopsy specimen was taken from segment III, segment IV, or segment V, respectively.

Histological grading of macrovesicular steatosis of "time 0" biopsies was performed by two independent pathologists (S.M., H.H). Macrovesicular steatosis was defined as hepatocytes containing one large vacuole of fat displacing the nucleus peripherally, and graded as none, mild (<30%), moderate (30%–60%), and severe (>60%) based on the percentage of hepatocytes containing cytoplasmic fat droplets, as previously reported (15).

### Calculation of L/S Ratio

All CT examinations were performed with a CT-W3000 (Hitachi Medical Systems, Tokyo, Japan). Scanning parameters were 120 kV, 200 mA, collimation of 7 mm, and table speed of 10 mL/s with reconstruction increments of 7 mm.

In noncontrast-CT, attenuation of normal liver is greater than the spleen. It has been reported that when this is reversed with a difference in liver-spleen attenuation of greater than –10 Hounsfield units, the liver is suspected to be steatotic (16). Hepatic and splenic attenuation values were measured on noncontrast-CT scans by using 16 circular region-of-interest (ROI) cursors in the liver and four in the spleen. In the liver, four ROIs were located in each of the right anterior, right posterior, left medial, and left lateral segments. This method was originally developed by us to raise the validity of the result by means of reducing errors in measurement and disappearance of overlap in each segment. All measurements were manually obtained in regions of uniform parenchymal attenuation, with care being taken to avoid vessels, artifacts, and other areas that might have spuriously in-

creased or decreased measurements. The four measurements in each segment of the liver and spleen were averaged.

In this study, the ratio of attenuation values in the liver to those in the spleen (L/S ratio) was evaluated for its efficacy as a marker for steatosis in the liver (Fig. 1). Calculation of L/S ratio was as follows:

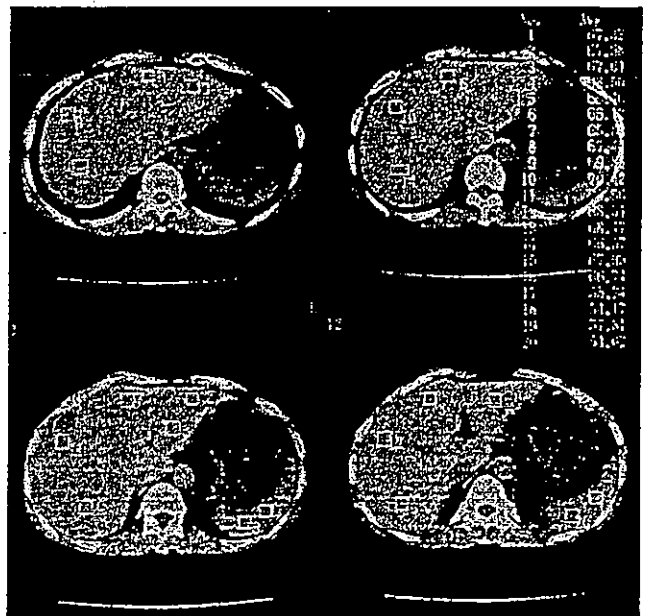L/S ratio

$$\frac{\text{Average attenuation value of liver (16 points)}}{\text{Average attenuation value of spleen (4 points)}}$$

Inter-segmental variation of L/S ratio was also analyzed.

### Statistical Analysis

Values are shown as median and range. For statistical comparison, chi-squared test or Fisher's exact probability test for categorical data, Kruskal-Wallis test or Mann-Whitney test for continuous data, Friedman test or Wilcoxon signed-ranks test for L/S ratio data of hepatic segments, and Cox-Mantel test for Kaplan-Meier survival curve were used. *P* values of less than 0.05 were regarded as statistically significant. To compare the preoperative diagnostic accuracy of L/S ratio, BMI, gamma-glutamyl transpeptidase (GGTP), alanine aminotransferase (ALT), aspartate aminotransferase (AST), cholinesterase (ChE), and total cholesterol (T-CHO) receiver operating characteristic (ROC) analysis was used with the "time 0" biopsy taken as the gold standard. The ROC curve can be drawn by plotting sensitivity (or "true-positive rate") on the



**FIGURE 1.** Calculation of liver-to-spleen CT attenuation values ratio. Hepatic and splenic attenuation values were measured on noncontrast-CT scans by using 16 circular region-of-interest (ROI) cursors in the liver and four in the spleen. In the liver, each four ROIs were measured at right anterior, right posterior, left medial, and left lateral segments. The size of one picture is 8×9 cm. Four sequential slices used for calculation of L/S ratio are demonstrated.

**TABLE 1.** Preoperative variables according to histological grades of macrovesicular steatosis

	Grade of macrovesicular steatosis (266)				P values
	None (198)	Mild (50)	Moderate (15)	Severe (3)	
Preoperative variables					
Donor age (yr)	37 (19–65) <sup>b</sup>	38 (21–61) <sup>d</sup>	48.5 (36–66) <sup>b,d</sup>	38 (30–47)	0.0127
BMI (kg/m <sup>2</sup> )	21.9 (17.4–34.3) <sup>a,b,c</sup>	24.3 (18.0–31.6) <sup>a,d</sup>	26.5 (19.4–33.8) <sup>b,d</sup>	25.6 (24.1–26.8) <sup>c</sup>	<0.0001
AST (IU/L)	17 (9–41) <sup>a,b</sup>	20 (11–87) <sup>a</sup>	23 (12–32) <sup>b</sup>	22 (11–25)	<0.0001
ALT (IU/L)	14 (4–123) <sup>a,b,c</sup>	25 (9–142) <sup>a</sup>	26 (15–55) <sup>b</sup>	33 (20–47) <sup>c</sup>	<0.0001
GGTP (IU/L)	16 (7–113) <sup>a,b,c</sup>	29 (10–90) <sup>a</sup>	27 (11–146) <sup>b,e</sup>	47 (30–87) <sup>a,e</sup>	<0.0001
ChE (IU/L)	296 (168–508) <sup>a,b</sup>	345 (237–482) <sup>a</sup>	362 (277–486) <sup>b</sup>	309 (265–517)	0.0006
T-CHO (mg/dL)	188 (120–314) <sup>a,b,c</sup>	202 (139–441) <sup>a</sup>	214 (166–251) <sup>b</sup>	237 (222–249) <sup>c</sup>	0.0013
L/S ratio	1.20 (1.00–1.46) <sup>a,b,c</sup>	1.12 (0.83–1.37) <sup>a,d,f</sup>	1.01 (0.74–1.21) <sup>b,d</sup>	0.90 (0.70–0.99) <sup>a,f</sup>	<0.0001

BMI, body mass index; AST, aspartate aminotransferase; ALT, alanine aminotransferase; ChE, cholinesterase; GGTP, gamma-glutamyl transpeptidase; T-CHO, total cholesterol; L/S ratio, liver-to-spleen CT attenuation values ratio.

<sup>a</sup>P < 0.05 none vs. mild; <sup>b</sup>P < 0.05 none vs. moderate; <sup>c</sup>P < 0.05 none vs. severe; <sup>d</sup>P < 0.05 mild vs. moderate; <sup>e</sup>P < 0.05 moderate vs. severe; <sup>f</sup>P < 0.01 mild vs. severe.

vertical (Y) axis and specificity (or “false-positive rate”) on the horizontal (X) axis with a given cut-off point and changing the cut-off points from more stringent to less stringent. Because the accuracy of a test depends on its sensitivity and specificity, ROC curves of tests with higher discriminating ability are closer to the upper left corner than curves of those with lower ability (17, 18). Area under the ROC curve (AUC) can be calculated using the trapezoidal method (17). AUC represents the probability of correctly ranking a randomly chosen pair of persons with and without the disorder. For comparison of two AUC's, the nonparametric method developed by Hanley and McNeil (17, 19) was employed.

## RESULTS

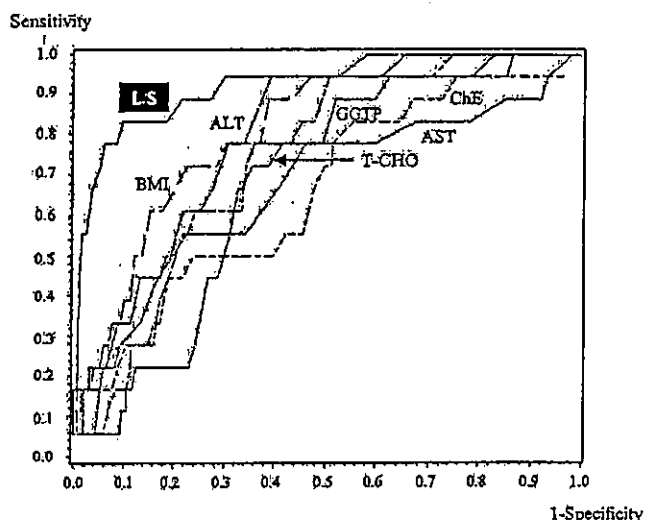
### Graft Steatosis and L/S Ratio

The grade of macrovesicular steatosis as evaluated in the “time 0” biopsy specimens was none in 198 livers (74.4%), mild in 50 (18.8%), moderate in 15 (5.7%), and severe in 3 (1.1%) (Table 1). The median L/S ratio for livers of each histological grade was 1.20 (range: 1.00–1.46), 1.12 (0.83–1.37), 1.01 (0.74–1.21), and 0.90 (0.70–1.21), respectively. The differences among the four groups were statistically significant (Table 1). There were also significant correlations between steatosis grade in “time 0” biopsy specimens and increases in BMI or other blood chemistry results.

An intersegmental variation of L/S ratio was analyzed in the four segments (left lateral, left medial, right anterior, and right posterior segments) in patients with more than moderate grade steatosis (n=18). The L/S ratios in the left lateral, left medial, right anterior, and right posterior were 0.985, 0.985, 0.89, and 0.945, respectively. Although no statistically significant differences were observed among the four segments, L/S ratio tended to be higher in the left lateral segment than in the right anterior or posterior segments.

### ROC Analysis

To compare the abilities of L/S ratio and other preoperative variables to discriminate between none to mild and moderate to severe steatosis, the ROC curves of these tests were determined (Fig. 2). The ROC curve of the L/S ratio was



**FIGURE 2.** ROC curves were determined for L/S ratio, BMI, GGTP, ALT, AST, ChE, and T-CHO, all of which were measured preoperatively in 266 cases of LDLT.

located closer to the upper left corner than that of any other preoperative variables (BMI, GGTP, ALT, AST, ChE, and T-CHO). For statistical comparison, Z statistics for the difference in areas under the ROC curves between L/S ratio and each of the other conventional variables are shown in Table 2. The AUC of L/S ratio was larger than that of any other variables, and the differences were significant, except for comparisons with BMI and ALT (Table 2).

### Graft Outcome

Postoperative peak AST and ALT levels in both donors and recipients were higher in patients with moderate to severe macrovesicular steatosis. AST levels in donors with none to mild steatosis and in those with moderate to severe steatosis were 300 IU/L and 362 IU/L ( $P < 0.05$ ), respectively. Similarly, ALT levels in the respective donors were 270 IU/L and 388 IU/L ( $P < 0.05$ ). Moreover, the respective levels in recipients

**TABLE 2.** Statistical comparison of areas under the ROC curves between L/S ratio and preoperative variables

	Z statistics vs. L/S ratio	(P value)
BMI	1.61206	0.10695
GGTP	3.00589	0.00265
ALT	1.53605	0.12453
AST	2.74714	0.00601
CHE	3.37740	0.00073
T-CHO	2.94694	0.00321

were 295 IU/L and 417 IU/L and 317 IU/L and 418 IU/L, with no statistical differences being observed. However, the 5-year graft survival rates for grafts with none to mild steatosis and those with moderate to severe steatosis were 74.1% vs. 71.8%, but this difference was not significant. PNF was not seen in any of this series.

### DISCUSSION

New insights into the mechanisms of failure of fatty livers should result in new prophylactic and therapeutic approaches (20). Livers with significant steatosis may increase the severity of ischemia-reperfusion injury and the incidence of graft PNF. Zamboni et al. (21) reported that macrovesicular steatosis involving 25% or more of the hepatocytes in the donor liver was significantly associated with shorter post-transplant survival and with a higher number of delayed graft failures. Worldwide, severely steatotic grafts (>60%) are routinely discarded for CLT. On the other hand, use of graft liver with microsteatosis did not influence either short- or medium-term survival (2, 22). In the case of LDLT, due to the limited selection of donors, grafts with moderate to severe grade steatosis have been sometimes used with fully informed consent. Probably due to the minimized cold ischemic time in part, PNF has not been observed in our series (cold ischemic time: 2 hr in this series). However, the risk of using grafts with severe steatosis has also been clearly identified in LDLT (7).

Although liver needle biopsy may be required for definitive preoperative diagnosis of hepatic steatosis, it is not a universally safe procedure and should not be routinely applied to all living donor candidates. To minimize the risks of liver needle biopsy, noninvasive diagnostic methods using clinical, imaging, and/or biochemical parameters have been investigated (23, 24). In a recent study on living liver donors, Mary et al. (8) reported that BMI was a reliable predictor of hepatic steatosis with a positive correlation between increasing BMI and steatosis grade on biopsy. It was also suggested that liver biopsy could be avoided in subjects with normal BMI, but that living donors with high BMI should undergo liver biopsy because biochemical and imaging data are not reliable enough to accurately diagnose the degree of steatosis (8).

In the present study, ROC analysis was used to compare the diagnostic ability of L/S ratio to predict the grade of hepatic steatosis with that of other preoperative variables. Because the ROC curve of L/S ratio is closer to the upper left corner of the graph than that of other variables, the sensitivity and specificity of L/S ratio can be considered higher when compared with these variables (BMI, GGTP, ALT, AST, CHE,

and T-CHO). The ROC curve is a graph of sensitivity versus specificity, both of which are independent of disorder prevalence, and analysis does not depend on the prevalence of disorder in the actual population to which the preoperative variable may be applied (17). Moreover, statistical analysis of the differences in AUCs reveals that L/S ratio could predict >30% hepatic steatosis more accurately than any other variable, although the differences were not significant in comparison with BMI or ALT.

If a liver with less than 30% steatosis is thought to be appropriate for a living donor, the mean  $\pm$  SD of the L/S ratio in donors with none to mild steatosis was  $1.184 \pm 0.091$ . With regard to discriminating between none to mild and moderate to severe steatosis by L/S ratio, when the cut-off level was set at 1.1, the sensitivity and specificity were 0.833 and 0.815, respectively (Table 3), and the ROC curve closely approached the upper left corner. With regard to balance between sensitivity and specificity, the optimal level of L/S ratio to predict >30% hepatic steatosis would be 1.1.

From the results of intersegmental variation of L/S ratio, it is likely that fat deposition is heterogeneous throughout the liver. Because a single biopsy specimen shows the grade of hepatic steatosis only at the area where it was taken, multiple needle biopsies would be necessary to accurately evaluate steatotic changes in the whole liver. On the other hand, evaluation of hepatic steatosis using CT attenuation values enables the assessment of fatty changes in each part of the liver. To simultaneously express a representative value of fatty changes of the whole liver as well as to estimate the risks of both the graft and the remnant liver, the averaged value was employed to determine L/S ratio in the present study.

The present study suggests that L/S ratio on noncontrast-CT can be clinically used as a noninvasive method to correctly evaluate hepatic steatosis. This method is actually feasible because CT examination has been routinely done in donor preoperative evaluation for the assessment of liver anatomy and graft size and the calculation of L/S ratio is not time consuming. By employing this modality, preoperative liver needle biopsy could be omitted for most donors at our institution. However, when hepatic steatosis of more than moderate grade indicated by the L/S ratio does not show any significant improvement regardless of adequate diet and exercise treatment, or is accompanied by other complications including diabetes mellitus and/or hyperlipidemia, liver biopsy is performed to exclude disorders such as nonalcoholic steatohepatitis.

**TABLE 3.** Assessment for cut-off point of L/S ratio more than 30% steatosis in time zero biopsy according to ROC analysis

Cut-off point of L/S ratio ( $\geq 30\%$ )	Sensitivity	Specificity	Diagnostic accuracy
1.2	0.944	0.448	0.481
1.1	0.833	0.815	0.816
1.0	0.556	0.984	0.955
0.9	0.222	0.992	0.940
0.8	0.111	1.000	0.940

### ACKNOWLEDGMENTS

We are indebted to Toshimitsu Kobayashi and Shinichi Yamaguchi, Division of PostMarketing Development Research Center, Fujisawa Pharmaceutical Co., Ltd. for their highly appreciated contributions in performing the statistical analysis.

### REFERENCES

1. Urena M, Gonzalez EM, Romero CJ, et al. An approach to the rational use of steatotic donor livers in liver transplantation. *Hepato-Gastroenterol* 1999; 46: 1164.
2. Fishbein TM, Fiel MI, Emre S, et al. Use of livers with microvesicular fat expands the donor pool. *Transplantation* 1997; 64: 247.
3. Imber CJ, St Peter SD, Handa A, et al. Hepatic steatosis and its relationship to transplantation. *Liver Transpl* 2002; 8: 415.
4. D'Alessandro AM, Kalayoglu M, Sollinger HW, et al. The predictive value of donor Liver biopsies for the development of primary nonfunction after orthotopic liver transplantation. *Transplantation* 1991; 51: 157.
5. Todo S, Demetris AJ, Makowka L, et al. Primary nonfunction of hepatic allografts with preexisting fatty infiltration. *Transplantation* 1989; 47: 903.
6. Hayashi M, Fujii K, Kiuchi T, et al. Effects of fatty infiltration of the graft on the outcome of living-related liver transplantation. *Transplant Proc* 1999; 31: 403.
7. Ito T, Kiuchi T, Egawa H, et al. Surgery-related morbidity in living donors of right lobe liver graft: lessons from the first 200 cases. *Transplantation* 2003; 76: 158.
8. Rinella ME, Alonso E, Rao S, et al. Body mass index as a predictor of hepatic steatosis in living liver donors. *Liver Transpl* 2001; 7: 409.
9. Angulo P, Keach JC, Batts KP, et al. Independent predictors of liver fibrosis in patients with nonalcoholic steatohepatitis. *Hepatology* 1999; 30: 1356.
10. Kral JG, Schaffner F, Pierson RN, et al. Body fat topography as an independent predictor of fatty liver. *Metabolism* 1993; 42: 548.
11. Chen YS, Cheng YF, Vanessa H, et al. Evaluation of living liver donors. *Transplantation* 2003; 75: 16.
12. Stotland BR, Lichtenstein GR. Liver biopsy complications and routine ultrasound. *Am J Gastroenterol* 1996; 91: 1295.
13. Van Ness MM, Diehl AM. Is liver biopsy useful in the evaluation of patients with chronically elevated enzymes? *Ann Intern Med* 1989; 111: 473.
14. Goddard CJ, Warenes TW. Raised liver enzymes in asymptomatic patients: Investigation and outcome. *Dig Dis* 1992; 10: 218.
15. Ploeg RJ, D'Alessandro AM, Knechtle SJ, et al. Risk factors for primary dysfunction after liver transplantation-A multivariate analysis. *Transplantation* 1993; 55: 807.
16. Siegelman I, Rosen MA. Imaging of hepatic steatosis. *Semin Liv Dis* 2001; 21: 71.
17. Imber CJ, St Peter SD, Handa A, et al. Hepatic steatosis and its relationship to transplantation. *Liver Transpl* 2002; 8: 415.
18. Metz CE. Basic principles of ROC analysis. *Semin Nucl Med* 1978; 8: 283.
19. Hanley JA, McNeil BJ. A method of comparing the areas under receiver operating curves derived from the same case. *Radiology* 1983; 148: 839.
20. Selzner M, Clavien PA. Fatty liver in liver transplantation and surgery. *Semin Liv Dis* 2001; 21: 105.
21. Zamboni F, Franchello A, David E, et al. Effect of macrovesicular steatosis and other donor and recipient characteristics on the outcome of liver transplantation. *Clin Transplant* 2001; 15: 53.
22. Urena MAG, Ruiz-Delgado FC, Gonzalez EM, et al. Assessing risk of the use livers with macro and microsteatosis in a liver transplant program. *Transplant Proc* 1998; 30: 3288.
23. Ounwater E, Blasbalg R, Siegelman E, et al. Detection of lipid in abdominal tissue with opposed-phase gradient-echo images at 1.5T: technical and diagnostic importance. *Radiographics* 1998; 18: 1465.
24. Ricci C, Longo R, Gioulis E, et al. Noninvasive in vivo quantitative assessment of fat content in human liver. *J Hepatol* 1997; 27: 108.

# Functional Portal Flow Competition After Auxiliary Partial Orthotopic Living Donor Liver Transplantation in Noncirrhotic Metabolic Liver Disease

By Mureo Kasahara, Yasutsugu Takada, Koichi Kozaki, Kenji Uryuhara, Yasuhiro Ogura, Kohei Ogawa, Yasuhiro Fujimoto, and Koichi Tanaka  
Kyoto, Japan

Auxiliary partial orthotopic liver transplantation (APOLT) was introduced initially as a tentative or permanent support for patients with potentially reversible fulminant hepatic failure and has extended its indication to congenital metabolic disorder of the liver that has otherwise normal functional integrity. Postoperative management of APOLT is complicated because of functional portal flow competition between the native and graft liver. The native portal vein diversion to the graft is sometimes indicated to prevent functional competition; however, it is still an open question whether this technique can be theoretically indicated for APOLT patients. The authors report a patient with ornithine transcarbamylase deficiency who received APOLT from a living donor without native portal vein diversion. Because of functional

portal vein competition between the native and graft liver, the patient had to have portal vein diversion, portal vein embolization, and finally native hepatectomy to induce the graft regeneration after APOLT. After the experience of the current case, primary portal vein diversion for APOLT with noncirrhotic metabolic liver disease patients to prevent functional portal flow competition is recommended.

*J Pediatr Surg* 39:1138-1141. © 2004 Elsevier Inc. All rights reserved.

**INDEX WORDS:** Auxiliary liver transplantation, living donor liver transplantation, noncirrhotic metabolic liver disease, ornithine transcarbamylase deficiency.

Liver transplantation can offer a complete cure for genetic metabolic errors in the liver.<sup>1</sup> The main purpose of liver transplantation for noncirrhotic congenital metabolic disorders is to supply missing enzymes by replacing the native liver, which is a normally functioning entity. Auxiliary partial orthotopic liver transplantation (APOLT) has been introduced as a treatment for noncirrhotic congenital metabolic disorder of the liver.<sup>2-4</sup> The claimed advantage of APOLT for noncirrhotic congenital metabolic disorder of the liver is that APOLT compensates for deficiencies in enzymes without complete removal of the native liver, which may help rescue the patient in case of graft failure and may make future gene treatment possible. One of the controversies surrounding APOLT is functional competition between the native and graft liver. Severe acute rejection induces rapid graft shrinking because of a portal flow steal phenomenon affecting to the remnant native liver.<sup>5,6</sup>

Ornithine transcarbamylase deficiency (OTCD) is an X-chromosome-linked genetic disorder, which results in fulminant hyperammonemia with a poor prognosis.<sup>4</sup> The usual medical treatment consists of protein restriction combined with the administration of sodium benzoate.<sup>7</sup> This treatment, however, is not always sufficient to avoid life-threatening fulminant hyperammonemia and induces serious neurologic sequelae in which APOLT is sometimes indicated.

We reported on a patient with OTCD who did not receive primary ligation of the native portal branch at the time of APOLT.<sup>4</sup> After a severe rejection episode, the graft became smaller, and the native liver underwent compensatory hypertrophy. We surgically ligated the native portal branch, then the graft recovered its volume and function. However, it is still controversial as to whether this technique can be indicated to APOLT patients. We report here a complicated case of OTCD, who had several episodes of functional portal flow competition between the native and graft liver after APOLT from a living donor. The management of portal flow competition, which includes native portal vein diversion, portal vein embolization, and native hepatectomy are also discussed.

## CASE REPORT

The patient was a girl aged 5 years and 8 months. Vomiting and somnolence developed at the age of 22 months, and OTCD was diagnosed on the basis of low enzyme activity by liver biopsy. Despite

*From the Department of Transplant Surgery, Kyoto University Hospital, Kyoto, Japan.*

*Supported in part by grants from the Scientific Research Fund of the Ministry of Education and by a Research Grant for Organ Transplant from the Ministry of Health and Welfare, Japan.*

*Address reprint requests to Mureo Kasahara, MD, Department of Transplant Surgery, Kyoto University Hospital, 54, Kawara-cho, Shogoin, Sakyo-ku, Kyoto 606-8507, Japan.*

© 2004 Elsevier Inc. All rights reserved.

0022-3468/04/3907-0032\$30.00/0

doi:10.1016/j.jpedsurg.2004.03.079

treatment with protein restriction and medication, the patient went into a hyperammonemic coma more than 30 times during 4 years of follow-up and was referred for living donor liver transplantation. APOLT was performed with a left lateral segment from the father in July 1996.<sup>4</sup> The left lateral segment of the native liver was removed followed by auxiliary orthotopic implantation of the left lateral segment.<sup>8</sup> The actual graft weight was 255 g, and the graft-to-recipient weight ratio (GRWR) was 1.34%. The left hepatic vein of the graft was anastomosed in an end-to-end fashion to the recipient's left hepatic vein. The portal venous flow to the graft was shared with the recipient's remnant right lobe, meaning that the left portal vein of the graft was anastomosed with the native left portal vein in an end-to-end fashion. The right portal vein was preserved. Hepatic artery reconstruction was performed end-to-end with the recipient's left hepatic artery using a microvascular technique. Biliary reconstruction was achieved by Roux-en-Y hepatico-jejunostomy. The patient was discharged from the hospital without complication. Postoperative computed tomography (CT) volumetry found the native liver to be 551 mL and the graft liver 255 mL (Native to Graft liver ratio, 2.16). Doppler echography showed the native and graft portal venous flows to 194 and 154 mL/min, respectively.

One year after transplantation, the patient had a severe rejection. Doppler echography showed hepatofugal flow of the graft portal vein and the entire portal blood flow going into the native liver. CT scan showed the decreasing volume of the graft (160 mL) and increasing volume of the native liver (600 mL, native to graft liver ratio, 3.75). A technetium 99 m-GSA scintigraphy study showed tracer uptake in the graft versus native liver to be 49.5: 50.5%. The patient had several episodes of relapsed fulminant hyperammonemia. The rejection episode was treated successfully with steroid bolus injections, and the serum ammonia level was normalized.

However, the native liver volume was not recovered, because the graft liver already lost much of the portal blood flow to the native side.<sup>8</sup> To prevent functional portal flow competition and induce graft regeneration, portal vein diversion (PVD) from the native portal blood flow to the graft was indicated. Before surgery, the indication of initial native hepatectomy was also discussed; however, CT volumetry of the graft liver showed "small-for-size" (GRWR 0.75%), defined as GRWR less than 0.8%,<sup>9</sup> which made us discard the possibility.

The right portal vein was isolated and transected in an operation performed in August 1997. Results of a <sup>99m</sup>Tc-GSA scintigraphy study showed the uptake in graft versus native liver to be improved to 72.6: 27.4%. The graft volume and function recovered satisfactorily, and the serum ammonia level was restored to its normal level.

Four years after portal vein diversion, the patient had an episode of fulminant hyperammonemia again. Doppler echography showed recanalization of the native portal flow through cavernous transformation of connective tissue around the right hepatic hilum. Doppler echography showed the native and graft portal venous flow to be 198 and 176 mL/min (Fig 1A). A CT volumetry study showed the graft liver to be shrunk to 200 mL and the native liver to have grown to 776 mL (native to graft liver ratio, 3.88). A <sup>99m</sup>Tc-GSA scintigraphy study revealed the uptake in graft versus native liver to be 32.0: 68.0%. Native hepatectomy was planned; however, the estimated graft volume was 200 mL, which was 0.6% in GRWR. The GRWR showed "small-for-size" to sustain the recipient's metabolic demand.<sup>9</sup>

To induce the graft regeneration, percutaneous transhepatic portal vein embolization (PTPE) to the right native lobe was indicated in October 2001. Three weeks after PTPE, the graft liver volume increased from 200 mL to 270 mL, which showed 0.8% in GRWR, and the native right lobe decreased from 776 mL to 726 mL (native to graft liver ratio, 2.69). A <sup>99m</sup>Tc-GSA scintigraphy study showed the uptake in graft versus native liver to be improved to 36.4: 63.5%.

To preserve a sufficient liver volume and retain the possibility of

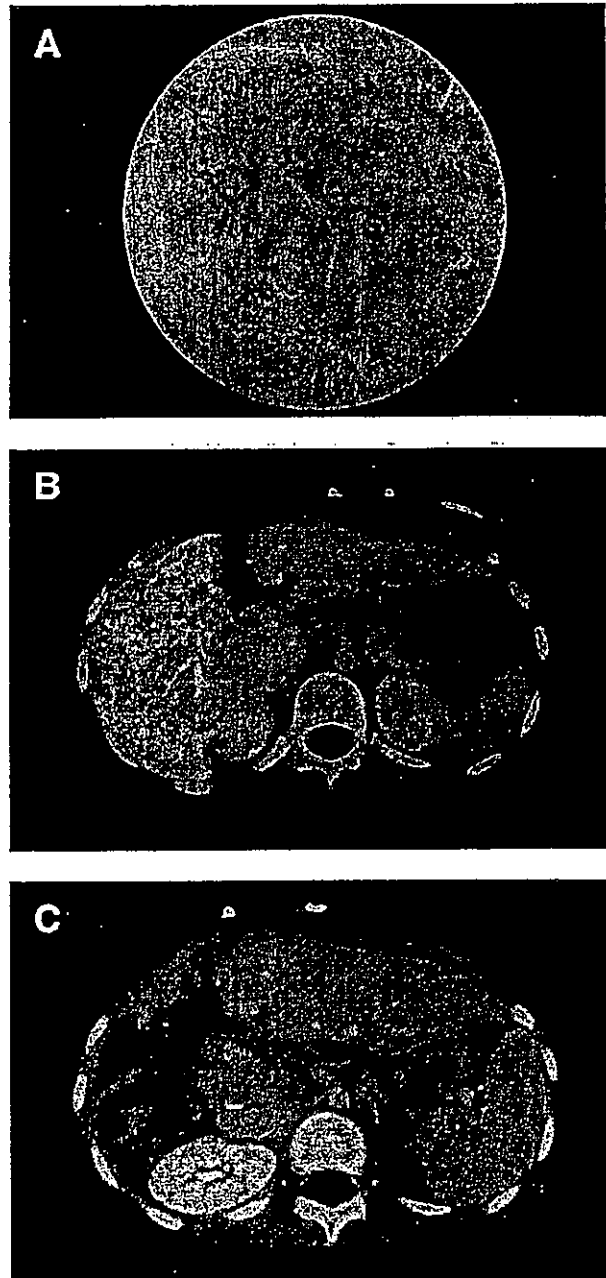


Fig 1. (A) Portal phase of angiology shows cavernous transformation of the native right portal vein after portal vein diversion. (B) After PTPE for native right portal vein. Right portal vein was occluded by Lipiodol. (C) CT after native right hepatectomy. The volumetric analysis showed 416 mL in the graft and 106 mL in the native caudate lobe.

future gene therapy, we performed a right hepatectomy of the native liver preserving the native caudate lobe in December 2001. The estimated GRWR of the native caudate lobe and graft was 1.1%, which might be a sufficient liver volume for the patient. Actual weight of the resected native right lobe was 600 g. Histologic findings of the native liver showed mild portal fibrosis and occlusion owing to PTPE. One month after native right hepatectomy, the estimated CT volumetry showed 416 mL in the graft and 106 mL in the native caudate lobe



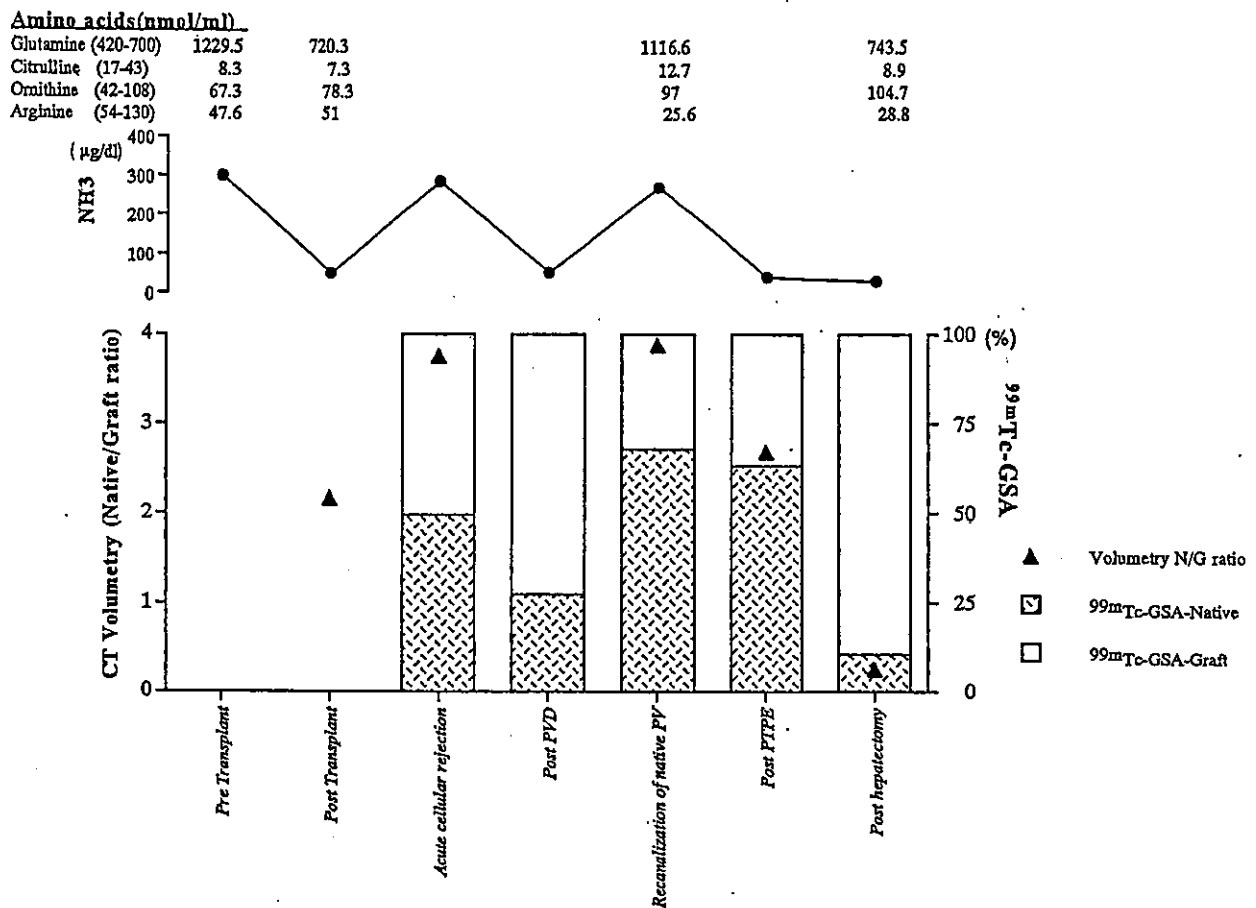


Fig 2. Changes of the native and graft liver in CT volumetry and  $^{99m}\text{Tc}$ -GSA scintigraphy evaluation.

(native to graft liver ratio, 0.25; Fig 1B). A  $^{99m}\text{Tc}$ -GSA scintigraphy study showed the uptake in the graft versus native caudate lobe to be 89.5:10.5%. During an 18-month follow-up, the patient has been doing well without an episode of relapsed hyperammonemia and protein restriction or additional medication for the metabolic disorder.

#### DISCUSSION

We have performed 6 cases of APOLT for noncirrhotic metabolic liver disease (citrullinemia in 3, OTCD in 2, Crigler-Najjar syndrome type I in 1) in our 940 LDLT series. One of the problems of APOLT is functional portal flow competition between the graft and native liver. To obtain a sufficient demand for metabolic correction of the original disease, an adequate functional graft volume is necessary. Adequate volume of the functional hepatocyte is different for each liver disease and type of native hepatectomy to correct the original liver disease, because there are several variations of enzyme activity in the native liver segments.<sup>4</sup> We used CT volumetry and  $^{99m}\text{Tc}$ -GSA scintigraphy in APOLT cases to evaluate the anatomic and functional volume in the graft and native liver. Figure 2 shows the changes in CT volumetry and  $^{99m}\text{Tc}$ -GSA scintigraphy after APOLT.

The anatomic volume of the graft might not always be relevant to functional volume. Subsequent CT volumetry and  $^{99m}\text{Tc}$ -GSA scintigraphy are useful to evaluate anatomic and functional liver volume after APOLT.

After APOLT, the graft showed severe rejection and shrank quickly. The remnant native liver had grown enough to take over the function of the graft in this case. Even after successful treatment of the rejection, the graft liver lost the portal blood flow to the native liver. The graft liver had difficulty increasing its volume again because it already lost much of the portal blood flow to the native side.<sup>8</sup>

After native PVD, the graft volume increased properly and was shown to have acceptable metabolic function. In our previous study, the resistance of portal venous inflow in the graft liver was higher than the native liver after APOLT,<sup>10</sup> and the dominant portal venous flow to the native liver could be observed readily in the event of severe rejection. After the experience of the current case, we changed the standard procedure for APOLT of noncirrhotic metabolic liver disease, meaning we indicated that the native PVD in all subsequent cases and the graft

liver received the entire portal venous flow. The native liver was supplied by arterial blood flow.

There will be a concern about dysfunction of the remnant native liver after PVD, which may negate the support of a patient's life and the possibility of future gene therapy. However, it was reported that occluded portal flow induces hepatocyte apoptosis rather than necrosis in the embolized lobe without changing the functional efficiency of hepatocyte.<sup>11,12</sup> The remnant native liver may sustain the recipient's life if the native portal vein is transected.

PVD is an effective technique to induce graft regeneration and to avoid functional portal flow competition. An unexpected event in this case was the recanalization of the native portal flow through cavernous transforma-

tion after PVD. Subsequent Doppler echography is important to evaluate the native portal flow after PVD. We performed PTPE for the native liver to obtain sufficient regeneration of the graft liver, because the GRWR was not sufficient to sustain the patient's metabolic demand after native right hepatectomy. PTPE also effectively increased both the volume and functional capacity of the transplanted graft liver in this case.

PVD for APOLT for noncirrhotic metabolic liver disease patients effectively prevents functional portal flow competition. A postoperative CT scan and <sup>99m</sup>Tc-GSA scintigraphy were useful to evaluate functional and anatomic liver volume after APOLT. Evaluation of the functional volume of the graft is important because it is often dissociated from anatomic volume.

#### REFERENCES

1. Todo S, Starzl TE, Tzakis A, et al: Orthotopic liver transplantation for urea cycle enzyme deficiency. *Hepatology* 15:419-422, 1992
2. Terpstra OT: Auxiliary liver grafting: A new concept, in liver transplantation. *Lancet* 342:758, 1993
3. Whittington PF, Edmond JC, Heffron T, et al: Orthotopic auxiliary liver transplantation for Crigler-Najjar syndrome type 1. *Lancet* 342:779-780, 1993
4. Kasahara M, Kiuchi T, Uryuhara K, et al: Treatment of ornithine transcarbamylase deficiency in girls by auxiliary liver transplantation: Conceptual changes in a living-donor program. *J Pediatr Surg* 33:1753-1756, 1998
5. Komatsu H, Inui A, Fujisawa T, et al: Severe late acute allograft rejection in a child after living-related auxiliary partial orthotopic liver transplantation for ornithine transcarbamylase deficiency. *Clin Transplant* 13:300-304, 1999
6. Kaibori M, Egawa H, Inomata Y, et al: Selected portal blood flow diversion in auxiliary partial orthotopic liver transplantation to induce regeneration of the graft. *Transplantation* 66:935-937, 1998
7. Brusilow SW, Denney M, Waber LJ, et al: Treatment of episodic hyperammonemia in children with inborn errors of urea synthesis. *N Engl J Med* 310:1630-1634, 1984
8. Inomata Y, Kiuchi T, Kim ID, et al: Auxiliary partial orthotopic living donor liver transplantation as an aid for small-for-size grafts in larger recipients. *Transplantation* 67:1314-1319, 1999
9. Kiuchi T, Kasahara M, Uryuhara K, et al: Impact of graft-size mismatching on graft prognosis in liver transplantation from living donors. *Transplantation* 67:321-327, 1999
10. Yabe S, Egawa H, Inomata Y, et al: Auxiliary partial orthotopic liver transplantation from living donors: Significance of portal blood flow. *Transplantation* 66:484-488, 1998
11. Harada H, Imamura H, Minagawa S, et al: Fate of human liver after hemihepatic portal vein embolization: Cell kinetic and morphometric study. *Hepatology* 26:1162-1170, 1997
12. Shimada R, Imamura H, Nakamura A, et al: Changes in blood flow and function of the liver after right portal vein embolization. *Arch Surg* 137:1384-1388, 2002

# End-to-Side Portocaval Shunting for a Small-for-Size Graft in Living Donor Liver Transplantation

Yasutsugu Takada,<sup>1</sup> Mikiko Ueda,<sup>1</sup> Yukika Ishikawa,<sup>2</sup> Yasuhiro Fujimoto,<sup>1</sup> Hideaki Miyauchi,<sup>3</sup> Yasuhiro Ogura,<sup>1</sup> Takenori Ochiai,<sup>2</sup> and Koichi Tanaka<sup>1</sup>

In the development of adult-to-adult living donor liver transplantation (LDLT), the small-for-size graft has been associated with poor clinical outcome. Persistent portal hypertension or portal venous overperfusion are considered to be causative factors, and partial diversion of portal flow to systemic circulation may be effective for avoiding injuries that occur in the small-for-size (SFS) graft. Recently, we constructed an end-to-side portocaval shunting using 1 of the portal branches and anastomosed the other branch with the portal vein of the graft in 2 cases of LDLT recipients transplanted with a SFS graft. With the suppression of portal hypertension, as well as sufficient portal flow to the graft, the recipients recovered successfully with favorable graft function. This new and simple technique may be able to be used as a feasible and effective method to attenuate the SFS syndrome. (*Liver Transpl* 2004;10:807-810.)

Living donor liver transplantation (LDLT) was initiated in pediatric patients to decrease mortality among patients on the cadaveric donor liver waiting list.<sup>1</sup> With excellent patient and graft survival, encouraging results in pediatric LDLT have led to the development of an adult-to-adult LDLT program. As the number of adult LDLTs performed has been increasing, it has been clarified that the size of the graft liver is associated with the clinical outcome. In our previous report,<sup>2</sup> when the graft-to-recipient weight ratio (GRWR) was less than 0.8%, the graft survival rate was significantly worse than with larger grafts. The clinical manifestations, referred to as the small-for-size (SFS) syndrome, consist of poor bile production, delayed synthetic function, prolonged cholestasis, and intractable ascites, leading to septic complications and higher mortality. Although a variety of recipient and donor factors are involved in the occurrence of SFS syndrome, persistent portal hypertension or portal venous overperfusion are suggested to be important mechanisms of SFS graft injury. Animal experimental studies<sup>3,4</sup> have shown that partial diversion of portal flow to systemic circulation through a mesocaval shunt can improve the function of an SFS graft liver. A recent clinical report<sup>5</sup> also has demonstrated that a mesocaval shunt with downstream ligation of the superior mesenteric vein was effective in preventing SFS syndrome in a recipient transplanted with a SFS liver graft (GRWR of 0.61%). On the basis of these findings, it is plausible that surgical procedures to attenuate portal venous overperfusion might protect

a SFS graft from the injuries associated with SFS syndrome. In this article, we describe our new method of using a simple portocaval shunting in LDLT with a SFS graft.

## Cases

### Case 1

A 16-year-old man collapsed during rugby practice. He was diagnosed with heat stroke, with a core body temperature of 42°C. Because he became comatose and liver function deteriorated markedly, he underwent LDLT for fulminant hepatic failure. He also developed renal failure caused by rhabdomyolysis, which was reflected by a drastic increase in serum creatine phosphokinase concentration to 128,800 IU/L and necessitated hemodialysis before operation. The donor was his mother, who weighed 51 kg; the patient's body weight was 90 kg. A right lobe graft without the middle hepatic vein was transplanted. The graft weight and GRWR were 496 g and 0.55%, respectively. In the recipient, the mean portal venous pressure (PVP) was 24 mm Hg at the time of the insertion of a catheter.<sup>6</sup> It increased to 34 mm Hg after clamping of the portal vein (Fig. 1). As a standard procedure to avoid splanchnic congestion during the anhepatic period, a portocaval shunt by end-to-side anastomosis of the right portal branch and the inferior vena cava (IVC) was constructed. After the hepatic venous reconstruction, the small graft was supposed to undergo portal venous overperfusion; therefore,

---

Abbreviations: LDLT, living donor liver transplantation; GRWR, graft-to-recipient weight ratio; SFS, small-for-size; PVP, portal venous pressure; IVC, the inferior vena cava; PFV, portal vein flow velocity; ALT, alanine aminotransferase; TB, total bilirubin; PT, prothrombin time; NH<sub>3</sub>, ammonia.

From the <sup>1</sup>Department of Transplantation and Immunology, Kyoto University Graduate School of Medicine, Kyoto, Japan; <sup>2</sup>Department of Academic Surgery, Chiba University Graduate School of Medicine, Chiba, Japan.

Supported in part by a Grant-in-Aid for Research from the Ministry of Health, Labor and Welfare in Japan.

Address reprint requests to Yasutsugu Takada, MD, Department of Transplantation and Immunology, Kyoto University Graduate School of Medicine, Kawara-cho 54, Shogoin, Sakyo-ku, Kyoto 606-8507, Japan. Telephone: 81-75-751-4323, FAX: 81-75-751-4877; E-mail: takaday@kuhp.kyoto-u.ac.jp

Copyright © 2004 by the American Association for the Study of Liver Diseases

Published online in Wiley InterScience (www.interscience.wiley.com). DOI 10.1002/lt.20164

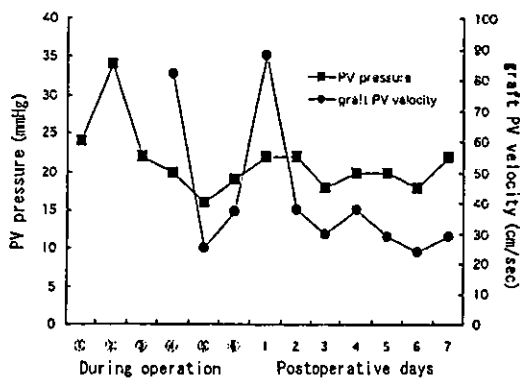


Figure 1. Changes in portal venous pressure and portal venous flow velocity of the graft liver in case 1. Abbreviations: PV pressure, portal venous pressure; graft PV velocity, portal venous flow velocity of the graft liver; During operation ①, at the time of the insertion of a catheter; ②, after the clamping of the portal vein; ③, during the anhepatic period with portocaval shunting; ④, after reperfusion of the graft with the shunt clamped; ⑤, after opening the shunt; ⑥, at the end of the operation.

the portocaval shunt was left intact and the right portal vein of the graft was anastomosed to the recipient's left portal branch (Fig. 2). After the reperfusion of the graft with the portal blood, the portal venous pressure was still high (20 mm Hg), when the shunt was occluded and subsequently decreased to 16 mm Hg by opening the shunt. The mean portal vein flow velocity (PFV) of the graft calculated by Doppler ultrasonography decreased from 82 cm/second to 25 cm/second after opening the shunt. Monitoring the PVP in the portal trunk and PFV of the graft, we decided to leave the shunt open (Fig. 1).

Postoperatively, the PVP and PFV transiently increased on day 1, however, they decreased and became stable at between 18 and 22 mm Hg and between 24 and 38 cm/seconds, respectively. The flow through the shunt was also detected by Doppler ultrasonography. Although he required mechanical ventilatory support and continuous hemodiafiltration for a long time after operation, the immediate postoperative graft function was successful. Serum transaminase levels and total bilirubin concentration decreased promptly, and prothrombin time was normalized within 1 week (Fig. 3). On day 9, according to the CT volumetry, the graft volume was estimated at 930 mL, indicating favorable regeneration. Nonetheless, plasma ammonia concentration began to increase at 3 weeks after operation and remained at more than 100 mmol/L for 4 weeks. On day 51, Tc-99m GSA (asialoglycoprotein receptor) scintigraphy revealed a normal value of liver uptake index, which suggested that the shunt flow was minimal. Thereafter, the ammonia level decreased spontaneously. He was weaned from hemodialysis and discharged with satisfactory liver function on day 66.

## Case 2

A 55-year-old man weighing 67 kg underwent LDLT for chronic hepatitis B-related liver cirrhosis and multiple hepatocellular carcinoma. A right lobe graft without the middle hepatic vein was transplanted from his wife, who weighed 49 kg. The graft weight and GRWR were 470 g and 0.70%, respectively. In the recipient operation, a portocaval shunt by end-to-side anastomosis of the right portal branch and the IVC was constructed during the anhepatic period. Judging from the distance between the portal veins of the graft and the recipient, the right portal branch of the recipient was cut off from the IVC and anastomosed to the portal vein of the graft. Then, a new shunt between the left portal branch and the IVC was made. The PFV of the graft was 43 cm/second at the end of the operation; however, it exceeded 100 cm/second despite the shunt being patent during the first 4 days after operation. Afterward, it began to decrease gradually and fell below 50 cm/second within 8 days. The postoperative course was uneventful with a successful graft function (Fig. 4). With no SFS syndrome or hyperammonemia, the patient was discharged on day 25.

## Discussion

Although the pathogenesis of SFS syndrome is multifactorial and has not been clearly identified, a small size of graft is a major contributing factor. Because cadaveric grafts are rare in Japan, LDLT with an SFS graft is sometimes inevitably selected as the only chance for treatment with fully informed consent. Attempts to

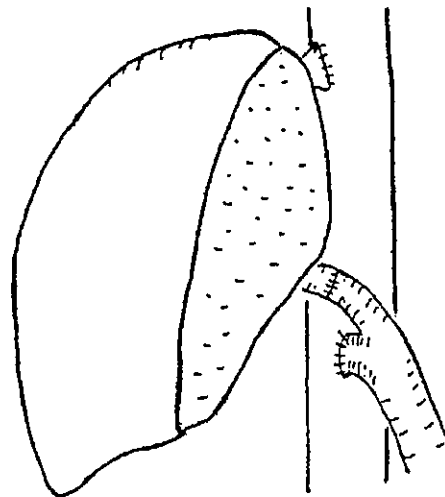


Figure 2. Scheme of the portal venous reconstruction with end-to-side portocaval shunt in case 1. A portocaval shunt by end-to-side anastomosis of the right portal branch and the inferior vena cava was left intact and the right portal vein of the graft was anastomosed to the recipient's left portal branch.

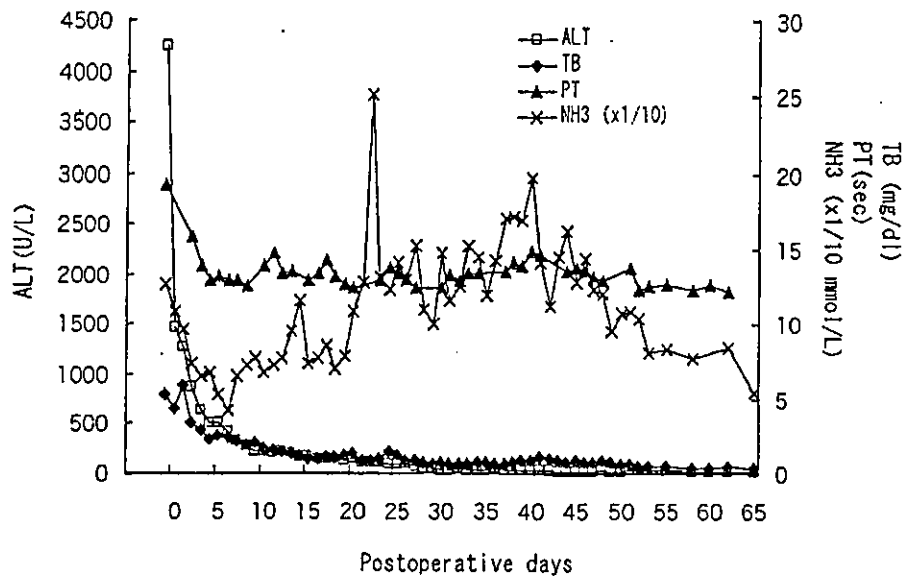


Figure 3. Changes in the liver function test results in case 1. Serum transaminase level and total bilirubin concentration decreased promptly and prothrombin time was normalized within 1 week.

reduce the risk of SFS syndrome have been made, such as auxiliary transplantation,<sup>7</sup> dual liver grafts,<sup>8</sup> splenic artery ligation,<sup>6</sup> and the prevention of outflow obstruction of the anterior segment in the right lobe graft by reconstruction of additional drainage veins or inclusion of the middle hepatic vein.<sup>9</sup> However, from the viewpoint of donor safety, these techniques cannot always be used. Even with these methods, the results have not been satisfactory in some cases. A simple and safe modality to efficiently avoid SFS syndrome is required.

In our previous study, a PVP of more than 20 mm Hg in the early period after LDLT showed a close association with morbidity and poor graft function.<sup>6</sup>

The current technique can be an option for attenuating the portal hypertension when such an elevated PVP is observed in a patient transplanted with an SFS graft. Compared with the previously reported procedure,<sup>5</sup> this is technically simple and should be feasible in most cases. However, there are 2 possible drawbacks with this technique: (1) The portal blood flow competition between the graft and the shunt may cause graft dysfunction because of portal hypoperfusion. (2) The portocaval shunt causes deleterious effects, such as hyperammonemia. However, tactics against both risks can be prepared. If the portal blood is directed predominantly through the shunt, the portal inflow to the graft will be restored by banding the portal branch to the shunt and will be adjusted to the optimal level with the guide of Doppler ultrasonography during the operation. Also, if hyperammonemia is persistent after operation and the symptom is uncontrolled by medical treatment, closure of the shunt can be performed safely as long as graft liver regeneration is confirmed. Because the current technique has been applied and shown to be effective in only 2 cases, the safety and feasibility should be confirmed through accumulation of experience.

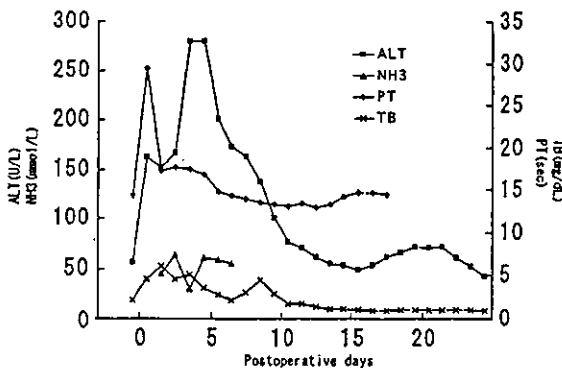


Figure 4. Changes in the liver function test results in case 2. The postoperative course was uneventful with a successful graft function. With no SFS syndrome or hyperammonemia, the patient was discharged on day 25.

References

1. Ozawa K, Uemoto S, Tanaka K, Kumada K, Yamaoka Y, Kobayashi N, et al. An appraisal of pediatric liver transplantation from living relatives. Initial clinical experiences in 20 pediatric liver transplantations from living relatives as donors. *Ann Surg* 1992; 216:547-553.

2. Kiuchi T, Kasahara M, Uryuhara K, Inomata Y, Uemoto S, Asonuma K, et al. Impact of graft size mismatching on graft prognosis in liver transplantation from living donors. *Transplantation* 1999;67:321–327.
3. Ku Y, Fukumoto J, Nishida T, Tominaga M, Maeda I, Kiyagawa T, et al. Evidence that portal vein decompression improves survival in canine quarter orthotopic liver transplantation. *Transplantation* 1995;59:1388–1392.
4. Smyrniotis VE, Kostopanagiotou G, Theodoraki K, Gamaletsos E, Kondi-Patifi A, Mystgacidou K, et al. Effect of mesocaval shunt on survival of small-for-size liver grafts: Experimental study in pigs. *Transplantation* 2003;75:1737–1740.
5. Boillot O, Delafosse B, Mecher I, Boucaud C, Pouyet M. Small-for-size partial liver graft in an adult recipient: a new transplant technique. *Lancet* 2002;359:406–407.
6. Ito T, Kiuchi T, Yamamoto H, Oike F, Ogura Y, Fujimoto Y, et al. Changes in portal venous pressure in the early phase after living-donor liver transplantation: pathogenesis and clinical implications. *Transplantation* 2003;75:1313–1317.
7. Inomata Y, Kiuchi T, Kim ID, Uemoto S, Egawa H, Asonuma K, et al. Auxiliary partial orthotopic living donor liver transplantation as an aid for small-for-size grafts in larger recipients. *Transplantation* 1999;67:1314–1319.
8. Kaihara S, Ogura Y, Kasahara M, Oike F, You Y, Tanaka K. A case of adult-to-adult living donor liver transplantation using right and left lateral lobe grafts from 2 donors. *Surgery* 2002;131:682–684.
9. Lo CM, Fan ST, Liu CL, Wei WI, Lo RJW, Lai CL, et al. Adult-to-adult living donor liver transplantation using extended right lobe grafts. *Ann Surg* 1997;226:261–270.



## Living Related Liver Transplantation

Y. Takada and K. Tanaka

---

### ABSTRACT

The introduction of cyclosporine was a major advance in liver transplantation, leading to increased numbers of liver transplant cases and, at the same time, a relative shortage of available donor organs. As one of the modalities to decrease the mortality rate on the waiting list, living related liver transplantation (LRLT) was initiated. In the LRLT program of Kyoto University, which started in June 1990, the number of cases has increased yearly as its application expanded from pediatric to adult patients. A landmark in LRLT was the introduction of right lobe grafts, which have become a standard procedure in adult-to-adult living donor liver transplantation. The basic immunosuppressive regimen consisted of tacrolimus and low-dose steroids from the beginning of our LRLT program. However, since documentation of significant improvements in clinical efficacy with Neoral compared to Sandimmun-based immunosuppression, the role of cyclosporine in LRLT is now being reevaluated.

---

**S**INCE THE INTRODUCTION of cyclosporine (CyA) in the early 1980s, the clinical results of liver transplantation drastically improved. However, the broadened indications and growing number of referrals have led to an increasing disparity between the number of patients waiting for transplantation and the number of cadaveric liver donors, resulting in a high mortality among candidates on the waiting list. In an attempt to narrow this gap, transplant centers began to employ innovative surgical techniques, such as reduced-size liver transplantation and split-liver transplantation.<sup>1,2</sup> Following the evolution of these techniques, living related liver transplantation (LRLT) was initially reported by Raia et al<sup>3</sup> in 1989. In 1990, Strong et al<sup>4</sup> reported the first successful LRLT, which was followed by Broelsch et al<sup>5</sup> and us.<sup>6</sup> LRLT was first performed in children, in which the gap between demand and supply of liver grafts was most serious. With excellent graft/patient survivals and proven donor safety, LRLT has become a routine procedure; waiting list mortality has decreased in children. Encouraging results in pediatric LRLT led to the development of adult-to-adult living donor liver transplantation (LDLT).<sup>7,8</sup>

LDLT provides several advantages to the recipient. In elective cases, the transplant operation can be scheduled before the candidate develops life-threatening complications of end-stage liver disease. Excellent graft viability can be expected because the donor is always healthy and hemodynamically stable, and preservation time is minimized. LDLT is also advantageous in patients who are

discriminated against with current organ allocation systems such as those with hepatocellular carcinoma. On the other hand, donor safety is of prime importance in LDLT, because the procedure subjects a healthy person to major surgery, potential morbidity, and mortality. The risk for the donor is balanced by the great benefit to the transplant recipient, as well as to donor self-esteem.<sup>9</sup> This article presents an overview of the development of LDLT at Kyoto University as well as the role of CyA as an immunosuppressive agent in LDLT.

### EXPANDED APPLICATION OF LDLT FROM PEDIATRIC TO ADULT PATIENTS

The use of the left lateral segment (Couinaud segment II to III) grafts is more frequent in pediatric LDLT, because it carries less risk for the donor and provides adequate hepatocyte mass for most pediatric recipients. When LDLT is applied in larger or older children, graft size matching may be achieved by using a left lobe graft (segment II to IV). This extension seems acceptable, because the risk of donor hepatectomy is usually similar to that of left lateral

---

From the Department of Transplantation and Immunology, Kyoto University Graduate School of Medicine, Kyoto, Japan.

Address reprint requests to Yasutsugu Takada, MD, Associate Professor, Department of Transplantation and Immunology, Kyoto University Graduate School of Medicine, Kawara-cho 54, Shogoin, Sakyo-ku, Kyoto 606-8507, Japan. E-mail: takaday@kuhp.kyoto-u.ac.jp

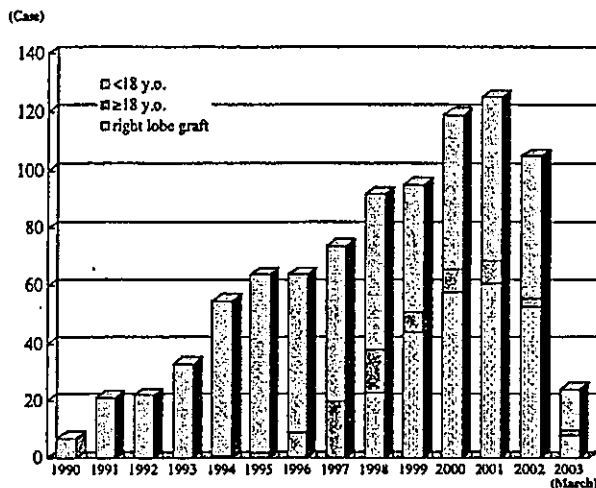


Fig 1. The yearly number of cases in LDLT program at Kyoto University.

segment grafts. However, the turning point was its application in larger teenagers and adults. The clinical significance of graft size mismatching was revealed by the small-for-size graft syndrome, even when full left lobe grafts includes the middle hepatic vein (MHV), namely, poor graft outcomes.<sup>10</sup> This syndrome consists of poor bile production, prolonged prothrombin time, intractable ascites, and prolonged cholestasis, closely associated with surgical and septic complications. The negative impact of small-for-size grafts are particularly pronounced when the recipient is chronically ill with severely deteriorated liver function.

To expand the applications of LDLT to adult patients with the restriction of using a left lobe graft, we introduced auxiliary partial orthotopic living donor liver transplantation (APOLT). In this procedure, a part of the native liver is left intact to compensate for the initial dysfunction in small-for-size grafts.<sup>11</sup> Although the actual survival rate in adult patients with chronic liver diseases treated with this APOLT technique was 60% in our initial results, the procedure failed to solve all cases of the small-for-size problem. Therefore, we started a new program using a right lobe graft from a living donor.

The initial trials of adult LDLT using right lobe grafts were reported from the Hong Kong<sup>12</sup> and the Colorado<sup>13</sup> groups. The right lobe graft was expected to meet the metabolic needs of larger patients and be advantageous to overcome size mismatching in adult recipients. Based on our experience with LDLTs of left lobe grafts, it was believed that the operative burden of the right lobectomy for the donor would be similar to that of a whole left lobectomy including the MHV, in terms of the extent of hilar dissection and the width of parenchymal transection. A subject of major concern was the increased risk to the donor due to the reduced residual liver volume.

Although the safety limit of residual liver volume for the donor has not been precisely estimated, it was believed that a normal liver could tolerate right lobectomy, leaving 30%

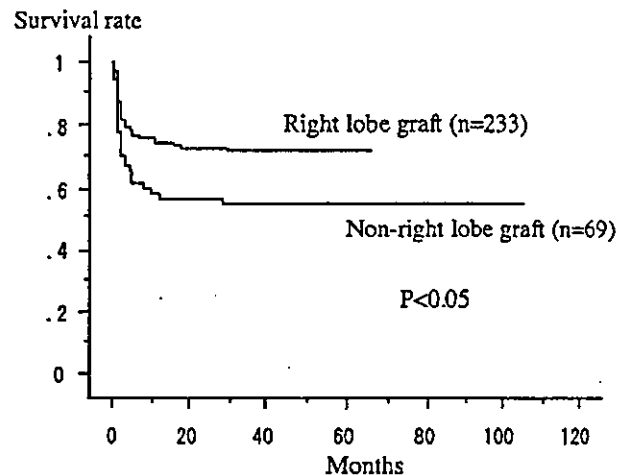


Fig 2. The survival curves of the patients treated with right lobe or non-right lobe grafts in adult-to-adult LDLT at Kyoto University.

to 40% of the liver volume.<sup>14</sup> Carefully balancing donor risk versus recipient benefit, we finally decided to introduce right lobe grafting in February 1998.<sup>8</sup> The safety and efficacy of right lobe grafting have been confirmed. Furthermore, we recently have adopted right lobe grafts with MHV (extended right lobe grafts) when the venous drainage pattern of the donor's right hepatic lobe is MHV-dominant.<sup>15</sup> In such cases, the venous drainage from segments V and VIII is substantially dependent on the tributaries of MHV, and the transection of such tributaries entails a greater risk of reduction in graft functional volume due to the venous congestion, which might lead to a critical small-for-size syndrome in the recipient.

Supported by the successful results of right lobe grafting, the number of adult LDLT cases has been remarkably increasing. Figure 1 shows the yearly number of cases in the LDLT program at Kyoto University. Between June 1990 and March 2003, 887 LDLTs were performed for 857 patients including 302 adult patients (more than 18 years old). Along with the increased number of LDLT cases performed per year (more than 100 cases after 2000), the proportion of the adult cases has increased to more than 50%. Overall 3-year patient survival rates in pediatric and adult patients were 84% and 68%, respectively. In adult primary LDLT, the 3-year patient survival rate was significantly improved among patients treated with right lobe grafts (72%) compared to those with non-right lobe grafts (55%) ( $P < .05$ , Fig 2).

#### IMMUNOSUPPRESSION IN LDLT

Because the efficacy of CyA in liver transplantation had been established, CyA was used as a main immunosuppressive agent in some centers for the initial LDLT series.<sup>5</sup> On the other hand, at Kyoto University, the basic immunosuppression regimen consisted of tacrolimus (TAC) and low-dose steroids from the beginning of our LDLT program.<sup>6,16</sup>



Our initial protocol for TAC administration was based on the Pittsburgh experience.<sup>17</sup> High-dose intravenous (IV) induction was performed, in which TAC was given at a dose of 0.075 mg/kg infused over 4 hours every 12 hours, and then switched to oral administration (0.3 mg/kg/d). Since extremely high trough levels were frequently observed in this first protocol, the IV dosage was reduced to 0.03 mg/kg. Finally, to avoid the drastic increase in blood levels of TAC detected even in the low-dose IV induction group, the induction protocol was changed to enteric administration of TAC (orally or via the gastric tube). At present, the dosage of enteric TAC administration is determined to maintain the 12-hour trough level between 10 and 15 ng/mL in the first 2 postoperative weeks.

Since the US and European multicenter studies comparing TAC versus Sandimmun CyA in adult cadaveric liver transplantation<sup>18,19</sup> as well as a controlled study in pediatric cases<sup>20</sup> showed improved graft survival and lower rates of acute rejection episodes, most centers have used TAC for LDLT. However, with the accumulation of cases managed with TAC, the incidence of adverse reactions, such as neurotoxicity, nephrotoxicity, and diabetes mellitus, has been reported to be relatively high. When TAC-related adverse effects are unresponsive to dose reduction, the patients are often treated by conversion to CyA. Emre et al<sup>21</sup> suggested that conversion to CyA in liver transplant recipients can be accomplished safely, with no increased risk of rejection and excellent long-term outcomes. Also in LDLT patients, favorable outcomes after conversion from TAC to CyA have been reported.<sup>22</sup>

Recently, it has been shown that Neoral, which is the microemulsion formulation of CyA, is more readily absorbed from the gastrointestinal tract than Sandimmun. Furthermore, its absorption is relatively independent of bile flow and food intake.<sup>23</sup> Due to the pharmacokinetic stability provided by this advanced formulation as well as the development of optimal monitoring (C<sub>2</sub> monitoring), significant improvements have been documented among liver transplantations with Neoral-based immunosuppression.<sup>24</sup>

Encouraged by these results in cadaveric liver transplantation, studies to evaluate the effects of Neoral-based immunosuppression in LDLT are in progress in centers including our institution.

#### REFERENCES

1. Bismuth H, Houssin D: *Surgery* 95:367, 1984
2. Pichlmayr R, Ringe B, Gubernatis G, et al: *Langenbecks Arch Chir* 373:127, 1989
3. Raja S, Nery J, Mies S: *Lancet* 2:497, 1989
4. Strong RW, Lynch SV, Ong TH, et al: *N Engl J Med* 322:1505, 1990
5. Broelsch CE, Whittington PF, Emond JC, et al: *Ann Surg* 214:428, 1991
6. Ozawa K, Uemoto S, Tanaka K, et al: *Ann Surg* 216:547, 1992
7. Kawasaki S, Makuuchi M, Matsunami H, et al: *Ann Surg* 227:269, 1998
8. Inomata Y, Uemoto S, Asonuma K, et al: *Transplantation* 69:258, 2000
9. ASTS: Ethics Committee: *Liver Transplant* 6:815, 2000
10. Kiuchi T, Kasahara M, Uryuhara K, et al: *Transplantation* 67:321, 1999
11. Inomata Y, Kiuchi T, Kim I, et al: *Transplantation* 67:1314, 1999
12. Lo CM, Fan ST, Liu CL, et al: *Transplantation* 63:1524, 1997
13. Wacks ME, Bak THE, Karrer FM, et al: *Transplantation* 66:1313, 1998
14. Ito T, Kiuchi T, Egawa H, et al: *Transplantation* 76:158, 2003
15. Maetani Y, Itoh K, Egawa H, et al: *Transplantation* 75:97, 2003
16. Uemoto S, Tanaka K, Honda K, et al: *Transplantation* 55:288, 1993
17. Todo S, Fung JJ, Starzl TE, et al: *Ann Surg* 212:295, 1990
18. The US Multicenter FK506 Liver Study Group: *N Engl J Med* 331:1110, 1994
19. European FK506 Multicenter Liver Study Group: *Lancet* 334:423, 1994
20. Tzakis AG, Reyes J, Todo S, et al: *Transplant Proc* 23:3020, 1991
21. Emre S, Genyk Y, Schluger LK, et al: *Transplant Int* 13:73, 2000
22. Hashikura Y, Ogino S, Ikegami T, et al: *Liver Transplantation* 9:C-66, 2003
23. Levy GA: *Transplant Proc* 30:1812, 1998
24. Levy GA: *Transplant Proc* 32:2S, 2000

## 肝細胞癌の再発は必ず起こるのか

高田 泰次\* 上田 幹子\*  
江川 裕人\* 田中 絃一\*

索引用語：肝細胞癌，肝移植，生体肝移植，再発

### 1 はじめに

これまでの肝細胞癌に対する治療は併存する慢性肝障害のために治療法の選択が制限され、また肝内転移や肝炎ウイルスに関連した多中心性発癌による再発が高率である。一方、肝移植は癌病変の除去と同時にその背景にある慢性肝疾患を根本的に治療できるという利点がある。最近本邦でも成人に対する生体肝移植が広く行われるようになり、肝細胞癌に対しても生体肝移植が導入されている。しかし、移植後の癌再発は術後成績に大きな影響を与え、特に進行癌ほど再発率が高いことが示されている。本稿では、欧米での脳死肝移植における術後再発に関する知見を概略し、また筆者らの施設でのこれまでの肝細胞癌に対する生体肝移植の成績を紹介する。

### 2 肝細胞癌に対する脳死肝移植

欧米での脳死肝移植では、初期の頃は切除不能進行肝細胞癌に対して積極的に肝移植が行われたが、術後再発が多く5年生存率は

15～30%とその成績は不良であった<sup>1-3)</sup>。そして、肝移植実施数の増加に伴い移植臓器不足や医療経済などの問題が深刻化し、適応の見直しがはかられた。その中で1996年にMazzaferroら<sup>4)</sup>、術前画像診断で脈管浸潤およびリンパ節転移がなく、腫瘍が単発ならば直径5cm以下、多発ならば3個以下で最大径が3cm以下の場合、75%の生存率が得られると報告した。これらの条件、いわゆる「ミラノ基準」を満たす症例は肝癌以外の移植症例と同等の成績が得られることが示され、その後世界的にもこの基準が肝細胞癌に対する移植適応として一般的に受け入れられるようになり、本邦の脳死肝移植の適応基準にも採用されている。このような背景には、数に限りのある移植臓器を有効に利用するためには、再発の危険性が少ない症例を移植適応とするべきであるという考え方が存在している。

一方で、このミラノ基準を超えた症例でも同等の成績が期待できる可能性があり、より多くの肝癌患者を救命することを目的として

Yasuji TAKADA *et al*: Recurrence of hepatocellular carcinoma after liver transplantation

\*京都大学大学院医学研究科移植免疫医学 [〒606-8507 京都市左京区聖護院川原町54]

表1 京都大学での肝細胞癌に対する生体肝移植症例 (n = 103, 1999.02 ~ 2004.09)

男女比	男 71 : 女 32
年齢	22 ~ 69 歳 (中央値 54 歳)
背景肝疾患	C 型肝硬変 (61), B 型肝硬変 (33), アルコール性肝硬変 (3), 原発性胆汁性肝硬変 (2), その他 (4)
Child-Pugh 分類	A (16), B (38), C (49)
MELD Score	~ 10 (21), 11 ~ 20 (53), 21 ~ 30 (24), 31 ~ (5)
癌進行度 (原発性肝癌取扱い規約)	I (14), II (35), III (42), IV-A (2), incidental (10)
ミラノ基準	内 (50), 外 (43) (incidental 10 例除く)
初発 : 再発	初発症例 (24) : 再発症例 (79)
前治療	TAE (65) PEIT, RFA (49) 肝切除 (13)

( ) 内は症例数

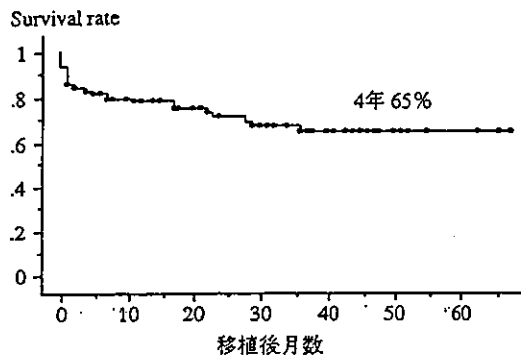


図1 移植後累積生存率 (n = 103)

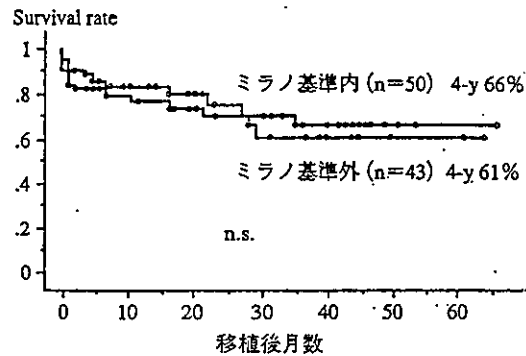


図2 ミラノ基準と移植後累積生存率

incidental 症例 (n = 10) を除くと, 4 年生存率はミラノ基準内群 (n = 50), 基準外群 (n = 43) でそれぞれ 66%, 61% であった (p = 0.953, log-rank test).

適応基準の拡大を図る報告も見られる。Yao らは<sup>9)</sup>, 単発例では径が 6.5 cm 以内, 多発例では 3 個以内で最大径が 4.5 cm 以内かつ腫瘍径の合計が 8 cm 以内という基準 (UCSF 基準) を提唱し, これによると 5 年生存率は 75.2% であった。

### 3 京都大学での肝細胞癌に対する生体肝移植

#### 1. 移植適応

生体肝移植では, 特定の患者 (レシピエント) に対する特定のドナーから肝臓が提供されるため, 移植臓器の有効な配分という脳死移植の場合の前提にとらわれない。そのため, 術後再発という観点から厳しく設定された「ミラノ基準」については, 移植の

有効性から見直すと適応拡大できる可能性がある。このような生体肝移植の特徴をふまえた上で, 京都大学移植外科では独自の適応基準を設けて 1999 年 2 月より肝細胞癌に対する生体肝移植を開始した<sup>6)</sup>。すなわち移植適応として, 1) 他の治療法では制御不能である, または肝機能不良のため他治療が適応されない肝細胞癌症例で, 2) 腫瘍の進展度において, 肝外病変がなく, 肝静脈, 門脈など脈管への肉眼的浸潤・腫瘍栓がないこととし, 腫瘍の数や大きさは考慮していない。

#### 2. 対象患者

2004 年 9 月までに, 103 例の肝細胞癌症

表2 移植後再発症例

年齢(歳)	性別	Stage	基準	個数	最大径	再発時期(月)	初回再発部位	治療	予後(月)
46	男	Ⅲ	外	5	5	26	肺	切除	生存(66)
31	男	Ⅲ	外	4	4	8	肺	放射線	死亡(29)
59	男	Ⅲ	外	15	5.5	3	脳	切除・放射線	死亡(17)
23	女	Ⅲ	外	23	22.5	8	横隔膜	化学療法	死亡(28)
27	女	I	内	4	2.1	44	肝	PEIT	生存(48)
54	男	Ⅲ	内	3	4	7	副腎・骨	TAE・放射線	死亡(17)
62	女	Ⅲ	外	7	3.5	3	肺	切除	死亡(23)
59	男	Ⅲ	内	4	5.2	14	肝	RFA	死亡(36)
56	男	Ⅱ	内	2	4.9	6	腹腔リンパ節		死亡(7)
30	男	Ⅲ	外	9	9	22	肝	化学療法	死亡(30)
54	男	Ⅱ	外	96	1.8	16	骨	放射線	生存(20)
60	男	Ⅱ	内	15	3.0	18	骨	切除	生存(20)
54	男	Ⅲ	外	380	4	6	骨	RFA	生存(14)
51	女	Ⅲ	外	40	3	6	肺	化学療法	生存(8)

Stageとミラノ基準は術前画像診断から判定、腫瘍の個数と最大径(cm)は摘出肝病理所見による。

例に生体肝移植を行った。患者背景(表1)では、男女比が71:32、年齢が22~69歳(中央値54歳)で、HCVまたはHBV関連肝硬変の合併が94例に見られた。移植前肝機能はChild-Pugh分類でAが16例、Bが38例、Cが49例で、MELD Scoreは10以下が21例、11~20が53例、21~30が24例、31以上が5例で中央値は14であった。原発性肝癌取扱い規約による術前の進行度分類ではStage I, II, III, IV-Aがそれぞれ14, 35, 42, 2例であった。脈管浸潤症例を除外しているため原則的にはStage IV-Aは適応外であるが、若年患者のために(22歳と30歳)例外的にVp3の腫瘍に対して2例の肝移植を行った。また、術前画像診断では腫瘍が指摘されなかった、または前治療によって腫瘍が完全にコントロールされていると診断されていた症例で、肝硬変を適応として移植を行ったところ摘出肝病理検査でviableな腫瘍が見つかった(incidental)症例が10例含まれている。このincidental 10例を除くと、ミラノ基準を満たす症例が50例、超える症例が43例であった。肝細胞癌が初発で肝移植

が最初の治療であった症例は24例で、残り79例(77%)は移植前に他の治療を受けており、3回以上の治療歴のある症例は約半数(46例)を占めていた。再発予防対策として、Stage III以上の症例には、ファルモルピシン10mg/m<sup>2</sup>を術中から投与し、術後も体力の回復を待って可及的早期より同量を週に1度、10回まで投与することになっている。移植後観察期間は1~68カ月(中央値32カ月)である。

### 3. 移植後生存率

全103例の4年累積生存率は65%であった(図1)。Incidental tumorを除く93例で術前診断においてミラノ基準を満たす症例(50例)と基準を超える症例(43例)を比較すると(図2)、4年生存率はそれぞれ66%と61%であり、統計学的には有意差を認めなかった。

### 4. 移植後再発

移植後の肝細胞癌再発はこれまで14例に見られ(表2)、非癌死を打ちきりとした場合の全体の累積再発率は4年で25%であった。最初に再発が発見された臓器は、肺が4