

[del]) and PreC (A1896) accompanied HCV infection. However, this patient became HBeAg-positive, and the appearance of the wild types PreC and BCP at phase 4 accompanied the resolution of HCV infection, together with a transient increase in the suppressed HBV viral load to become equal to the pre-HCV infection level. Case 2, who was HBeAg-negative, had mutation of PreC (A1896) and double mutations of BCP (T1762/A1764). Interestingly, HCV infection was accompanied in this patient by the appearance of PreC wild type (G1896) from phase 3 and an increase in the transiently suppressed HBV viral load to a level higher than that determined before HCV infection. Thus, the change in HBeAg state in Case 1 was associated with changes in BCP and PreC sequences, while in Case 2, there were no changes in HBeAg state and BCP. In both cases, nucleotide sequences of PreC changed in parallel with fluctuations of HBV viral loads but those (nt 1136–1148) of Enh1 did not change in spite of fluctuations in HBV viral loads. Figure 2 shows the nucleotide sequences of Enh1, Enh2 including BCP, and PreC.

HCV 5'-UTR and HCV Spontaneous Clearance

In both cases, acute HCV superinfection resolved spontaneously, but no nt A insertion at position 193 of HCV 5'-UTR was detected.

Nucleotide Sequences of HBV Enh1 and Enh2, and Amino Acid Sequences of HCV Core Region

In both cases, nucleotide sequences (nt 1136–1148) of the binding site for members of the nuclear receptor family in Enh1 did not change during HCV infection, but nucleotide sequences (nt 1755–1768) in Enh2 changed into mutant type only at phase 3. Case 1 showed 8-bp deletions of nt 1758–1765, and Case 2 showed T-to-A mutation at nt 1768. The amino acid sequences of the putative DNA-binding motif site in the HCV core were SPRG, as reported previously (19).

DISCUSSION

The impact of acute HCV superinfection on chronic HBV infection remains poorly understood. Previous reports showed that HCV superinfection in HBsAg carries

could result in severe and progressive liver disease, including fulminant/subfulminant hepatitis (1–5). Furthermore, it is also reported that HCV superinfection might exert a suppressive effect on HBV replication and enhance sero-clearance of HBV antigens (HBeAg seroconversion and HBsAg clearance) (6–8), and HCV could potentially take over the role of HBV in causing persistent chronic hepatitis (8). However, the virological impact of HCV superinfection on HBV infection is still not clear. The aim of our study was to analyze the virological impact of acute HCV superinfection on chronic HBV infection. For this purpose, we investigated the nucleotide sequences of HBV Enh1, Enh2 including BCP, PreC, and HCV 5'-UTR and amino acid sequences of the HCV core.

Whether the nucleotide sequences of BCP and PreC affect the HBeAg state during acute HCV superinfection on chronic HBV infection is debatable. Mutation in PreC (A1896) is associated with loss of HBeAg (9, 10). Double mutation in BCP (T1762/A1764) is also associated with reduced synthesis of HBeAg through the suppression of transcription of precore mRNA (11–14). On the other hand, the effects of BCP mutation are not as thorough as those of PreC mutation (12, 13), although BCP mutation is implicated in seroconversion to HBeAb in some carriers whose PreC of HBV-DNA is of the wild type (G1896) (11, 29). In the present study, the HBeAg state of Case 1 (who was HBeAg-positive at the time of HCV infection) changed along with nucleotide sequences of BCP and PreC, whereas that of Case 2 (who was HBeAg-negative at the time of HCV infection) did not change along with those of PreC. These findings suggest that BCP and PreC sequences might change in different manners by HBeAg state (positive or negative) at the time of HCV infection. It should be cautioned, however, that the present results are based on only two cases, and further large-scale studies should be conducted to confirm our findings.

The mechanisms that influence HBV viral kinetics during HCV superinfection are poorly understood. Bock and coworkers reported that mutants of Enh1 have a major impact on HBV replication and that these mutations might determine the switch from high to low levels of viral replication (17). However, our results showed that nucleotide sequences of the binding site for COUP-TF1,

Fig 1. Clinical courses of two patients with HBV related-cirrhosis and acute HCV superinfection. Both patients were infected with HBV genotype C and HCV genotype 1b. In both patients, chronic HBV infection was transiently suppressed by HCV infection but persisted later while acute HCV infection resolved spontaneously. Viral kinetics of HBV and HCV indicated reciprocal change. (A) A 53-year-old male with active hepatitis (HBeAg-positive, high levels of HBV-DNA). (B) An 83-year-old female with less active hepatitis (HBeAg-negative, lower levels of HBV-DNA), in comparison with Case 1. In both cases, nucleotide sequences of precore (PreC), but not those of basic core promoter (BCP), influenced HBV viral load. The shaded area represents HBV-DNA level below the detection limit. The cutoff index of HBeAg is shown by the light line at the top of A. HBV Amplicor is shown as the heavy line at the top of A and B. del, deletion; TAE, transcatheter arterial embolization. *PreC (nt 1896) in phase 4 of Case 2 was mixed wild (G1896)- and mutant (A1896)-type virus, and wild type was more dominant than mutant type.

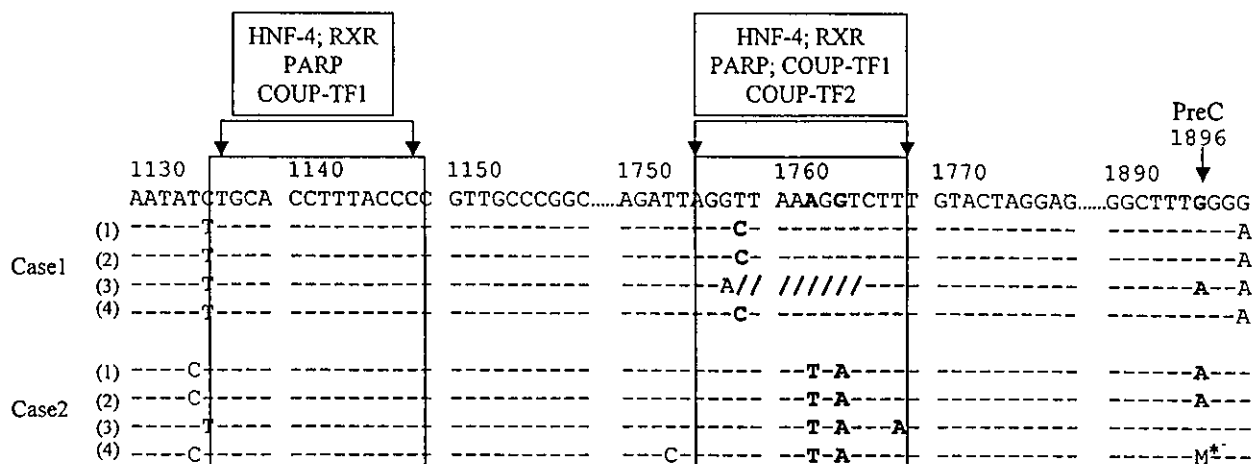


Fig 2. Nucleotide sequences of HBV enhancer 1 (Enh1), enhancer 2 (Enh2), including basic core promoter (BCP), and precore (PreC). The binding sites for COUP-TF1, HNF4, PARP, and RXR are shown in gray shading (nt 1136–1148 of Enh1, nt 1755–1768 of Enh2). The source of the binding sites is Schuttler *et al.* (20). Phase 1; HCV-Ab-negative and HCV-RNA-negative before HCV infection. Phase 2: High titer of HCV-RNA during HCV infection (early phase of HCV infection), Phase 3: Low titer of HCV-RNA during HCV infection (late phase of HCV infection), Phase 4: HCV-Ab-positive and HCV-RNA-negative accompanied by spontaneous resolution of HCV infection (resolution phase of HCV infection). Nucleotide sequences of the binding sites in Enh1 did not change with the development of acute HCV infection, but those in Enh2 changed to mutant type at phase 3. M* of PreC (nt 1896) in phase 4 of Case 2—mixed wild (G1896)- and mutant-(A1896)-type virus (wild type was more dominant than mutant type).

HNF4, PARP, and RXR in Enh1 did not change with fluctuations in HBV-DNA levels. The present results are based on only two cases and the exact reason(s) for this discrepancy is not known at present. Recently, Haushofer and colleagues suggested that there might be mutual influence on HBV and HCV replication at coinfection and that HBV viral loads might be different according to HBeAg state and existence of HCV-RNA (30). In our study, viral kinetics of HBV and HCV certainly indicated reciprocal changes, and the HBV viral load following spontaneous resolution of HCV infection was equal to (Case 1, who was HBeAg-positive and had wild-type PreC at the time of HCV infection) or greater than (Case 2 who was HBeAg-negative and had mutant PreC at the time of HCV infection) the HBV viral load before HCV superinfection. Thus, our results showed that HBV viral kinetics also differ according to HBeAg state at the time of HCV infection and existence of HCV-RNA. Interestingly, the PreC mutant reversed (Case 1) or changed (Case 2) into wild type along with resolution of HCV infection, suggesting that nucleotide sequences of PreC are another viral factor that could affect the HBV viral load. Considered collectively, these results suggest that HBV viral load at HCV superinfection might be influenced by a variety of factors, including HBeAg state, sequences of PreC, and existence of HCV-RNA. Further large-scale study should be conducted to confirm not only the virological but also the clinical impact of acute HCV superinfection on chronic HBV infection.

Acute HCV infection becomes chronic in more than 80% of infected individuals (31, 32), while less than 5% of those with acute HBV infection will progress into chronic infection (33, 34). Hence, the spontaneous clearance of HCV noted in our study is very unusual. Furthermore, this course is in contrast to the findings of earlier studies that HCV usually suppresses HBV in patients with HBV/HCV dual infection (7, 8, 19), especially the stronger suppression of HBV Enh1 by the HCV core from genotype 1b (20). A recent report showed that nt A insertion at position 193 of the 5'-UTR might affect spontaneous HCV clearance by acute hepatitis B superinfection during liver transplantation (18). However, our analysis showed no nucleotide A insertion at position 193 despite spontaneous HCV resolution. The discrepancies between our results and the above studies may be due to one or more factors. The first is probably related to the different setting used for investigating acute HCV superinfection on chronic HBV infection. The second is probably due to the virological difference in participating patients including genotype of HBV (genotype C)/HCV (genotype 1b). The third reason is related to differences in subjects with respect to the severity of liver disease and duration of HBV infection. Both our cases had suffered from HBV infection for more than 20 years, and they advanced to the stage of liver cirrhosis. Hence, while chronic HBV infection could be transiently suppressed, it might not be taken over by HCV infection. Further studies of a larger population are important to confirm these findings.

The molecular mechanisms responsible for the suppressive effect of dual HBV/HCV infection are still unclear. Shih *et al.* reported that *in vitro* HCV core protein suppressed HBV replication by inhibiting the process of transcription and encapsidation of HBV pregenomic RNA, which contained the putative DNA-binding motif (SPRG; amino acids 99–102) (19). Schuttler and coworkers reported *in vitro* that HCV core protein could suppress Enh1 up to 11-fold and Enh2 up to 3- to 4-fold, but not 5'-terminally truncated constructs of Enh1 and common mutants (8-bp deletion or double mutation of BCP) of Enh2 (20). Based on these results, they concluded that HCV core protein suppressed the activity of Enh1/2 to contain binding sites for COUP-TF1, HNF4, PARP, and RXR, members of the nuclear receptor family (20). In both cases reported in the present study, the amino acid sequences of the putative DNA-binding motif site in HCV core were SPRG, as reported previously (19). Nucleotide sequences of the binding site for members of the nuclear receptor family in Enh1 did not change but those in Enh2 did change during HCV infection. Specifically, sequences in Enh2 changed at phase 3 (late phase of acute HCV infection), suggesting that suppression of HBV by HCV at this phase might be milder than that of phase-2 (early phase of acute HCV infection). We could not determine, in this clinical study of only two cases, whether these changes in Enh2 might occur as part of the process of escape from HBV suppression by HCV or the process of HCV elimination by HBV or whether they occur for other reasons. Further investigations should be conducted to confirm the clinical significance of these binding sites.

To our knowledge, our study is the first to investigate clinically the virological impacts of acute HCV superinfection on chronic HBV infection. Further large-scale studies should be conducted to confirm the virological and clinical impacts of HCV infection on HBV infection.

REFERENCES

- Liaw YF, Tai DI, Chen TJ, Chu CM, Huang MJ: Alpha-fetoprotein changes in the course of chronic hepatitis: Relation to bridging hepatic necrosis and hepatocellular carcinoma. *Liver* 6:133–137, 1986
- Tandon BN, Ireshad M, Acharya SK, Joshi YK: Hepatitis C virus infection is the major cause of severe liver disease in India. *Gastroenterol Jpn* 26:S192–S195, 1991
- Chu CM, Sheen IS, Liaw YF: The role of hepatitis C virus in fulminant viral hepatitis in an endemic area of hepatitis A and B. *Gastroenterology* 107:189–195, 1994
- Wu JC, Chen CL, Hou MC, Chen TZ, Lee SD, Lo KJ: Multiple viral infection as the most common cause of fulminant and subfulminant viral hepatitis in an area endemic for hepatitis B: Application and limitation of the polymerase chain reaction. *Hepatology* 19:836–840, 1994
- Liaw YF: Hepatitis C virus superinfection in patients with chronic hepatitis B virus infection. *J Gastroenterol* 37:65–68, 2002
- Liaw YF, Lin SM, Sheen IS, Chu CM: Acute hepatitis C virus superinfection followed by spontaneous HBeAg seroconversion and HBsAg elimination. *Infection* 19:250–251, 1991
- Pontisso P, Ruvoletto MG, Fattovich G, Chemello L, Gallorini A, Roul A, Alberti A: Clinical and virological profiles in patients with multiple hepatitis virus infections. *Gastroenterology* 105:1529–1533, 1993
- Liaw YF, Tsai SL, Chang JJ, Sheen IS, Chien RN, Lin DY, Chu CM: Displacement of hepatitis B virus by hepatitis C virus as the cause of continuing chronic hepatitis. *Gastroenterology* 106:1048–1053, 1994
- Carman WF, Jacyna MR, Hadziyannis S, Karayiannis P, McGarvey MJ, Makris A, Thomas HC: Mutation preventing formation of hepatitis B e antigen in patients with chronic hepatitis B infection. *Lancet* 2:588–591, 1989
- Okamoto H, Yotsumoto S, Akahane Y, Yamanaka T, Miyazaki Y, Sugai Y, Tsuda F, Tanaka T, Miyakawa Y, Mayumi M: Hepatitis B viruses with precore region defects prevail in persistently infected hosts along with seroconversion in the antibody against e antigen. *J Virol* 64:1298–1303, 1990
- Okamoto H, Tsuda F, Akahane Y, Sugai Y, Yoshida M, Moriyama K, Tanaka T, Miyakawa Y, Mayumi M: Hepatitis B virus with mutations in the core promoter for an e antigen-negative phenotype in carriers with antibody to e antigen. *J Virol* 68:8102–8110, 1994
- Takahashi K, Aoyama K, Ohno N, Iwata K, Akahane Y, Baba K, Yoshizawa H, Mishihiro S: The precore/core promoter mutant (T1762A1764) of hepatitis B virus: clinical significance and an easy method for detection. *J Gen Virol* 76:3159–3164, 1995
- Buckwold VE, Xu Z, Chen M, Yen TS, Ou JH: Effects of naturally occurring mutation in the hepatitis B virus basal core promoter on precore gene expression and viral replication. *J Virol* 70:5845–5851, 1996
- Yu X, Mertz JE: Promoters for synthesis of the pre-C and pregenomic mRNAs of human hepatitis B virus are genetically distinct and differentially regulated. *J Virol* 70:8719–8726, 1996
- Baumert TF, Rogers SA, Hasegawa K, Liang TJ: Two core promoter mutations in a hepatitis B virus strain associated with fulminant hepatitis result in enhanced viral replication. *J Clin Invest* 98:2268–2276, 1996
- Scaglioni PP, Melegari M, Wands JR: Biological properties of hepatitis B viral genomes with mutations in the precore promoter and precore open reading frame. *Virology* 233:374–381, 1997
- Bock CT, Malek NP, Tillmann HL, Manns MP, Trautwein C: The enhancer 1 core region contributes to the replication level of hepatitis B virus *in vivo* and *in vitro*. *J Virol* 74:2193–2202, 2000
- Sergi C, Arnold JC, Rau W, Otto HF, Hofmann WJ: Single nucleotide insertion in the 5'-untranslated region of hepatitis C virus with clearance of the viral RNA in a liver transplant recipient during acute hepatitis B virus superinfection. *Liver* 22:79–82, 2002
- Shih CM, Lo SJ, Miyamura T, Chen SY, Lee YH: Suppression of hepatitis B virus expression and replication by hepatitis C virus core protein in HuH-7 cells. *J Virol* 67:5823–5832, 1993
- Schuttler CG, Fiedler N, Schmidt K, Repp R, Gerlich WH, Schaefer S: Suppression of hepatitis B virus enhancer 1 and 2 by hepatitis C virus core protein. *J Hepatol* 37:855–862, 2002
- Alter HJ, Purcell RH, Shih WJ, Melpolder JC, Houghton M, Choo QL, Kuo G: Detection of antibody to hepatitis C virus in prospectively followed transfusion recipients with acute and chronic non-A, non-B hepatitis. *N Engl J Med* 321:1494–1500, 1989

HEPATOLOGY

Clinical and pathological characteristics of the autoimmune hepatitis and primary biliary cirrhosis overlap syndrome

YOSHIYUKI SUZUKI,* YASUJI ARASE,* KENJI IKEDA,* SATOSHI SAITOH,* AKIHITO TSUBOTA,* FUMITAKA SUZUKI,* MASAHIRO KOBAYASHI,* NORIO AKUTA,* TAKASHI SOMEYA,* YUZO MIYAKAWA[†] AND HIROMITSU KUMADA*

*Department of Gastroenterology, Toranomon Hospital and [†]Miyakawa Memorial Research Foundation, Tokyo, Japan

Abstract

Background and Aims: The defining of the autoimmune hepatitis (AIH) and primary biliary cirrhosis (PBC) overlap syndrome as a separate clinicopathological entity has been controversial and temporally and geographically subjective.

Methods: From 1979 until 2000, 227 patients diagnosed with AIH, PBC or the overlap thereof were treated. Cases with genuine AIH/PBC overlap syndrome were sorted out using close clinical follow up and serial liver biopsies.

Results: Of the 227 patients, 19 (8.4%) were diagnosed with the AIH/PBC overlap syndrome. They all cleared a score >10 for the diagnosis of AIH, and tested positive for antimitochondrial antibodies during their courses. Long-term follow up with frequent histological examinations, however, established the diagnosis of AIH/PBC overlap syndrome in only two (0.8%) patients. The most powerful factor distinguishing AIH from PBC was acidophilic bodies in lobules that were detected significantly more frequently in patients with AIH than PBC or spurious overlap syndrome (39/46 [85%] vs 3/85 [4%], $P < 0.001$). It was more reliable than bile-duct lesions for the distinction of PBC from AIH.

Conclusions: Although AIH/PBC overlap syndrome does exist, it is infrequent and needs to be diagnosed carefully using close clinical and histological follow up to enable timely and effective treatment.

© 2004 Blackwell Publishing Asia Pty Ltd

Key words: acidophilic body, autoimmune hepatitis, overlap syndrome, primary biliary cirrhosis.

INTRODUCTION

Autoimmune liver disease has an uneven geographic distribution, and is much less frequent in Japan than in Western countries. There have been increasing registrations of autoimmune liver disease in the Ministry of Health, Labor and Welfare of Japan. It is not certain, however, whether this increase is attributable to a real increase as a result of changes towards a more Western lifestyle, or to the inclusion of more patients previously unrecognized before the advent of modern diagnostic techniques. In fact, the diagnostic criteria for autoimmune hepatitis (AIH) has been modified often, in 1993¹ and 1999² by International Committees, as well as in 1992 and 1996 in Japan.³ The lack of specific markers

for AIH makes it difficult to establish a clear-cut and indisputable consensus for its diagnosis.

By contrast, antimitochondrial antibodies (AMA) are widely accepted as the hallmark of primary biliary cirrhosis (PBC),^{4–6} although doubts have been cast on their being essential to diagnosis.^{7,8} In addition, there are characteristic bile-duct lesions and granuloma that help diagnose PBC. Although there are many features in common between AIH and PBC,^{7–10} they are at the opposite ends of the spectrum of autoimmune liver disease and differ remarkably with respect to pathological findings and therapeutic interventions.

During the 1970s, there were scattered reports on the co-occurrence of AIH and PBC in the same patients.^{11–14} Since then, development of methods to

Correspondence: Dr Yoshiyuki Suzuki, Department of Gastroenterology, Toranomon Hospital, 2-2-2 Toranomon, Minato-ku, Tokyo 105-8470, Japan. Email: suzunari@interlink.or.jp

Accepted for publication 22 October 2003.

distinguish between AIH and PBC, along with specific therapies for treating each condition using immunosuppressants and ursodeoxycholic acid (UDCA), respectively, appeared to temporarily draw a clear line between them.^{15,16} At present, however, there is much argument either for the common occurrence (7%) of an AIH/PBC overlap syndrome,¹⁷ for which a combination therapy with immunosuppressants and UDCA is indicated, or for disproving the concept of the overlap syndrome by defining it as a hepatic form of PBC.^{18,19} In Japan, where AIH and PBC are much less common than in Western countries, the overlap syndrome, should it exist, would be taken more seriously in evaluating the existence of the 'true' AIH/PBC overlap syndrome. A close survey with long-term follow up has been conducted on patients with autoimmune liver disease in a city hospital in Japan to verify the authenticity of the AIH/PBC overlap syndrome.

METHODS

Patient populations

From 1979 to 2000, 227 patients with autoimmune liver disease were treated in the Gastroenterology Department of Toranomon Hospital in Tokyo, Japan. The diagnosis of autoimmune liver disease, including AIH, PBC and the overlap thereof, was made based on clinical symptoms, biochemical and serological tests and markers of hepatitis virus infections in sera taken at the first liver biopsy before the start of therapy. They were followed for biochemical and serological findings, as well as pathological changes in the liver. The study design conformed to the 1975 Declaration of Helsinki and was approved by the Ethics Committee of the institution. A written informed consent was obtained from each patient.

Diagnostic criteria

The patients with AIH fulfilled the score for 'definite AIH' (>15) or 'probable AIH' (10–15), using the criteria of the International Autoimmune Hepatitis Group as proposed in 1999; they satisfied the Japanese diagnostic criteria agreed upon in 1994, also. The diagnosis of PBC was based on the criteria implemented by the Japanese Ministry of Health and Welfare in 1992. The patients who satisfied criteria for both AIH and PBC at presentation or during follow up were deemed to have the AIH/PBC overlap syndrome.

Autoantibodies

The presence of antinuclear antibodies (ANA), anti-smooth muscle antibodies (ASMA) and AMA was determined using indirect immunofluorescence on rat liver tissues with the standard methods. AMA of M2 category²⁰ was determined using a standard ELISA method incorporating beef pyruvate dehydrogenase.

Histological examinations

Liver specimens were obtained with a Silverman needle under laparoscopy. They were fixed with formalin, embedded in paraffin, cut into 2- μ m slices and stained with HE, D-periodic acid Schiff (D-PAS) and silver. Specimens from patients suspected of the overlap syndrome were cut serially, and three serial 2- μ m slices were each stained with either HE, D-PAS or silver, and the maneuver was performed 10 times for coverage of a total thickness of 120 μ m. In addition, sections were stained with Evan's van Gieson and chromotrim-aniline blue as well as for iron. Histological assessments were made by a single pathologist who was unaware of the biochemical and serological profiles of patients. Pathological evaluation was made using the METAVIR score on liver specimens from patients with AIH and using the Scheuer classification on those with PBC; specimens from patients suspected of AIH/PBC overlap syndrome were evaluated using both methods.

The number of acidophilic bodies was counted in a high-power field ($\times 400$), and graded high for ≥ 6 , middle for 2–5 and low for ≤ 1 per field.

Statistical analysis

Categorical and continuous variables were compared between groups using the two-tailed Mann-Whitney *U*-test. *P*-values <0.05 were considered significant.

RESULTS

Patients suspected of having the autoimmune hepatitis/primary biliary cirrhosis overlap syndrome

Of the 227 patients with autoimmune liver disease in Japan, 19 (8.4%) were diagnosed with the AIH/PBC overlap syndrome. Table 1 compares the features of the 19 patients with the overlap syndrome against those of the 52 patients with AIH as well as the 156 patients with PBC. Women predominated in the group with AIH/PBC overlap syndrome. Decrease in the transaminase levels occurred was greatest in the AIH group, followed by the overlap and the PBC groups, while immunoglobulin (Ig)M increased in the same order.

The biochemical, serological and histological profiles of the 19 patients with AIH/PBC overlap syndrome, along with the evolution of AMA in them, are shown in Table 2. Of these patients, seven (cases 2, 3, 7, 13, 15, 18 and 19), met the score for definite AIH (>15), and the remaining 12 for probable AIH (10–15). A ratio of alanine aminotransferase (ALT) over alkaline phosphatase (ALP) >3.0 was found in 10 patients (cases 1, 2, 5–8, 12–14 and 16). AMA persisted in six (cases 1–6), turned negative in 12 (cases 7–18) and became positive during follow up in the remaining one (case 19).

Table 1 Demographic, biochemical and immunological differences between patients with autoimmune hepatitis (AIH), primary biliary cirrhosis (PBC) and AIH/PBC overlap syndrome

Features	AIH (n = 52)	AIH/PBC overlap syndrome (n = 19)	PBC (n = 156)	Differences
Women (%)	34 (65)	18 (95)	128 (82)	NS
Age (years)†	52 (24–66)	50 (26–57)	54 (31–64)	NS
Aspartate aminotransferase (U/L)‡	72 (27–521)	65 (27–630)	40 (8–435)	<i>P</i> < 0.0001‡
Alanine aminotransferase (U/L)‡	86 (34–826)	82 (28–542)	34 (7–542)	<i>P</i> < 0.0001‡
Immunoglobulin G (mg/100 mL)‡	2146 (1456–4179)	2715 (2170–3623)	1638 (not known)	NS
Immunoglobulin M (mg/100 mL)‡	221 (not known)	302 (66–775)	444 (51–2018)	NS

†Median values are shown with ranges in parentheses. ‡Comparison between AIH and PBC as well as AIH/PBC overlap syndrome and PBC. NS, not significant.

Table 2 Demographic, biochemical and immunological profiles, and the evolution of antimitochondrial antibodies, in 19 patients with autoimmune hepatitis/primary biliary cirrhosis overlap syndrome

Case no.	Age/sex	AST (IU/L)	ALT (IU/L)	ALP (IU/L)	IgG (mg/100 mL)	IgM (mg/100 mL)	ANA titer	AIH score	AMA evolution
1	57M	56	71	502	2865	512	1280	10	+ → +
2	46F	33	38	196	2170	66	40	16	+ → +
3	46F	121	124	221	3623	408	1280	17	+ → +
4	61F	232	340	377	2054	296	1280	11	+ → +
5	36F	45	38	484	2789	280	320	14	+ → +
6	24F	38	58	295	3229	692	1280	14	+ → +
7	53F	45	60	321	2301	775	640	16	+ → -
8	41F	121	188	584	1893	1557	40	10	+ → -
9	60F	124	164	377	2120	227	160	11	+ → -
10	40F	678	958	717	2341	308	80	14	+ → -
11	62F	459	387	840	2950	366	1280	12	+ → -
12	41F	68	57	478	2120	366	320	12	+ → -
13	57F	38	42	273	2621	77	10240	16	+ → -
14	56F	61	98	395	2838	142	1280	13	+ → -
15	63F	84	103	196	4457	166	2560	19	+ → -
16	56F	78	84	755	2997	496	1280	14	+ → -
17	26F	46	79	184	2641	193	1280	13	+ → -
18	40F	58	61	128	4109	195	320	16	+ → -
19	50F	645	594	282	2623	692	160	16	- → +

AIH, autoimmune hepatitis; ALT, alanine aminotransferase; AMA, antimitochondria antibody; ANA, antinuclear antibody; AST, aspartic aminotransferase.

The patient with autoimmune hepatitis who developed antimitochondrial antibodies during follow up

Figure 1 shows fluctuating levels of ALT and aspartate aminotransferase, as well as ALP and γ -glutamyl transpeptidase (GTP), in a 50-year-old female patient with AIH who was followed for 17 years from 1983 when she was 51 years old. She was referred to Toranomon Hospital because of recurrent jaundice since 1981. Soon after the presentation, she came down with a severe bout of elevated transaminases without any changes in cholestatic enzymes. On the first liver biopsy

carried out in 1983, no bile duct lesions were observed, which would have excluded PBC (Fig. 2a,e). Because transaminases normalized spontaneously, no treatments were given to her at that time. Thereafter, she had a second severe bout of transaminases, this time accompanied by elevated ALP and γ -GTP levels. The second liver biopsy performed in 1984 revealed submassive necrosis in the liver along with scattered acidophilic bodies, indicative of a single-cell necrosis (Fig. 2b,f). A roughly uneven surface of the liver on laparoscopy also supported a diagnosis of AIH. Accordingly, this patient was started on prednisolone with tapering doses of 30–10 mg/day for maintaining normal levels of transami-

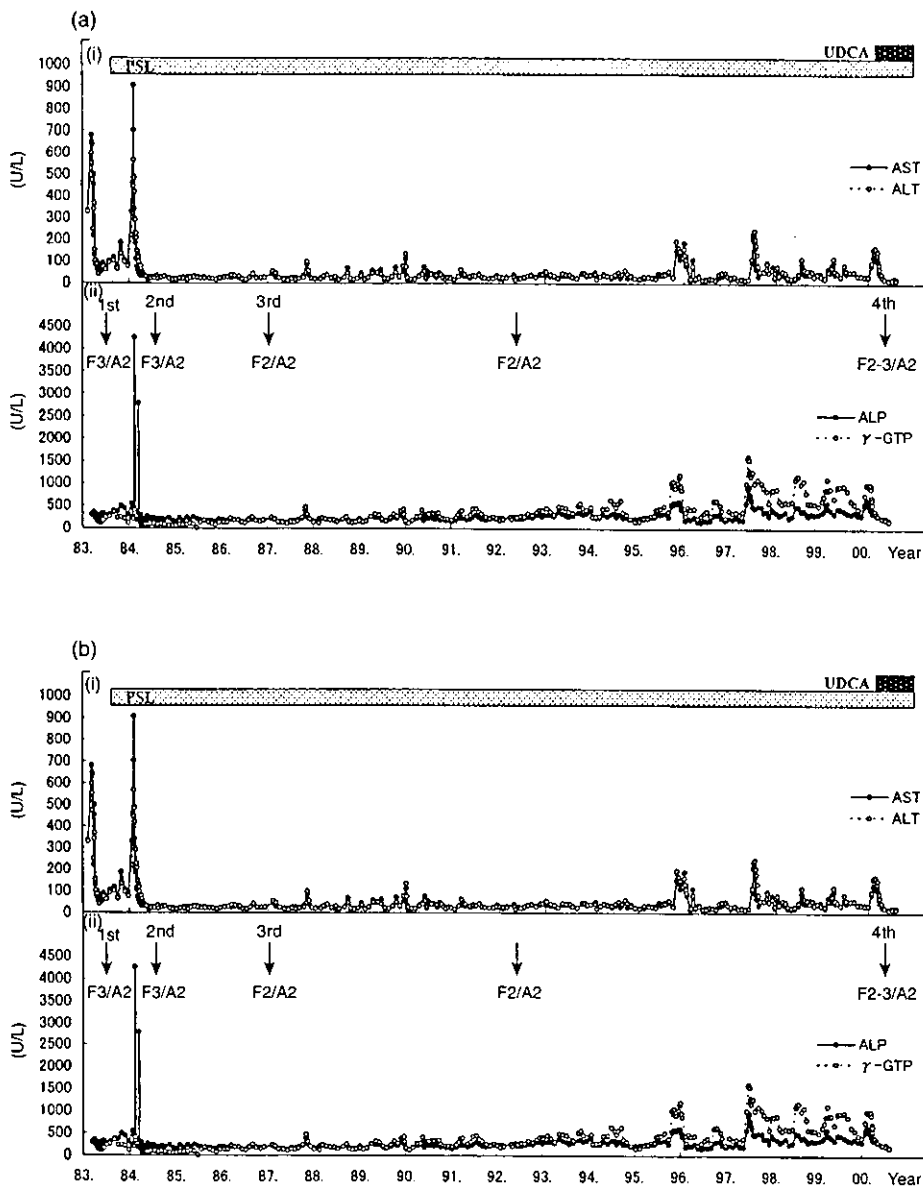


Figure 1 Clinical course of a patient with the autoimmune hepatitis/primary biliary cirrhosis overlap syndrome (case 19). Fluctuating levels of alanine aminotransferase and aspartate aminotransferase as well as alkaline phosphatase and γ -glutamyl transpeptidase are shown over 17 years of follow up. (a) Durations of prednisolone (PLS) and ursodeoxycholic acid (UDCA) administration and (b) the dates of four liver biopsies (see Figure 2).

nases and cholestatic enzymes during the 12 years thereafter.

The third biopsy carried out in 1987 indicated histological improvements with decreased fibrosis (Fig. 2c,g). Slightly elevated levels of cholestatic enzymes and transaminases emerged after 1996, and they gradually increased to form periodical bouts. Because the dose of prednisolone of 30 mg/day had no effect on liver enzymes, the patient received a fourth liver biopsy in 2000; it disclosed a full-blown histology of PBC with marked bile-duct lesions (Fig. 2d,h). The patient was found to be positive for AMA, and had elevated serum IgM levels; therefore UDCA 600 mg/day was commenced. Because UDCA was very efficient in decreasing levels of both transaminases and cholestatic enzymes, it was continued together with prednisolone in doses tapering down to a maintenance dose of 10 mg/day.

Histological characteristics of autoimmune hepatitis, autoimmune hepatitis/primary biliary cirrhosis overlap syndrome and primary biliary cirrhosis

Acidophilic bodies representing inflammation in lobules (Fig. 2b) in high-grade (≥ 6 per high-power field) or medium-grade (2–5 per field) were observed clearly more often in biopsied liver specimens from patients with AIH (39/46 [85%]) and AIH/PBC overlap syndrome (15/19 [79%]) than in PBC patients (3/85 [4%], $P < 0.001$). They were found in biopsied liver specimens from 12 of the 15 (80%) patients with a submassive necrosis and in those from three of the four (75%) without it. Hence, acidophilic bodies would sensitively reflect the inflammation in hepatocytes, and serve as a pathological marker of AIH.

Figure 2 Changes in the pathology with time in liver biopsies from a patient with the autoimmune hepatitis (AIH)/primary biliary cirrhosis (PBC) overlap syndrome (case 19). High-power and low-power magnifications are shown for four biopsy specimens taken at times indicated in Figure 1. (a,e) Typical histology of AIH is observed in the first biopsy without changes in bile ductules. Centrilobular inflammation with submassive necrosis is seen. (b,f) Fibrosis proceeded in the second biopsy, but bile ductules are kept intact. (c,g) Marked improvement in necroinflammation is observed after corticosteroid therapy in the third biopsy. Fibrosis is absorbed to some extent, but slight changes in bile ductules are seen. (d,h) Typical pathology of PBC in the portal area, without progression of fibrosis, is observed in the fourth biopsy.

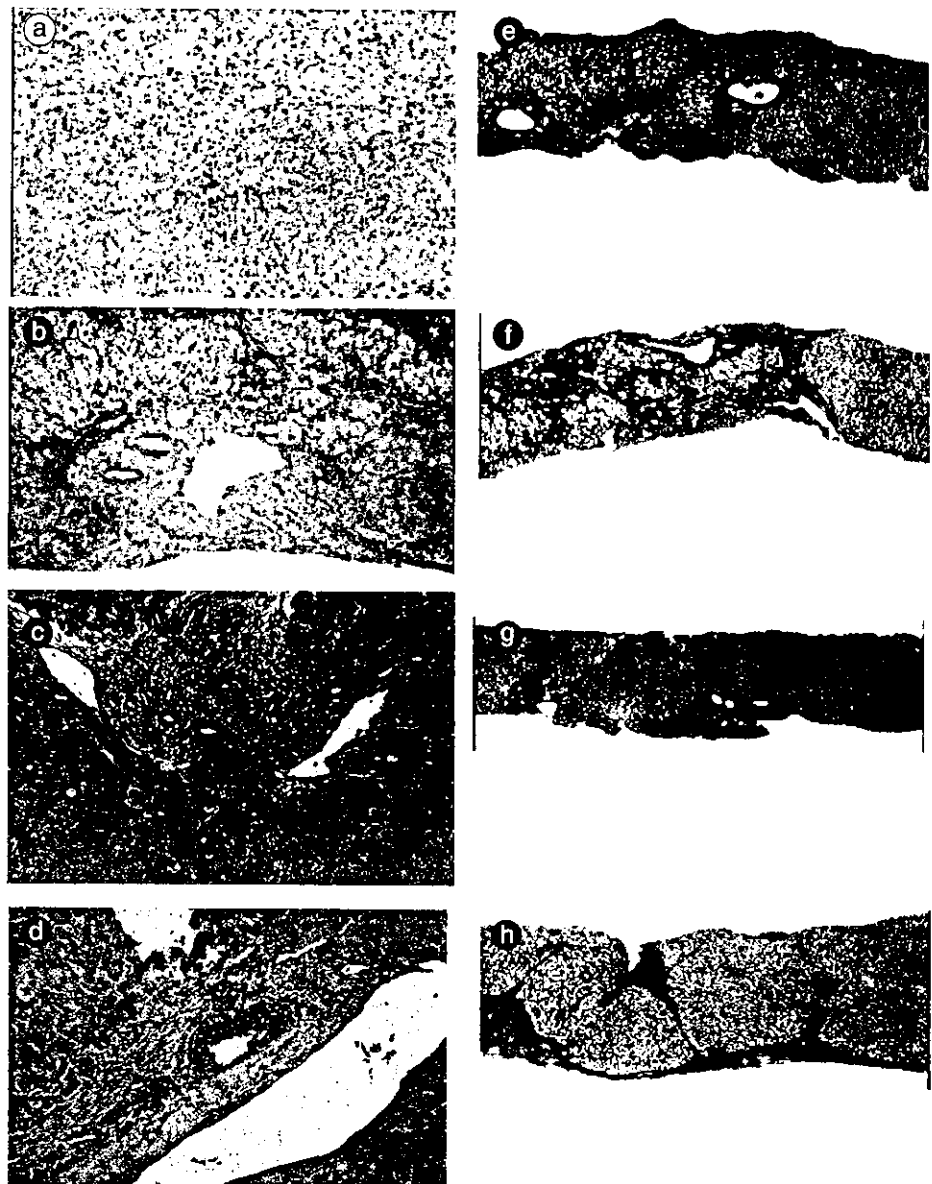


Table 3 summarizes the histological characteristics of 19 patients who were suspected of AIH/PBC overlap syndrome, along with treatments they received. Slight to moderate bile-duct lesions were observed in 12 (63%) of these patients. When acidophilic bodies were plotted against the localization of inflammation predominantly in periportal (P) or lobular (L) areas, however, they separated into two categories with a major pathology of either AIH or PBC (Fig. 3). Therapeutic responses in this group were in agreement with the pathology of either AIH or PBC, also. Strict AIH/PBC overlap syndrome was diagnosed clinically, histologically and therapeutically in only two of the 19 (11%) patients who were suspected of it (cases 5 and 19). These two patients accounted for <1% of the 227 patients with autoimmune liver disease in Tokyo, Japan.

DISCUSSION

Some patients with AIH have features of PBC, while those with PBC possess shades of AIH. The official name for this disease state with AIH and PBC combined is not declared as yet. A plethora of labels for this condition demonstrates the extent of the confusion. They include 'mixed types',^{7,21} 'overlap syndrome',²²⁻²⁴ 'immunocholangitis',²⁵ 'autoimmune cholangitis'²⁸ and 'autoimmune cholangiopathy',²⁶ as well as 'hepatic form of PBC' and 'cholestatic AIH', giving rise to concerns regarding the independence of AIH/PBC overlap syndrome from AIH or PBC. If AIH and PBC sit at opposite ends of the continuum of a single disease entity,²⁷ the mixture of the two with a dominance of one or the other is reasonably defined. AIH and PBC are very different in many respects, however, including epi-

Table 3 Histological findings and treatment of 19 patients with autoimmune hepatitis/primary biliary cirrhosis overlap syndrome

Case no.	Age/sex	Acidophilic bodies	Bile-duct lesion	Inflammation	Treatment
1	57M	-	Moderate	P > L	UDCA
2	46F	-	Slight	P > L	PSL
3	46F	-	Slight	P > L	PSL/UDCA
4	61F	+	-	P > L	UDCA
5	36F	+	Slight	P = L	PSL/UDCA
6	24F	+	Moderate	P < L	PSL
7	53F	-	Slight	P < L	PSL/UDCA
8	41F	+	-	P < L	PSL
9	60F	+	-	P < L	PSL
10	40F	+	Slight	P < L	PSL
11	62F	+	-	P < L	PSL
12	41F	+	-	P < L	PSL
13	57F	+	Moderate	P < L	PSL
14	56F	+	-	P < L	PSL
15	63F	+	Moderate	P < L	PSL
16	56F	+	Moderate	P = L	UDCA
17	26F	+	Moderate	P < L	PSL
18	40F	+	-	P < L	PSL
19	50F	+	Moderate	P < L	PSL/UDCA

L, lobular; P, portal; PSL, prednisolone; UDCA, ursodeoxycholic acid.

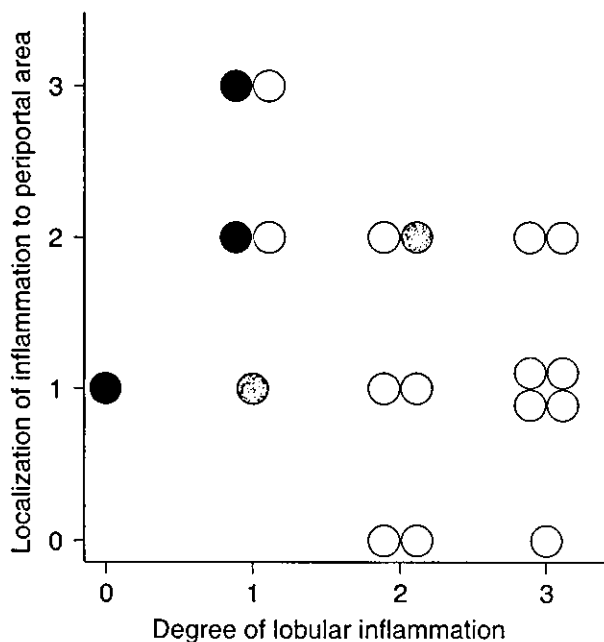


Figure 3 Different localizations of inflammation in relation to degree of inflammation. Findings in patients with (○) autoimmune hepatitis (AIH), (●) primary biliary cirrhosis (PBC) and (◐) AIH/PBC overlap syndrome are plotted.

demographical distribution, histological manifestation, biochemical and serological findings, as well as distinct therapeutic responses to either immunosuppression or choleretic agents.^{15,16} Although both AIH and PBC have robust immunological backgrounds, patterns of autoan-

tibodies are very different also, with ANA and ASMA predominant in AIH, in contrast to AMA, which is almost exclusive to PBC.⁴

Recently, the view that the AIH/PBC overlap syndrome represents a subgroup of PBC with characters resembling AIH has become increasingly popular. This is supported by the allowance of the presence of AMA in the context of AIH, in spite of this antibody having been considered integral to PBC.^{4,7,9,28,29} The favorable response of the patients with PBC to immunosuppressive therapies³⁰ appears to support this theory. Furthermore, the development of features that are characteristic of AIH has occurred only in the patients with PBC who have a genetic predisposition to AIH tagged by HLA markers.³¹

A few salient results emerged in the present study on 227 patients with autoimmune liver disease in Japan. Above all, the AIH/PBC overlap syndrome was not as rare and was found in 19 (2%) of these patients at presentation or during long-term follow up. However, even when it was suspected in patients with autoimmune liver disease, these patients had predominant features of either AIH or PBC. Moreover, the predominance waxed and waned with time. Thus, close clinical and pathological follow up would be required for diagnosing the 'true' AIH/PBC overlap syndrome.

Secondly, the genuine AIH/PBC overlap syndrome was very rare, being diagnosed in only two (0.8% of the total) patients, corresponding to 3.9% of the 52 with AIH and 1.3% of the 156 with PBC. Hence, even with the margin for AIH/PBC overlap syndrome set much narrower than before, the combination does seem to exist. The development of PBC in one patient with AIH was confirmed clinically, serologically and

pathologically, as was the response to therapy, in a female patient who was closely followed over 20 years (Figs 1,2).

Kloppel *et al.* found a histology mixed with that of PBC in seven of the 27 (26%) patients with AIH.²¹ They would not have been able to exclude the patients with PBC with severe necroinflammatory changes in the liver. Furthermore, chronic hepatitis C is not precluded from their cases. Chazouilleres *et al.* diagnosed overlap with AIH in 12 of 130 (9%) patients with PBC, one of whom developed AIH during the follow-up period.¹⁹ The histology of AIH was detected in 10 of these patients, including two without AMA in serum. Czaja found a variant type with AIH and PBC combined in 15 of 227 (7%) patients with autoimmune liver disease, including 162 with AIH, 37 with PBC and 26 with primary sclerosing cholangitis.¹⁷ Histology in the liver was not provided for these patients. Lohse *et al.* compared 20 cases each of AIH/PBC overlap, AIH and PBC.³¹ The diagnosis of AIH/PBC overlap was made clinically in 14 and histologically in six. Taken along with these reported cases, the two Japanese patients in this study would support the clinical entity of 'true' AIH/PBC overlap syndrome, albeit it is rare.

In view of a low prevalence of AIH or PBC in Japan,³ the co-occurrence of AIH and PBC in Japanese patients would be taken much the more seriously as evidence for the AIH/PBC overlap syndrome. In a survey conducted by the Japanese Ministry of Health, Labor and Welfare in 2000, there were only 590 registrations of AIH and 4361 registrations of PBC. Prevalence rates of AIH and PBC in Japan are reported to be 0.00–0.15 and 0.34–0.42 per 100 000 population, respectively, in Japan;³² rates lower than those in Sweden (17 for both AIH and PBC).³³ Likewise, the incidence rates of AIH and PBC in Japan are 0.0005 and 0.0040 per 100 000 population per year in comparison with 0.1–1.2 and 0.4, respectively, in 10 European countries.³⁴

Given the lack of a 'gold ruler' for drawing the line between AIH and PBC, the virtue of close and meticulous histological examination cannot be overemphasized. Caution should be exercised, particularly for PBC that presents with characteristic granulomatous changes and bile-duct lesions. Some patients with AIH, particularly those with severe inflammatory changes that involve bile ducts, can display a histological picture hardly distinguishable from that of PBC. Moreover, the examination of serial liver sections, as was performed in the present study, may pick up more traits of bile-duct lesions in liver specimens biopsied from patients with AIH.

Distribution of inflammation and emergence of acidophilic bodies have emerged as characteristic histological changes in AIH. Unlike AIH and viral hepatitis that are induced by cytotoxic T-cell responses directed to hepatocytes, the target of immune attack is focused on bile-duct epithelia in PBC. In addition, the vigor of immune responses seems very different between the two diseases. AIH can be controlled only by immunosuppressive therapies such as prednisolone and azathioprine, while PBC may be treated using UDCA that has moderate immunomodulatory activity in addition to choleric action.

Acidophilic bodies decreased in number in liver specimens from patients with AIH in our series as the treatment took effects, in parallel with the amelioration of biochemical and histological signs of inflammation in the liver. Because the cases of AIH/PBC overlap syndrome with predominant acidophilic bodies at the first biopsy evolved into AIH at a later stage, they would be of help for an early diagnosis. It needs to be noted that the localization of inflammation at the site of immune attacks was different between patients with AIH and PBC. When inflammation is severe, both periportal and lobular areas are involved. This makes it difficult to differentiate the site of immune attacks from surrounding areas that are affected inevitably but secondarily. As the inflammation is put under control by treatment, however, the predominance of either AIH or PBC will unfold. AMA tested positive at least once during the clinical course in 19 patients who were suspected of AIH/PBC overlap syndrome. It disappeared, however, in 13 of these patients, including 12 with acidophilic bodies in lobules of liver specimens biopsied for an early diagnosis of AIH. They all responded well to prednisolone.

As Mann *et al.* rightfully state,^{2,18} the need for closely following each patient is not to be overemphasized. This is highlighted in the typical case of an AIH patient who developed PBC during follow up for 17 years in the present study. Serial liver biopsies performed on this patient identified bile-duct lesions promptly, and allowed an immediate institution of UDCA therapy. Not included in the present study, a very similar case was experienced who developed the AIH/PBC overlap syndrome during a follow-up period of 10 years (Y Suzuki, unpubl. obs., 1989–1999).

In conclusion, although infrequent, the 'real' AIH/PBC overlap syndrome does exist among patients with autoimmune liver disease in Japan. Most patients who were suspected of AIH/PBC overlap syndrome at the first presentation, however, evolved into either AIH or PBC during long-term follow up. In contrast, patients who present with either AIH or PBC can develop the other, leading to the diagnosis of the authentic overlap syndrome in the long run. It is the responsibility of attending doctors not to miss these changes by repeating liver biopsies on laparoscopy as required, for commencing efficient and timely medical intervention. After all, diagnosis of the 'real' AIH/PBC overlap syndrome, as well as differentiation of AIH from PBC or the other way around, would not be accomplished by simple assessment of serological and histological manifestation at a single time point. Careful adjustment of examination and therapy, case by case in patients closely followed for a long period, would not only lessen the burden of morbidity in these patients, but also help comprehend and define the 'real' AIH/PBC overlap syndrome.

REFERENCES

- 1 Johnson PJ, McFarlane IG. Meeting report: International Autoimmune Hepatitis Group. *Hepatology* 1993; 18: 998–1005.

- 2 Alvarez F, Berg PA, Bianchi FB *et al.* International Autoimmune Hepatitis Group Report: review of criteria for diagnosis of autoimmune hepatitis. *J. Hepatol.* 1999; 31: 929–38.
- 3 Toda G, Zeniya M, Watanabe F *et al.* Present status of autoimmune hepatitis in Japan – correlating the characteristics with international criteria in an area with a high rate of HCV infection. Japanese National Study Group of Autoimmune Hepatitis. *J. Hepatol.* 1997; 26: 1207–12.
- 4 Munoz LE, Thomas HC, Scheuer PJ, Doniach D, Sherlock S. Is mitochondrial antibody diagnostic of primary biliary cirrhosis? *Gut* 1981; 22: 136–40.
- 5 Gershwin ME, Coppel RL, Mackay IR. Primary biliary cirrhosis and mitochondrial autoantigens – insights from molecular biology. *Hepatology* 1988; 8: 147–51.
- 6 Van de Water J, Cooper A, Surh CD *et al.* Detection of autoantibodies to recombinant mitochondrial proteins in patients with primary biliary cirrhosis. *N. Engl. J. Med.* 1989; 320: 1377–80.
- 7 Goodman ZD, McNally PR, Davis DR, Ishak KG. Autoimmune cholangitis: a variant of primary biliary cirrhosis. Clinicopathologic and serologic correlations in 200 cases. *Dig. Dis. Sci.* 1995; 40: 1232–42.
- 8 Michieletti P, Wanless IR, Katz A *et al.* Antimitochondrial antibody negative primary biliary cirrhosis: a distinct syndrome of autoimmune cholangitis. *Gut* 1994; 35: 260–5.
- 9 Kim WR, Poterucha JJ, Jorgensen RA *et al.* Does antimitochondrial antibody status affect response to treatment in patients with primary biliary cirrhosis? Outcomes of ursodeoxycholic acid therapy and liver transplantation. *Hepatology* 1997; 26: 22–6.
- 10 Kinoshita H, Omagari K, Whittingham S *et al.* Autoimmune cholangitis and primary biliary cirrhosis – an autoimmune enigma. *Liver* 1999; 19: 122–8.
- 11 Klatskin G, Kantor FS. Mitochondrial antibody in primary biliary cirrhosis and other diseases. *Ann. Intern. Med.* 1972; 77: 533–41.
- 12 Geubel AP, Baggenstoss AH, Summerskill WH. Responses to treatment can differentiate chronic active liver disease with cholangitic features from the primary biliary cirrhosis syndrome. *Gastroenterology* 1976; 71: 444–9.
- 13 Kenny RP, Czaja AJ, Ludwig J, Dickson ER. Frequency and significance of antimitochondrial antibodies in severe chronic active hepatitis. *Dig. Dis. Sci.* 1986; 31: 705–11.
- 14 Shouval D, Eliakim M, Levij IS. Chronic active hepatitis with cholestatic features. II. A histopathological study. *Am. J. Gastroenterol.* 1979; 72: 551–5.
- 15 Kaplan MM. Primary biliary cirrhosis. *N. Engl. J. Med.* 1996; 335: 1570–80.
- 16 Krawitt EL. Autoimmune hepatitis. *N. Engl. J. Med.* 1996; 334: 897–903.
- 17 Czaja AJ. Frequency and nature of the variant syndromes of autoimmune liver disease. *Hepatology* 1998; 28: 360–5.
- 18 Davis PA, Leung P, Manns M *et al.* M4 and M9 antibodies in the overlap syndrome of primary biliary cirrhosis and chronic active hepatitis: epitopes or epiphenomena? *Hepatology* 1992; 16: 1128–36.
- 19 Chazouilleres O, Wendum D, Serfaty L, Montembault S, Rosmorduc O, Poupon R. Primary biliary cirrhosis – autoimmune hepatitis overlap syndrome: clinical features and response to therapy. *Hepatology* 1998; 28: 296–301.
- 20 Mackay IR, Gershwin ME. Primary biliary cirrhosis: current knowledge, perspectives, and future directions. *Semin. Liver Dis.* 1989; 9: 149–57.
- 21 Kloppel G, Seifert G, Lindner H, Dammermann R, Sack HJ, Berg PA. Histopathological features in mixed types of chronic aggressive hepatitis and primary biliary cirrhosis. Correlations of liver histology with mitochondrial antibodies of different specificity. *Virchows Arch. A. Pathol. Anat. Histol.* 1977; 373: 143–60.
- 22 Duclos-Vallee JC, Hadengue A, Ganne-Carrie N, Robin E, Degott C, Erlinger S. Primary biliary cirrhosis – autoimmune hepatitis overlap syndrome. Corticoreistance and effective treatment by cyclosporine A. *Dig. Dis. Sci.* 1995; 40: 1069–73.
- 23 Perrillo RP, Mason AL, Jacob S, Gerber MA. Hepatitis and cholestasis in a middle-aged woman. *Hepatology* 1996; 24: 730–4.
- 24 Czaja AJ. The variant forms of autoimmune hepatitis. *Ann. Intern. Med.* 1996; 125: 588–98.
- 25 Brunner G, Klinge O. A cholangitis with antinuclear antibodies (immunocholangitis) resembling chronic non-suppurative destructive cholangitis. *Dtsch. Med. Wochenschr.* 1987; 112: 1454–8.
- 26 Ben-Ari Z, Dhillon AP, Sherlock S. Autoimmune cholangiopathy: part of the spectrum of autoimmune chronic active hepatitis. *Hepatology* 1993; 18: 10–15.
- 27 Doniach D, Walker JG. A unified concept of autoimmune hepatitis. *Lancet* 1969; 1: 813–15.
- 28 Boberg KM, Fausa O, Haaland T *et al.* Features of autoimmune hepatitis in primary sclerosing cholangitis: an evaluation of 114 primary sclerosing cholangitis patients according to a scoring system for the diagnosis of autoimmune hepatitis. *Hepatology* 1996; 23: 1369–76.
- 29 Invernizzi P, Crosignani A, Battezzati PM *et al.* Comparison of the clinical features and clinical course of antimitochondrial antibody-positive and – negative primary biliary cirrhosis. *Hepatology* 1997; 25: 1090–5.
- 30 Mitchison HC, Palmer JM, Bassendine MF, Watson AJ, Record CO, James OF. A controlled trial of prednisolone treatment in primary biliary cirrhosis. Three-year results. *J. Hepatol.* 1992; 15: 336–44.
- 31 Lohse AW, zum Buschenfelde KH, Franz B, Kanzler S, Gerken G, Dienes HP. Characterization of the overlap syndrome of primary biliary cirrhosis (PBC) and autoimmune hepatitis. evidence for it being a hepatic form of PBC in genetically susceptible individuals. *Hepatology* 1999; 29: 1078–84.
- 32 Nishioka M, Morshed SA, McFarlane IG *et al.* Geographical variation in the frequency and characteristics of autoimmune liver diseases. In: Krawitt EL, Wiesner RH, Nishioka M, eds. *Autoimmune Liver Diseases*, 2nd edn. Amsterdam: Elsevier Science, 1998; 413–24.
- 33 Boberg KM, Aadland E, Jahnsen J, Raknerud N, Stiris M, Bell H. Incidence and prevalence of primary biliary cirrhosis, primary sclerosing cholangitis, and autoimmune hepatitis in a Norwegian population. *Scand. J. Gastroenterol.* 1998; 33: 99–103.
- 34 Triger DR, Berg PA, Rodes J. Epidemiology of primary biliary cirrhosis. *Liver* 1984; 4: 195–200.

Wild-type Precore and Core Promoter Sequences in Patients with Acute Self-limited or Chronic Hepatitis B

M. Kobayashi, Y. Arase, K. Ikeda, A. Tsubota, Y. Suzuki, S. Saitoh, M. Kobayashi, F. Suzuki, N. Akuta, T. Hosaka, T. Someya, M. Matsuda, J. Sato, Y. Miyakawa & H. Kumada
Research Institute for Hepatology and Dept. of Gastroenterology, Toranomon Hospital, Tokyo, Japan; Miyakawa Memorial Research Foundation, Tokyo, Japan

Kobayashi M, Arase Y, Ikeda K, Tsubota A, Suzuki Y, Saitoh S, Kobayashi M, Suzuki F, Akuta N, Hosaka T, Someya T, Matsuda M, Sato J, Miyakawa Y, Kumada H. Wild-type precore and core promoter sequences in patients with acute self-limited or chronic hepatitis B. *Scand J Gastroenterol* 2004;39:53–59.

Background: Mutations in the precore region and core promoter were compared between patients with acute and chronic hepatitis B. **Methods:** There were 69 patients with acute self-limited hepatitis B and 210 with chronic hepatitis B who had been followed for >15 years. The hepatitis B virus (HBV) of genotypes A, B and C was detected in 14 (23%), 8 (13%) and 28 (45%) of the patients with acute self-limited hepatitis, respectively, in contrast to 11 (5%), 25 (12%) and 167 (80%) of those with chronic hepatitis. **Results:** At presentation, hepatitis B e antigen (HBeAg) in serum was the more common (82% versus 65%, $P < 0.05$), and the wild-type sequences of the precore region (100% versus 74%, $P < 0.001$) and core promoter (88% versus 36%, $P < 0.00001$) were more frequent in the 50 patients with acute self-limited hepatitis than the 203 patients with chronic hepatitis B who were infected with HBV of genotype A, B or C. Wild-types of both the precore region and core promoter persisted in acute self-limited hepatitis, while they decreased from 28% to 10% in chronic hepatitis over the course of >15 years. **Conclusion:** HBV with the wild-type sequences of the precore region and core promoter prevails in patients with acute self-limited hepatitis, unlike in patients with chronic hepatitis.

Key words: Hepatitis B e antigen; hepatitis B surface antigen; hepatitis B virus; hepatocellular carcinoma; genotypes

Mariko Kobayashi, B.S., Dept. of Gastroenterology, Toranomon Hospital, 1-3-1, Kajigaya, Takatsu-ku, Kawasaki City 213-8587, Japan (fax. +81 44 860 1623, e-mail. vj7m-kbys@asahi-net.or.jp)

Of two billion people in the world exposed to the hepatitis B virus (HBV), it is estimated that 350 million are infected with it persistently (1). In regions highly endemic for HBV, such as Asia and Africa, the persistent carrier state is established by perinatal transmission or early in infancy. Carriers serve as the reservoir of HBV in the community, and can spread the infection to susceptible individuals. Before hepatitis B surface antigen (HBsAg) was identified as the marker of HBV infection in the early 1970s, transmission in adulthood occurred through transfusions and inappropriate medical practices. Transmission now takes place through promiscuous sexual contact and through the sharing of needles and syringes for injection of illicit intravenous drugs.

The wild-type HBV can direct the synthesis of hepatitis B e antigen (HBeAg) in hepatocytes. The production of HBeAg is abolished by mutations in the precore region that prohibit the translation of HBeAg precursor (2, 3) and is reduced by mutations in the core promoter that down-regulate the transcription of precore RNA for the HBeAg precursor (4, 5). The ability of HBV to encode HBeAg is crucial in

persistence of infection as well as pathogenesis of chronic hepatitis B.

Mutations in the precore region and core promoter were compared between 50 patients with acute self-limited hepatitis B and 203 patients with chronic hepatitis B, all of whom were infected with HBV genotype A, B or C, and their clinical course was followed in a city hospital in Tokyo. The results highlighted markedly different virological characters of HBV, in terms of its ability to encode HBeAg, between acute self-limited and chronic hepatitis B.

Patients and Methods

Patients

In the period from 1971 to 1986, 69 patients with acute self-limited hepatitis B (62 M, 7 F; median age 32 years (range 19–63 years)) visited the Dept. of Gastroenterology at Toranomon Hospital in Metropolitan Tokyo. They had serum HBsAg and antibody to hepatitis B core antigen (anti-HBc) of IgM class in high titres for the diagnosis of acute hepatitis B. HBV infection resolved with the loss of HBsAg from serum in

62 (90%) within 6 months of admission. There were 210 patients with chronic hepatitis B who visited the same hospital during the 15 years (1971–86) and had been followed for 15 years or longer. Serum samples were collected from patients at regular intervals from the day of admission and were stored at -80°C until virological tests. Fifty of the 69 (72%) patients with acute self-limited hepatitis and the 203 of the 210 (97%) with chronic hepatitis, who were infected with HBV genotype of A, B or C, were compared for serum HBeAg as well as mutations in precore region and core promoter in HBV DNA samples recovered from their sera. The study design conformed to the 1975 Declaration of Helsinki, and was approved by the Ethics Committee of Toranomon Hospital. Each patient gave written informed consent on the purpose of this study.

Serum markers of HBV infection

HBsAg was determined with commercial kits by haemagglutination (MyCell, Institute of Immunology Co., Ltd., Tokyo, Japan) and radioimmunoassay (AUSRIA II-125, Dinabot, Tokyo, Japan), and IgM anti-HBc was tested by enzyme-linked immunosorbent assay (ELISA) with commercial kits (HBc-antiM RIA; Dinabot). HBeAg was determined by ELISA (ELISA, F-HBe; Kokusai Diagnostic, Kobe, Japan). Serotypes of HBsAg were determined by ELISA with commercial kits (HBs Antigen Subtype EIA, Institute of Immunology). The six major genotypes of HBV (A–E) were determined by ELISA with commercial kits (HBV Genotype EIA, Institute of Immunology) after the method of Usuda et al. (6, 7). This involves the expression of preS2 epitopes, detected by monoclonal antibodies, the combination of which is specific for each of the six HBV genotypes. Genotype G, which was discovered recently (8), was determined by the combination of preS2 serotype for genotype D and HBsAg subtype of *adv*; it is specific for this genotype (9). HBV DNA was determined by transcription-mediated amplification and hybridization-protection assay (Chugai Diagnostics, Tokyo, Japan), and the results were expressed as log genome equivalents (LGE) per millilitre. The lower detection limit of this assay is 3.7 LGE/mL, which is equivalent to 5,000 copies/mL.

Nucleotide sequences of the precore region and core promoter

Nucleic acids were extracted from serum with a Smitest EX & R kit (Genome Science, Tokyo, Japan). For determination of the wild-type or mutants in the precore region, they were amplified by polymerase chain reaction (PCR) with nested primers. The first-round PCR was performed with BCP-F7 (sense, 5'-TGC ACT TCG CTT CAC CTC TG-3' (nucleotides (nt) 1580–1599)) and BCP-R8 (antisense, 5'-TAA GCG GGA GGA GTG CGA AT-3' (nt 2295–2276)) primers, and the second-round PCR with BCP-F5 (sense, 5'-GCA TGG AAC CAC CGT GAA C-3' (nt 1606–1625)) and BCP-R6 (antisense, 5'-ATA CAG AGC AGA GGC GGT AT-3' (nt 2014–

1995)) for 35 cycles each (94°C , 1 min (5 min in the first cycle); 53°C , 2 min; and 72°C , 3 min (7 min in the last cycle)). The amplification products were run on gel electrophoresis and stained with BIG Dye (Applied Biosystems, Calif., USA). Amplification products were isolated with the QIAquick PCR purification kit (Qiagen, Hilden, Germany), and then sequenced in ABI Prism 310 Genetic Analyzer (Applied Biosystems). Mutations interfering with the translation or transcription of HBeAg were sought in the precore region and core promoter. These included a G-to-A mutation at nt 1896 in the precore region (A1896) and the double mutation in the core promoter converting nt 1762 from A to T as well as nt 1764 from G to A (T1762/A1764). Also examined was nt 1858 of T or C in the precore region sequence.

Statistical analyses

Categorical data were compared between groups using the chi-squared test as well as the Fisher exact test, and non-categorical data using the Mann-Whitney *U* test. Data analysis was performed using the SAS computer program (10), and *P* values less than 0.05 were considered significant.

Results

Patients with acute self-limited and chronic hepatitis B

Among the 69 patients with acute self-limited hepatitis B, HBV genotypes were A in 14 (23%), B in 8 (13%) and C in 28 (45%). Of the 50 (72% of the total) patients infected with HBV of genotype A, B or C (median age 33 years), 48 were men (96%). Extramarital sexual contacts were reported by 27 (54%). Family members with liver diseases were recognized in 3 (6%), all of whom were wives. Serum HBeAg was detected in 41 (82%) and 4 (8%) had lost HBsAg from serum already at presentation.

The baseline characteristics of patients with acute self-limited hepatitis B who were infected with HBV genotype A, B or C are compared in Table 1. HBsAg subtypes were mostly *adv* in patients infected with HBV genotype A or B in contrast to *adr* frequent in those with HBV genotype C. There were no significant differences in demographic and virological characteristics among the patients infected with HBV genotypes A, B and C.

Of the 210 patients with chronic hepatitis B who visited the same hospital and had been followed for >15 years, 203 (97%) were infected with HBV of genotypes A (11 (5%)), B (25 (12%)) or C (167 (82%)). The frequency of genotype A was lower in chronic than in acute self-limited hepatitis B (5% versus 23%, $P < 0.001$). The 203 patients had a median age of 35 years (range 12–66), and there were 166 (82%) males. At least one family member with liver disease was found in 125 in a frequency significantly higher than that in patients with acute self-limited hepatitis B (62% versus 6%, $P < 0.0001$). HBeAg was detected in sera from 131 of them at presentation, significantly less frequently than in patients with acute self-

Table I. Baseline characteristics of patients with acute self-limited hepatitis B

Features	Genotype A (n = 14)	Genotype B (n = 8)	Genotype C (n = 28)
Age (years)*	32 (25–56)	35 (24–55)	32 (19–63)
Male	14 (100%)	8 (100%)	21 (75%)
Infection routes			
Heterosexual	9 (64%)	3 (37%)	18 (64%)
Homosexual	2 (14%)	0	0
Needlestick	0	1 (13%)	1 (4%)
Unknown	3 (22%)	4 (50%)	9 (32%)
Bilirubin (mg/dl)*	7.7 (0.8–17.3)	9.6 (1.2–26.3)	7.7 (0.6–15.9)
ALT (IU/l)*	1896 (968–3300)	1185 (1026–4484)	1983 (670–4056)
HBeAg	13 (93%)	6 (75%)	22 (79%)
HBsAg subtypes			
<i>adw</i>	13 (93%)	7 (88%)	5 (18%)
<i>adr</i>	0	0	22 (79%)
<i>adwr</i>	0	0	1 (4%)
Untypeable	1 (7%)	1 (13%)	0
HBV DNA (LGE†/ml)*	8.5 (<3.7–>8.7)	2.4 (<3.7–5.0)	3.5 (<3.7–>8.7)

*Median values are given with the range in parentheses.

†Log geometric equivalents determined by transcription-mediated amplification and hybridization-protection assay.

limited hepatitis B who were infected with HBV of genotype A, B or C (65% versus 82%, $P < 0.05$).

Baseline characteristics are compared among patients with chronic hepatitis who were infected with HBV genotype A, B or C (Table II). HBeAg was detected at presentation in patients infected with HBV genotype B less frequently than in patients with genotype A or C ($P = 0.018$). HBsAg genotype was predominantly *adw* in patients infected with HBV genotype A or B, while it was frequently *adr* in those with genotype C. HBV DNA levels at presentation were significantly lower in patients infected with HBV genotype B than in those with genotype A or C ($P = 0.001$).

Wild-type sequences of the precore region and core promoter at the presentation of patients with acute self-limited or chronic hepatitis B

Nucleotide sequences of the precore region and core

promoter were determined on HBV DNA samples from patients at presentation. Wild-type sequences of the precore region and core promoter that regulate the synthesis of HBeAg were examined and compared between patients with acute self-limited and chronic hepatitis B.

Wild-type sequences of the precore region (43/43 or 100% versus 150/203 or 74%, $P < 0.001$) and core promoter (38/43 88% versus 73/203 or 36%, $P < 0.0001$) were detected significantly more frequently in patients with acute self-limited than chronic hepatitis B, in agreement with HBeAg, which was more frequent in the former than in the latter (Fig. 1). There was no appreciable influence of HBV genotypes on the wild-type sequence of the precore region or core promoter in patients with acute self-limited hepatitis B (Table III). The wild-type sequences of both the precore region and core promoter had persisted until they resolved HBV infection with the loss of HBsAg.

Table II. Baseline characteristics of patients with chronic hepatitis B

Features	Genotype A (n = 11)	Genotype B (n = 25)	Genotype C (n = 167)
Age (years)*	28 (12–55)	39 (25–56)	35 (15–66)
Men	10 (90%)	21 (84%)	135 (81%)
Liver fibrosis*			
F1	7 (64%)	22 (88%)	105 (63%)
F2	4 (36%)	3 (12%)	62 (37%)
HBeAg	8 (73%)	8 (32%)	114 (66%)
HBsAg subtypes			
<i>adw</i>	11 (100%)	24 (96%)	2 (1%)
<i>adr</i>	0	0	138 (83%)
<i>ayr</i>	0	0	2 (1%)
<i>adwr</i>	0	0	23 (14%)
<i>adyr</i>	0	0	2 (1%)
Untypeable	0	1 (4%)	0
HBV DNA (LGE†/ml)*	8.6 (<3.7–> 8.7)	6.9 (<3.7–> 8.7)	7.5 (<3.7–> 8.7)

*Median values are given with the range in parentheses.

†Log geometric equivalents determined by transcription-mediated amplification and hybridization-protection assay.

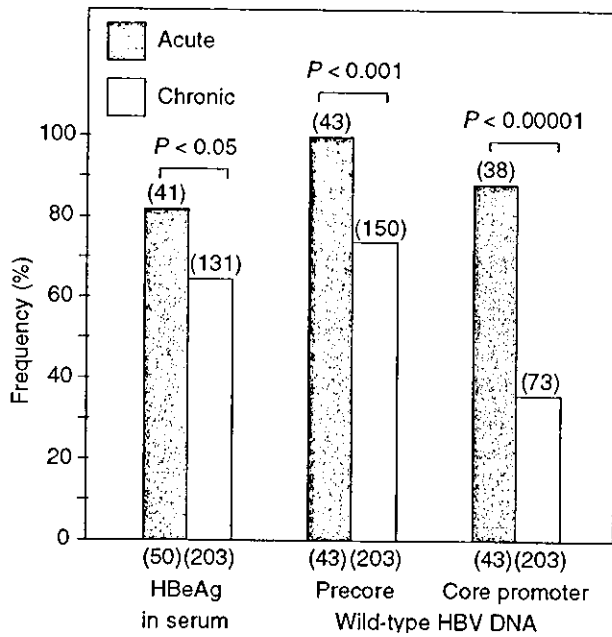


Fig. 1. Prevalence rates of serum HBeAg as well as the wild-type sequences of the precore region and core promoter in HBV DNA samples from patients with acute self-limited or chronic hepatitis B.

In patients with chronic hepatitis B, however, HBV genotypes had an influence on the prevalence of wild-type precore and core promoter sequences (Table IV). At presentation, genotype B infection accompanied the less frequent wild-type precore sequence than genotypes A ($P < 0.01$) or C ($P < 0.05$), as well as the more common wild-type sequence of the core promoter than genotypes A ($P < 0.05$) or C ($P < 0.001$) infection. After >15 years of follow-up, the wild-type precore region was more frequent in patients infected with HBV genotype A than B ($P < 0.001$) or

C ($P < 0.001$), and the wild-type core promoter was more common in patients with genotype B than C ($P < 0.001$) infection. The 1858th nucleotide making a pair with nt 1896 of G in the wild-type, or A in precore mutants, was T in all HBV isolates from patients infected with HBV genotype B or C; it was C in all patients infected with HBV genotype A.

Fig. 2 compares the distribution of mutations in the precore region and core promoter between patients with acute self-limited and chronic hepatitis B at presentation. Patients with chronic hepatitis B were classified into two groups by the presence or absence of serum HBeAg at presentation. Wild-type sequences in the precore region and core promoter were detected in 88% of the patients with acute self-limited hepatitis B, significantly more frequently than in 36% of patients with chronic hepatitis B with HBeAg ($P < 0.0001$) or in 13% of those without HBeAg at presentation ($P < 0.0001$). Among the patients with chronic hepatitis B, wild-type sequences in the precore region and core promoter were more frequent (36% versus 13%, $P < 0.01$), and mutations in the precore region and core promoter were more common in those with HBeAg than in those without (51% versus 36%, $P < 0.01$) at presentation.

Precore and core promoter mutations increasing in patients with chronic hepatitis B infected with HBV genotype B or C during the course of >15 years

Nucleotide sequences of the precore region and core promoter were compared in patients with chronic hepatitis B at presentation and after follow-ups >15 years (Fig. 3). Overall, mutations in the precore region increased from 54% to 65% and those in core promoter from 64% to 83% during 15 years or longer. There were marked decreases in prevalence of the wild-type precore region (more than 35%) and core promoter (more than 16%) during >15 years in the patients infected with HBV of genotype B or C (Table III). In

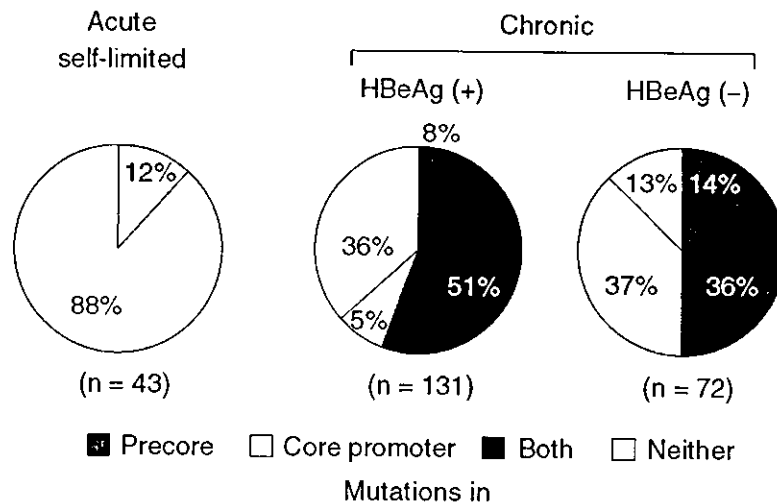


Fig. 2. Distribution of mutations in the precore region and core promoter in HBV DNA samples from patients with acute self-limited or chronic hepatitis B at presentation.

(a) At the presentation (b) After the loss of HBsAg or follow-up > 15 years

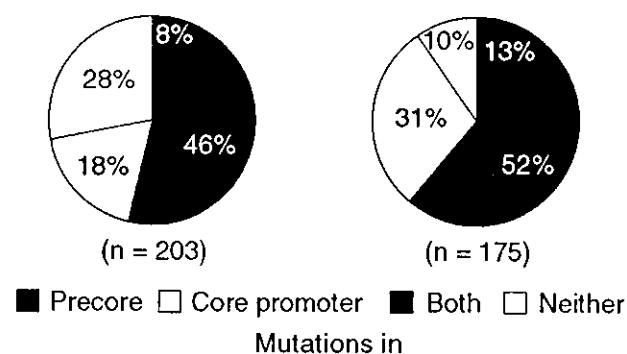


Fig. 3. Changes in mutations of the precore region and core promoter in HBV DNA samples from patients with chronic hepatitis B from presentation until they lost HBsAg or after follow-ups >15

Table III. Wild-type sequences of the precore region and core promoter in patients with acute self-limited hepatitis B who were infected with HBV of genotype A, B or C

Time and genotypes	Wild-type	
	Precore region	Core promoter
At the presentation		
Genotype A (n = 11)	11 (100%)	10 (91%)
Genotype B (n = 5)	5 (100%)	5 (100%)
Genotype C (n = 27)	27 (100%)	23 (85%)
Total (n = 43)	43 (100%)	38 (88%)
At the loss of HBsAg		
Genotype A (n = 4)	4 (100%)	4 (100%)
Genotype B (n = 1)	1 (100%)	0 (0%)
Genotype C (n = 15)	15 (100%)	13 (87%)
Total (n = 20)	20 (100%)	17 (85%)

the 11 patients infected with HBV genotype A, by contrast, precore mutations did not increase at all, while mutations in the core promoter increased by only 9%.

Discussion

In Japan, the HBV carrier state has been established most

frequently through perinatal transmission from infected mothers with serum HBeAg to their babies (11, 12). In 1986, the national programme was implemented for protecting babies born to HBeAg-positive mothers with a combined passive and active immunization by hepatitis B immune globulin and vaccine. The indication for immunoprophylaxis was extended to babies born to carrier mothers without serum HBeAg in 1995. Consequently the prevalence of HBsAg in children has decreased from 2% to less than 0.1% in the past 15 years. Transmission of HBV by transfusions has decreased markedly since screening for HBsAg started in 1972 and even further after tests for anti-HBc began in 1986 and for HBV DNA by nucleic acid technology (NAT) in 2000.

Suspected transmission routes in the 50 patients with acute self-limited hepatitis infected with HBV of genotype A, B or C, disclosed the current inclination of adults who acquire HBV infection in Japan. Extramarital sexual contacts accounted for HBV infection in 54%. Family members with liver disease, by contrast, were less frequent in the case of patients with acute self-limited hepatitis B than in those with chronic hepatitis B (62% versus 6%, *P* < 0.0001). Of the three major genotypes in Japan (A, B and C), genotype A was significantly more frequent in patients with acute self-limited than chronic hepatitis B (28% versus 6%, *P* < 0.001), confirming our previous report (13) and that of others (14). HBV genotype A is rare in Japan, and it would therefore have spread mostly by contacts with professional sex workers from abroad.

The 50 patients with acute self-limited hepatitis and the 203 with chronic hepatitis B, for whom sequencing of HBV DNA was feasible, were compared for serum HBeAg as well as for mutations in the precore region and core promoter; they were all infected with HBV of genotype A, B or C. HBeAg in serum was more frequent in patients with acute self-limited than in those with chronic hepatitis B at presentation (82% versus 65%, *P* < 0.05). The most remarkable virological differences between patients with acute self-limited and chronic hepatitis B were the sequences of the precore region and core promoter. The wild-type precore sequence was detected in HBV DNA samples from all 50 patients with acute self-limited hepatitis B at presentation, and the wild-type core

Table IV. Wild-type sequences of precore region and core promoter in 203 patients with chronic hepatitis B who were infected with HBV of genotype A, B or C

Time and genotypes	Wild-type			
	Precore region	Differences	Core promoter	Differences
At the presentation				
Genotype A (n = 11)	11 (100%)] <i>P</i> < 0.01	4 (36%)] <i>P</i> < 0.05
Genotype B (n = 25)	13 (52%)		19 (76%)	
Genotype C (n = 167)	126 (75%)] <i>P</i> < 0.05	50 (30%)] <i>P</i> < 0.001
Total (n = 203)	150 (75%)		73 (36%)	
After the loss of HBsAg or follow-up >15 years				
Genotype A (n = 11)	11 (100%)] <i>P</i> < 0.001	3 (27%)] <i>P</i> < 0.001
Genotype B (n = 25)	4 (16%)		13 (52%)	
Genotype C (n = 167)	53 (32%)		21 (13%)	
Total (n = 203)	68 (33%)		37 (18%)	

promoter in 38 (88%) of them. These results have confirmed and extended the report of Ogawa et al., who found the wild-type precore sequence in 23 of 25 (92%) patients and the wild-type core promoter in 16 of 21 (76%) patients with acute hepatitis B from Japan (14). Our findings are also consistent with wild-types of the precore region and core promoter that have been detected much more prevalently in patients with acute self-limited than fulminant hepatitis B (15, 16).

In remarkable contrast, the wild-type precore sequence was detected less often in 150 of the 203 (74%) patients with chronic hepatitis B at presentation ($P < 0.001$) and those in core promoter in only 73 (36%) of them ($P < 0.001$) than in patients with acute self-limited hepatitis B. These results indicate that acute hepatitis B would have been induced by street HBV strains with the wild-type of both the precore region and core promoter. By contrast, chronic hepatitis B would be a consequence of long-standing HBV infection since time of birth in Japan. The wild-type sequences in both the precore region and core promoter were found in only 36% of the patients who presented with chronic hepatitis. Hence the majority would have been seroconverting toward the antibody to HBeAg accompanied by elevated transaminase levels in serum.

The 1858th nucleotide makes a pair with the 1896th nucleotide and affects the mutation from G to A at this position (17–19). It was C in all HBV isolates of genotype A as has been reported. In contrast, nt 1858 was T in all HBV isolates of genotypes B, as well as in those of genotype C, unlike HBV isolates of genotype C from Hong Kong that frequently possess C1858 (20, 21).

There were many differences in the evolution of precore and core promoter mutations between patients with acute self-limited and chronic hepatitis B. The wild-type of the precore region or core promoter persisted in most patients with acute self-limited hepatitis until they resolved HBV infection. It was reasonably delineated in view of a short duration while they had clinical diseases. By contrast, the wild-type of both precore and core promoter decreased in patients with chronic hepatitis B during >15 years of follow-up in a manner dependent on HBV genotypes. The wild-type precore sequence thus decreased by >35% and the wild-type core promoter by >16% in patients infected with HBV of genotype B or C. These results concur with changes in precore and core promoter mutations in HBV strains infecting 7 Japanese patients followed for 6–11 years (22). In patients infected with HBV of genotype A, however, the wild-type sequences of the precore region persisted during follow-ups >15 years; those of core promoter decreased only from 36% to 27%. These genotype-dependent changes in precore and core promoter sequences may explain, at least in part, the influence of HBV genotypes on the severity and course of chronic hepatitis B (23–26).

In conclusion, acute self-limited hepatitis B is induced by HBV strains of the wild-type sequences in both the precore region and the core promoter. In chronic hepatitis B,

mutations in the precore region and core promoter prevail and increase during >15 years of follow-up. HBV genotypes influence the development of precore and core promoter mutations in chronic hepatitis B.

References

1. Lee WM. Hepatitis B virus infection. *N Engl J Med* 1997;337:1733–45.
2. Carman WF, Jacyna MR, Hadziyannis S, Karayiannis P, McGarvey MJ, Makris A, et al. Mutation preventing formation of hepatitis B e antigen in patients with chronic hepatitis B infection. *Lancet* 1989;2:588–91.
3. Okamoto H, Yotsumoto S, Akahane Y, Yamanaka T, Miyazaki Y, Sugai Y, et al. Hepatitis B viruses with precore region defects prevail in persistently infected hosts along with seroconversion to the antibody against e antigen. *J Virol* 1990;64:1298–303.
4. Okamoto H, Tsuda F, Akahane Y, Sugai Y, Yoshida M, Moriyama K, et al. Hepatitis B virus with mutations in the core promoter for an e antigen-negative phenotype in carriers with antibody to e antigen. *J Virol* 1994;68:8102–10.
5. Buckwold VE, Xu Z, Chen M, Yen TS, Ou JH. Effects of a naturally occurring mutation in the hepatitis B virus basal core promoter on precore gene expression and viral replication. *J Virol* 1996;70:5845–51.
6. Usuda S, Okamoto H, Iwanari H, Baba K, Tsuda F, Miyakawa Y, et al. Serological detection of hepatitis B virus genotypes by ELISA with monoclonal antibodies to type-specific epitopes in the preS2-region product. *J Virol Methods* 1999;80:97–112.
7. Usuda S, Okamoto H, Tanaka T, Kidd-Ljunggren K, Holland PV, Miyakawa Y, et al. Differentiation of hepatitis B virus genotypes D and E by ELISA using monoclonal antibodies to epitopes on the preS2-region product. *J Virol Methods* 2000;87:81–9.
8. Stuyver L, De Gendt S, Van Geyt C, Zoulim F, Fried M, Schinazi RF, et al. A new genotype of hepatitis B virus: complete genome and phylogenetic relatedness. *J Gen Virol* 2000. p. 67–74.
9. Kato H, Orito E, Sugauchi F, Ueda R, Gish RG, Usuda S, et al. Determination of hepatitis B virus genotype G by polymerase chain reaction with hemi-nested primers. *J Virol Methods* 2001; 98:153–9.
10. SAS. Institute SAS/ST AT User's Guide, Release 6.11 Edition. Cary, N.C., USA 1996.
11. Okada K, Kamiyama I, Inomata M, Imai M, Miyakawa Y. e antigen and anti-e in the serum of asymptomatic carrier mothers as indicators of positive and negative transmission of hepatitis B virus to their infants. *N Engl J Med* 1976;294:746–9.
12. Stevens CE, Neurath RA, Beasley RP, Szmunes W. HBeAg and anti-HBe detection by radioimmunoassay: correlation with vertical transmission of hepatitis B virus in Taiwan. *J Med Virol* 1979;3:237–41.
13. Kobayashi M, Arase Y, Ikeda K, Tsubota A, Suzuki Y, Saitoh S, et al. Clinical characteristics of patients infected with hepatitis B virus genotypes A, B, and C. *J Gastroenterol* 2002;37:35–9.
14. Ogawa M, Hasegawa K, Naritomi T, Torii N, Hayashi N. Clinical features and viral sequences of various genotypes of hepatitis B virus compared among patients with acute hepatitis B. *Hepatol Res* 2002;23:167–77.
15. Aye TT, Uchida T, Becker SO, Hirashima M, Shikata T, Komine F, et al. Variations of hepatitis B virus precore/core gene sequence in acute and fulminant hepatitis B. *Dig Dis Sci* 1994;39: 1281–7.
16. Aritomi T, Yatsushashi H, Fujino T, Yamasaki K, Inoue O, Koga M, et al. Association of mutations in the core promoter and precore region of hepatitis virus with fulminant and severe acute hepatitis in Japan. *J Gastroenterol Hepatol* 1998;13:1125–32.
17. Li JS, Tong SP, Wen YM, Vitvitski L, Zhang Q, Trepo C. Hepatitis B virus genotype A rarely circulates as an HBe-minus mutant: possible contribution of a single nucleotide in the precore region. *J Virol* 1993;67:5402–10.

18. Lok AS, Akarca U, Greene S. Mutations in the pre-core region of hepatitis B virus serve to enhance the stability of the secondary structure of the pre-genome encapsidation signal. *Proc Natl Acad Sci USA* 1994;91:4077-81.
19. Alestig E, Hannoun C, Horal P, Lindh M. Phylogenetic origin of hepatitis B virus strains with precore C-1858 variant. *J Clin Microbiol* 2001;39:3200-3.
20. Chan HL, Hussain M, Lok AS. Different hepatitis B virus genotypes are associated with different mutations in the core promoter and precore regions during hepatitis B e antigen seroconversion. *Hepatology* 1999;29:976-84.
21. Chan HL, Leung NW, Hussain M, Wong ML, Lok AS. Hepatitis B e antigen-negative chronic hepatitis B in Hong Kong. *Hepatology* 2000;31:763-8.
22. Uchida T, Aye TT, Shikata T, Yano M, Yatsubashi H, Koga M, et al. Evolution of the hepatitis B virus gene during chronic infection in seven patients. *J Med Virol* 1994;43:148-54.
23. Mayerat C, Mantegani A, Frei C. Does hepatitis B virus (HBV) genotype influence the clinical outcome of HBV infection? *J Viral Hepatitis* 1999;6:299-304.
24. Kao JH, Chen PJ, Lai MY, Chen DS. Hepatitis B genotypes correlate with clinical outcomes in patients with chronic hepatitis B. *Gastroenterology* 2000;118:554-9.
25. Orito E, Mizokami M, Sakugawa H, Michitaka K, Ishikawa K, Ichida T, et al. A case-control study for clinical and molecular biological differences between hepatitis B viruses of genotypes B and C. Japan HBV Genotype Research Group. *Hepatology* 2001;33:218-23.
26. Chu CJ, Lok AS. Clinical significance of hepatitis B virus genotypes. *Hepatology* 2002;35:1274-6.

Received 16 July 2003
Accepted 4 October 2003

Adefovir Dipivoxil for Treatment of Breakthrough Hepatitis Caused by Lamivudine-Resistant Mutants of Hepatitis B Virus

Tetsuya Hosaka Fumitaka Suzuki Yoshiyuki Suzuki Satoshi Saitoh
Masahiro Kobayashi Takashi Someya Hitomi Sezaki Norio Akuta
Akihito Tsubota Yasuji Arase Kenji Ikeda Hiromitsu Kumada

Department of Gastroenterology, Toranomon Hospital, Tokyo, Japan

Key Words

Adefovir dipivoxil · Lamivudine-resistant mutant ·
Hepatitis B virus · Interferon

Abstract

Objective: Adefovir dipivoxil (ADV) is a nucleoside analogue that inhibits wild-type hepatitis B virus (HBV) and lamivudine-resistant HBV mutants in vitro and in vivo. The aim of this study was to evaluate the efficacy of ADV against lamivudine-resistant mutants and of adefovir and interferon (IFN) add-on to lamivudine for patients with severe acute exacerbation of hepatitis caused by lamivudine-resistant mutants. **Methods:** Fourteen patients with breakthrough hepatitis were treated with ADV. Four of the 14 patients also received IFN as combined treatment for severe acute exacerbation of hepatitis. **Results:** At week 24, serum HBV DNA levels had significantly decreased by a median of over 4.8 log copies/ml in the ADV group and over 5.9 log copies/ml in the ADV + IFN group compared to baseline. The median decrease in alanine aminotransferase (ALT) levels from baseline to week 24 was –1.05 times the upper limit of normal (ULN) in the ADV group [significant at week 24 compared with baseline ($p = 0.012$)] and –22.3 times the ULN in the ADV + IFN group. **Conclusions:** Administration of ADV add-on to lamivudine for patients with breakthrough hepatitis reduced HBV DNA and ALT levels. ADV

and IFN add-on to lamivudine could prevent a fatal course in patients with severe acute exacerbation of hepatitis.

Copyright © 2004 S. Karger AG, Basel

Introduction

Lamivudine, a nucleoside analogue, inhibits replication of hepatitis B virus (HBV) and is used worldwide for treatment of chronic HBV infection [1–3]. Lamivudine improves alanine aminotransferase (ALT) concentrations and liver histological findings, causes few adverse events and is well tolerated [4, 5]. However, the emergence of lamivudine-resistant HBV strains in patients on long-term lamivudine therapy has been observed, and such resistant mutation occurs in the HBV DNA polymerase gene [6, 7]. Mutation at codon M552 of the YMDD motif results in substitution of methionine by isoleucine (M552I) or valine (M552V) [8]. The emergence of such mutant viruses results in the reevaluation of HBV DNA and ALT, and causes clinical and histologic progression [9]. Resistance was recently reported to develop in 12.5, 43.8 and 62.5% of patients after 1, 3 and 5 years of lamivudine therapy, respectively [10]. Other nucleoside analogues such as ganciclovir and famciclovir have limited efficacy against lamivudine-resistant HBV mutants [11]. Interferon (IFN) also exhibits antiviral ef-

KARGER

Fax +41 61 306 12 34
E-Mail karger@karger.ch
www.karger.com

© 2004 S. Karger AG, Basel
0300-5526/04/0476-0362\$21.00/0

Accessible online at:
www.karger.com/int

Tetsuya Hosaka, MD
Department of Gastroenterology, Toranomon Hospital
2-2-2 Toranomon, Minato-ku
Tokyo 105-8470 (Japan)
Tel. +81 44 877 5111, Fax +81 44 860 1623, E-Mail hosa-p@toranomon.gr.jp

ficacy against lamivudine-resistant mutants [9, 12]; however, the use of IFN is limited due to its side effects.

Adefovir dipivoxil (ADV) is a nucleoside analogue that selectively inhibits viral polymerases and reverse transcriptases and has broad-spectrum antiviral activity against retroviruses, hepadnaviruses and herpes viruses [13–16]. ADV has antiviral activity against not only wild-type HBV but also lamivudine-resistant HBV mutants *in vitro* and *in vivo* [17, 18]. Moreover, pilot clinical studies of ADV therapy for lamivudine-resistant mutants in liver and kidney transplant recipients, in human immunodeficiency virus (HIV)-HBV-coinfected patients and in decompensated cirrhotic patients have been recently reported [19–21]. In these studies, administration of ADV decreased serum HBV DNA levels and improved liver enzymes such as ALT. Meanwhile, severe acute exacerbations of hepatitis due to lamivudine-resistant mutants are sometimes associated with liver failure and mortality [22, 23]. One report showed that a cirrhotic patient with liver failure due to the emergence of a lamivudine-resistant mutant could not be rescued by administration of ADV despite a decrease in HBV DNA levels [24]. In the present study, we used IFN in addition to ADV to prevent hepatic decompensation. The previous studies of ADV for the treatment of lamivudine-resistant mutants were reported mainly in Western Europe, the USA and Canada. It is well known that the geographic distribution of HBV genotypes is different in Europe and America than in Asia; genotypes A and D are commonly found in Europe and America, whereas genotypes B and C are prevalent in Asia [25]. However, the emergence rates of lamivudine-resistant mutants did not depend on genotype A, B or C in our colleagues' recent report [26]. The present study reports the efficacy of ADV against lamivudine-resistant mutants of HBV genotypes B and C (mainly genotype C) in Japan during a median interval of about 6 months. In addition, we evaluated the effects of IFN addition to ADV in preventing liver failure and mortality from severe acute exacerbations of hepatitis caused by lamivudine-resistant mutants.

Patients and Methods

Patients

Lamivudine was administered to 316 patients at Toranomon Hospital, Tokyo, Japan, who had been infected with HBV for more than 1 year since 1995. In 66 patients (20.8%), resistance to lamivudine occurred, and serum HBV-DNA and ALT were reelevated despite continuation of lamivudine (breakthrough hepatitis). In this study, 14 patients with breakthrough hepatitis were treated

with ADV. Ten of the 14 patients were administered ADV alone in addition to lamivudine (ADV group), and 4 were coadministered IFN as combined treatment for severe acute exacerbation of breakthrough hepatitis (ADV + IFN group). Severe acute exacerbation was defined as relevation of ALT levels to over 10 times the upper limit of normal (ULN) after a decrease of ALT levels by administration of lamivudine. No patients had coinfection with hepatitis A, hepatitis C, delta viruses, TT virus, cytomegalovirus, Epstein-Barr virus, herpes simplex virus or HIV, or a history of other liver diseases, such as autoimmune hepatitis, alcoholic liver disease or metabolic liver disease.

Procedure

Patients received a 10-mg once-daily dose of oral ADV, except for one patient who received 5 mg of ADV because of slight elevation of serum creatinine. Lamivudine therapy was continued in all patients. The 4 patients in the ADV + IFN group were treated with a daily dose of 6 million units of natural IFN- α (Sumiferon, Sumitomo Pharmaceutical, Osaka, Japan) at the same time as the treatment with ADV. IFN- α was given daily for 4 weeks and 3 times a week thereafter until virological and biochemical relapses were controlled. In 3 of the 4 patients, corticosteroid was also added at the same time as the treatment with ADV and IFN until biochemical relapses were controlled. Blood samples were obtained at least once or twice every month before, during and after treatment with ADV, and analyzed for virological markers, biochemical markers associated with liver function and renal function, and full blood count. Changes from baseline in serum HBV DNA, ALT, bilirubin and other biochemical markers were assessed.

Virological Studies

Serum HBV DNA levels were evaluated by quantitative polymerase chain reaction (PCR) assay (Amplicor HBV Monitor test, Roche Molecular Systems, Inc., N.J., USA). The detection range of this assay was 2.6–8.7 log copies/ml. HBsAg and HBeAg/e antibodies were determined by commercially available radioimmunoassay systems (Dainabot, Tokyo, Japan). Confirmation of mutation in the HBV DNA polymerase gene (codon M552 of the YMDD motif) was determined using the PCR-based method of Chayama et al. [27]. HBV genotype was determined by enzyme-linked immunosorbent assay (HBV Genotype EIA, Institute of Immunology, Tokyo) based on the method of Usuda et al. [28].

Statistical Analysis

Wilcoxon's signed rank test was used to evaluate changes in serum HBV DNA and ALT levels from baseline. A *p* value of less than 0.05 was considered statistically significant. Changes in serum HBV DNA and ALT levels were plotted in graph format using the median value. Each error bar indicates 25 or 75 percentile points in all values at various time points from the commencement of ADV treatment.

Results

The clinical and virological profiles of the 14 patients prior to adefovir treatment with IFN (ADV + IFN group) or without IFN (ADV group) are shown in table 1. One