



Figure 3. A: Postoperative radiograph shows the massive skeletal reconstruction and the bag of antibiotic impregnated cement beads. B: Radiograph shows Zielke rod, which was left after removal of the ISOLA system due to infection.

ular graft (110 mm) from both lower legs was undertaken under an air-tourniquet. The patient was moved into prone position, and the posterior approach was started with a three-limbed incision, the so-called "Mercedes star incision," on the lower back. The osteotomy of the ilia around the sacroiliac joint was completed with the T-saw. After the L5 laminectomy, the dural sac at L5-S1 was ligated and cut. All the ligaments connecting the sacrum to the ischium (sacrospinous and sacrotuberous ligament) and the anal coccygeal ligament were exposed and cut. The sacrum was elevated from distal to proximal after cutting the sacral nerves. At this time, a total *en bloc* resection of the sacrum with a part of iliac wing was accomplished.

The spinal instrumentation system was used to connect the lumbar spine and both ilia. Reconstruction began with the L5 vertebral body, which was pulled distally and placed between the bilateral iliac crest. A Zielke rod inserted through both iliac crests and the vertebral body of the fifth lumbar spine closed the space between the crests, compressing them to the vertebral body *via* nuts of the Zielke system (Ulrich, Germany). The pedicular screws of ISOLA system (DePuy AcroMed, Rayham, MA) were inserted from L3 through L5. Iliac screws were inserted in both ilia. The ilia were then notched to receive the press-fit autogenous fibula grafts distal to the L5 body. A bag of antibiotic-impregnated beads with piperacillin (16 g) and gentamycin (480 mg) into Surgical Simplex P Radiopaque Bone Cement (40 g, Howmedica) was placed to reduce the vacated space and to assure a local control of infection (Figure 3A). Myocutaneous wound closure with gluteus muscle was performed, and four suction drains were placed. Total bleeding was approximately 12,000 mL, and the operative time was 19 hours. Histologic examination of the resected specimen confirmed the positive response to the preoperative treatment, no viable tumor cells were found. Intravenous antibiotic administration continued for 16 days due to a urinary tract infection followed by 5 weeks of oral administration. The gentamycin beads were removed 3 months after surgery, and passive range of motion exercise started in a wheelchair 8 months after surgery. Daily rehabilitation (quadriceps setting exercise, active range of motion exercise, ambulation with a walker) enabled the patient to finally walk with two crutches in the second postoperative year. During the postoperative chemotherapy (3 cycles of MAID; Mesna, ADR, IFX, DTIC), decubitus of the buttock expanded. Despite daily irrigation, the ISOLA system and iliac screws were removed to control an infection that developed in the ninth postoperative month (Figure 3B). The autogenous fibula grafts were stable, and the Zielke rod remained in place.

At 5 years after tumor excision and reconstruction, the patient continues to be disease free. He can drive an automobile with automatic transmission and ascend stairs holding the handrail and using one crutch. He can urinate by self-catheterization and can evacuate the bowel by voluntary increase of the abdominal muscle pressure or a laxative. At the last follow-up, the patient expressed satisfaction with his degree of mobility and ability to live independently.

#### ■ Discussion

The estimated incidence of primary sacral tumors among all bone tumors is 1.49% (332 of 22,327) from 1967 to 1992 in Japan<sup>14</sup>; among them, the common primary malignant sacral tumors are chordoma (163 cases), chondrosarcoma (25 cases), osteosarcoma (11 cases), and Ewing's sarcoma (11 cases). Synovial sarcomas of the sacrum are rare. In this patient, the initial histologic assessment of a specimen from open biopsy of the sacrum was reported as synovial sarcoma. Although SYT-SS10 fusion gene can be detected in 95% of synovial sarcomas,<sup>15-19</sup> this tumor should be designated as an unclassified sarcoma because of the absence of SYT-SS10 fusion gene and the markedly excellent response to chemotherapy. Chemosensitivity of synovial sarcoma is reported to be not high, and it does not seem to affect pleomorphic fibrosarcoma or osteosarcoma.<sup>20</sup>

Total or extended sacrectomy was the only radical means to treat the massive sacral tumor in our case. Although the incidence of local recurrence after excision of sacrum tumor is high,<sup>9,21</sup> if wide local excisions are performed in sacral neoplasms, there seem to be few local recurrences. Combined anterior and posterior excision is needed for lesions extending to the S1 or S2 body to achieve adequate margin.<sup>3,7,9,10</sup>

Resection involving more than 50% of the sacroiliac joint makes the pelvis unstable,<sup>15</sup> and reconstruction after extensive sacral tumor resection, which results in complete dissociation of the spine from the pelvis, is necessary to restore continuity of the spine and pelvic ring.<sup>3,7,10,22</sup> Various reconstruction methods after total sacrectomy include the use of sacral bars to connect the ilium and the spine with Harrington rods, the use of transpedicular screws with iliac screws connected by plates, the vertical Galveston rods attached to cross-connecting spinal rods, a threaded transiliac rod, and the use of custom-made sacral prosthesis.<sup>3,7,10,22</sup> For the current case, we selected the Zielke rod to obtain compression between L5 vertebra and bilateral iliac crest, and the ISOLA reconstruction system, which allowed the patient to walk with crutches early in rehabilitation.

Unavoidable neurologic deficits in total sacrectomy are serious in the treatment selection. The sacrifice of the S3 nerve root causes sexual dysfunction, and of the bilateral S2 nerve roots, cause loss of normal urogenital and rectal functions.<sup>9</sup> In the same way, motor function of the lower legs is disturbed after resection of sciatic nerves, but walking with a short leg brace is possible if the L5 nerve roots can be preserved.

The postoperative course is often complicated by infection and delayed wound healing.<sup>3,9</sup> The risk of postoperative infection is high because of the large space vacated by the sacrum, the use of instrumentation, and the long time in surgery. The aggressive measures taken to avoid early infection were effective in the current case; late infection during postoperative chemotherapy developed due to decubitus.

The surgical risks and postoperative complications that attend an extended total sacrectomy are not trivial. Neurologic deficits and gait disturbance are unavoidable. The risk of fracture from falling is increased. On balance, the patient remains disease free and is satisfied with his level of activity and autonomy. The patient's excellent response to preoperative antitumor treatment was a key consideration. The decision between a wide local excision with reconstruction and a less extensive procedure with combined therapy remains controversial.

#### ■ Key Points

- We report a case with sacral malignancy, and a successful en bloc excision of the whole sacrum including part of the iliac wings, followed by reconstruction of the sacroiliac joint.
- The surgical risks and complications in total sacrectomy are serious.
- The patient's excellent response to preoperative anti-tumor treatment was a key consideration.

#### References

1. Ozaki T, Flege S, Liljenqvist U, et al. Osteosarcoma of the spine: experience of the Cooperative Osteosarcoma Study Group. *Cancer*. 2002;94:1069-1077.
2. Wuisman P, Lieshout O, Sugihara S, et al. Total sacrectomy and reconstruction: oncologic and functional outcome. *Clin Orthop*. 2000;381:192-203.
3. Wuisman P, Lieshout O, van Dijk M, et al. Reconstruction after total en bloc sacrectomy for osteosarcoma using a custom-made prosthesis: a technical note. *Spine*. 2001;26:431-439.
4. Stener B, Gunterberg B. High amputation of the sacrum for extirpation of tumors: principles and technique. *Spine*. 1978;3:351-366.
5. Sundaresan N, Huvos AG, Krol G, et al. Postradiation sarcoma involving the spine. *Neurosurgery*. 1986;18:721-724.
6. Sundaresan N, Huvos AG, Krol G, et al. Surgical treatment of spinal chordomas. *Arch Surg*. 1987;122:1479-1482.
7. Shikata J, Yamamuro T, Kotoura Y, et al. Total sacrectomy and reconstruction for primary tumors: report of two cases. *J Bone Joint Surg Am*. 1988;70:122-125.
8. Samson IR, Springfield DS, Suit HD, et al. Operative treatment of sacrococcygeal chordoma: a review of twenty-one cases. *J Bone Joint Surg Am*. 1993;75:1476-1484.
9. Ozaki T, Hillmann A, Winkelmann W. Surgical treatment of sacrococcygeal chordoma. *J Surg Oncol*. 1997;64:274-279.
10. Tomita K, Tsuchiya H. Total sacrectomy and reconstruction for huge sacral tumors. *Spine*. 1990;15:1223-1227.
11. Cheng EY, Ozerdemoglu RA, Transfeldt EE, et al. Lumbosacral chordoma: prognostic factors and treatment. *Spine*. 1999;24:1639-1645.
12. Spiegel DA, Richardson WJ, Scully SP, et al. Long-term survival following total sacrectomy with reconstruction for the treatment of primary osteosarcoma of the sacrum: a case report. *J Bone Joint Surg Am*. 1999;81:848-855.
13. Daniels L, Worthingham C. Muscle testing. In: *Techniques of Manual Examination*, 6th ed. Philadelphia: Saunders, 1995.
14. JOA Musculoskeletal Tumor Committee (Report). *Bone Tumor Registry in Japan*. National Cancer Institute, Tokyo, 1992;120-121.
15. Clark J, Rocques PJ, Crew AJ, et al. Identification of novel genes, SYT and SSX, involved in the t(X;18)(p11.2;q11.2) translocation found in human synovial sarcoma. *Nat Genet*. 1994;7:502-508.
16. Crew AJ, Clark J, Fisher C, et al. Fusion of SYT to two genes, SSX1 and SSX2, encoding proteins with homology to the Kruppel-associated box in human synovial sarcoma. *EMBO J*. 1995;14:2333-2340.
17. Skytting BT, Szymanska J, Aalto Y, et al. Clinical importance of genomic imbalances in synovial sarcoma evaluated by comparative genomic hybridization. *Cancer Genet Cytogenet*. 1999;115:39-46.
18. Skytting B, Nilsson G, Brodin B, et al. A novel fusion gene, SYT-SSX4, in synovial sarcoma. *J Natl Cancer Inst*. 1999;91:974-975.
19. Panagopoulos I, Mertens F, Isaksson M, et al. Clinical impact of molecular and cytogenetic findings in synovial sarcoma. *Genes Chromosomes Cancer*. 2001;31:362-372.
20. Okcu MF, Despa S, Choroszy M, et al. Synovial sarcoma in children and adolescents: thirty three years of experience with multimodal therapy. *Med Pediatr Oncol*. 2001;37:90-96.
21. Sar C, Eralp L. Surgical treatment of primary tumors of the sacrum. *Arch Orthop Trauma Surg*. 2002;122:148-155.
22. Gokaslan ZL, Romsdahl MM, Kroll SS, et al. Total sacrectomy and Galveston L-rod reconstruction for malignant neoplasms: technical note. *J Neurosurg*. 1997;87:781-787.

TECHNICAL NOTE

## Reconstruction with ipsilateral fibula transfer with pasteurized bone after excision of bone sarcoma of the tibia

TOSHIFUMI OZAKI<sup>1</sup>, KAZUO FUJIWARA<sup>1</sup>, TOSHIYUKI KUNISADA<sup>1</sup>,  
TATSUO ITO<sup>1</sup>, AKIRA KAWAI<sup>2</sup>, HAJIME INOUE<sup>1</sup>

<sup>1</sup>Department of Orthopaedic Surgery, Okayama University Hospital, 2-5-1 Shikata-cho, Okayama 700-8558, Japan

<sup>2</sup>Department of Orthopaedic Surgery, National Cancer Center Hospital, Tsukiji, Chuo-ku, Tokyo 104-0045, Japan

### Abstract

We report a technique of implantation of the ipsilateral vascularized fibula with pasteurized recycled bone after excision of tibia sarcoma in two cases. Plate and screws were used for osteosynthesis of the tibia or talus, vascularized fibula, and pasteurized bone. Microsurgery is not necessary for this reconstruction technique. Two patients who underwent this technique have obtained good functional results without tumor relapse 5 and 6 years after operation. The technique produced excellent results with regard to tibial reconstruction in these cases. We found it to be simple, speedy, safe, and a low cost technique by use of recycled bone.

### Introduction

Tumor area in bone and its extraskelatal involvement can currently be clearly recognized with a careful preoperative radiological evaluation, including magnetic resonance (MR) imaging.<sup>1</sup> Improved imaging techniques<sup>2</sup> and preoperative chemotherapy<sup>3,24</sup> permit limb-sparing surgeries to be carried out safely in patients with bone and soft tissue tumors. Good long-term functional results have been reported after reconstruction of large bone defects using vascularized fibular grafts after tumor resection.<sup>5</sup> The bone union rate in one report was 81% (130 of 160 patients) at an average of 42 months after vascularized bone transfer.<sup>6</sup> However, lower extremity reconstructed with only a vascularized fibula apparently is too weak to withstand the mechanical stresses of full weight bearing before union or thickening of the grafted fibula. When a pasteurized bone shell is implanted around a vascularized fibula, the recycled bone can strengthen the fibula and bone junction, and protect the fibula from mechanical failure. Moreover, if ipsilateral vascularized fibula from the affected site is available, the operative invasion can be limited to only one leg. We report a technique of such a reconstruction of the tibial defects after tumor excision of the tibia in two cases.

The ipsilateral vascularized fibula was transferred centro-medially, and pasteurized tibial bone was implanted as an autograft shell with plate and screws. The procedure is a modification of a technique originally described by Capanna *et al.*<sup>7</sup> and Wuisman *et al.*<sup>8</sup>

### Operative technique

The tibial tumor is excised with a wide margin. The attached soft tissue of the resected bone including the tumor is removed. Tumor resection and graft preparation procedures must be done on tables other than the instrumentation or operation table to prevent tumor contamination. A massive pasteurized bone graft is prepared from the resected tibial portion by treatment in physiological saline with povidone iodine (concentration, 3000 mg/1000 mL) at 60°C for 30 min.<sup>10</sup> The pasteurized bone then is reamed. One-third of the circumference of the pasteurized bone is excised longitudinally to allow implantation of the vascularized fibula in the cavity of the shell. Two-thirds of the tibia is retained for external support of the vascularized fibula. The ipsilateral fibula, which is usually cut 4-5 cm longer than the resection, is harvested with its periosteal cuff and peroneal vessels. The ends of

Correspondence to: Toshifumi Ozaki, Department of Orthopaedic Surgery, Okayama University Hospital, 2-5-1 Shikata-cho, Okayama 700-8558, Japan. Tel.: +81-86-235-7273; Fax: +81-86-223-9727; E-mail: tozaki@md.okayama-u.ac.jp

1357-714X print/1369-1643 online © 2004 Taylor & Francis Ltd  
DOI: 10.1080/13577140400017794

the vascularized fibula are inserted a few centimeters into the medullary canal of the residual tibia, and 5 mm into the talus. The meta-diaphyseal intercalary pasteurized bone is implanted around the fibula with the vascular pedicle emerging from the split side of the pasteurized bone. The fibular blood flow is confirmed by the bleeding at the end of the bone before osteosynthesis.

## Case report

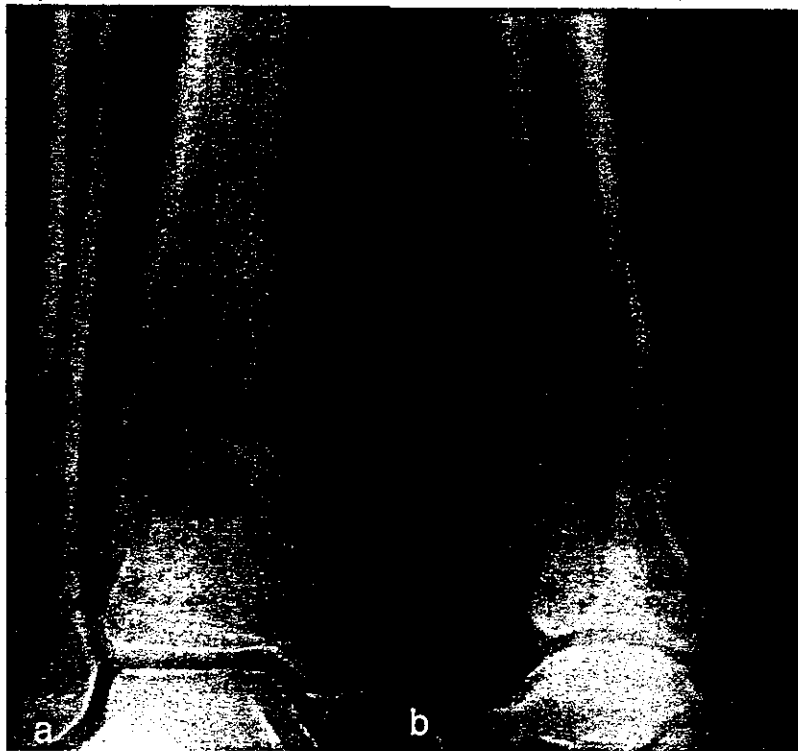
### Case 1

A 45-year-old man had a sudden onset of left lower leg pain while he was playing baseball. A radiograph of the left lower leg revealed a pathological fracture of the tibia and he was referred to the authors' hospital. The patient's medical history and family history were unremarkable. The patient presented with swelling and tenderness of the left lower leg. Plain radiographs revealed an osteolytic shadow and a fracture at the distal metaphysis of the left tibia (Fig. 1). Bone scan showed an abnormal uptake from the shaft to the distal tibia. A digital subtraction angiograph showed increased vascularity of the vessels in the lesion. MR images showed a low-signal intensity tumor with an extra-skeletal tumor projection on T1-weighted images (Fig. 2a) and a high-signal intensity on T2-weighted images. Gadolinium-diethylenetriaminepentaacetic acid (DTPA)-enhanced T1-weighted images showed

inhomogeneous enhancement of the tumor (Fig. 2b). Open biopsy was performed; the diagnosis was leiomyosarcoma. Two cycles of preoperative chemotherapy ifosfamide, doxorubicin, and dacarbazine (MAID)<sup>9</sup> were administered. Preoperative intra-arterial administration of cisplatin (150 mg) was done twice. Preoperative MR images made after chemotherapy showed tumor limited to the tibia.

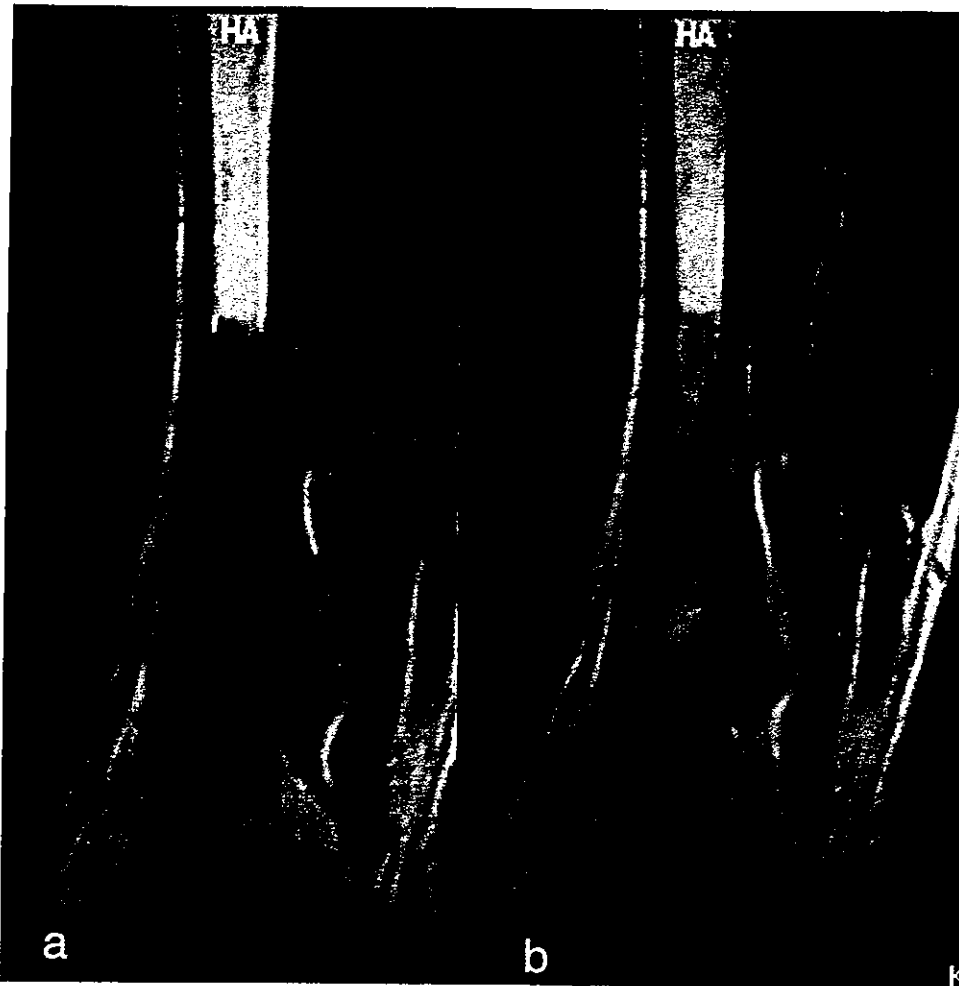The tumor was excised with a wide margin. The resected bone was removed for pasteurization. The fibula was cut 5 cm longer than the resected tibia. After dividing the intraosseous membrane, the peroneal vessels were identified. The fibula was not released, but with the muscles, it was moved antero-medially. The proximal end was inserted in the residual tibia and the distal end was inserted in the talus. The pasteurized bone was implanted around the fibula. A long plate with seven screws was used for osteosynthesis.

The bone union was rapid, and partial weight bearing began 12 weeks after operation. At 6 months, full weight bearing was permitted. Twelve months after operation, the junction between the recycled bone and host bone had almost healed. The patient, a postman, had resumed his work, which included riding a motor bike. At 5 years after the operation, the junction was completely healed (Fig. 3). The leg length discrepancy was 3 cm. Evaluation scores at last follow-up, according to the method of Enneking *et al.*,<sup>11</sup> were 5 in pain, 4 in function, 4



Ozaki T, et al.

Fig. 1. Case 1. Plain radiograph shows a radiolucent area with pathological fracture in the distal tibia. (a) Antero-posterior view; (b) lateral view.



Ozaki T, et al.

**Fig. 2.** Case 1. (a) T1-weighted magnetic resonance (MR) imaging showed a low-signal intensity tumor with extra-skeletal projection. (b) Gadolinium-diethylenetriaminepentaacetic acid (DTPA)-enhanced T1-weighted images showed an inhomogeneously enhanced tumor.

emotional acceptance, 5 support, 5 for walking, 4 for gait; 27 (90%) in total.

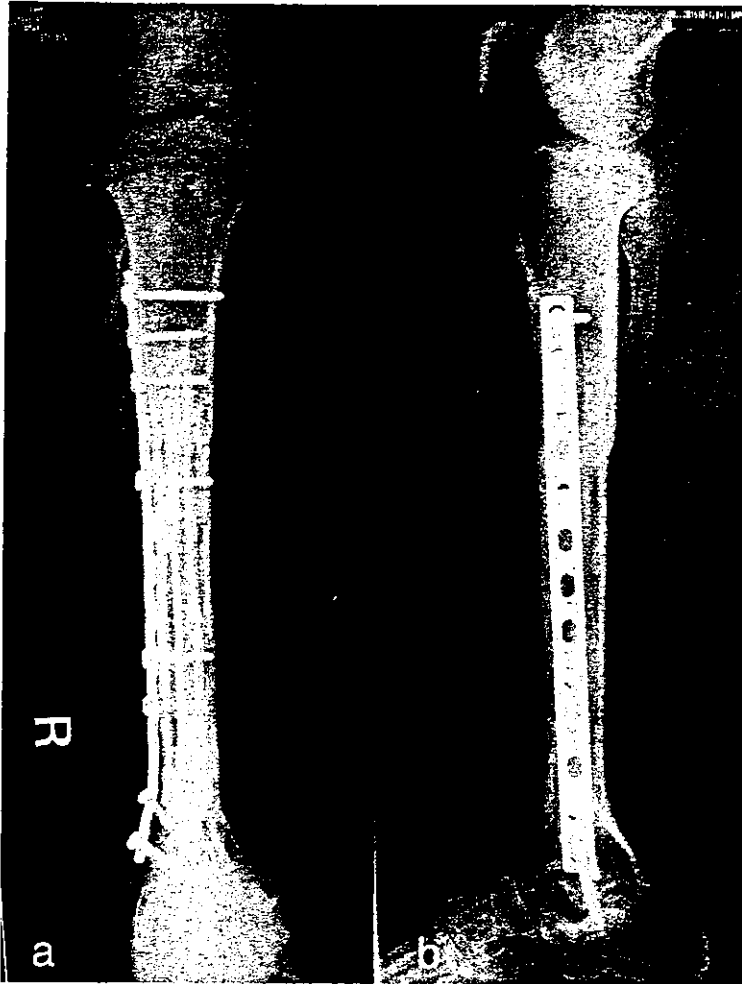
#### Case 2

A 12-year-old boy had right lower leg pain without trauma. His medical history indicated that he had had red cell aplasia 1 month after birth and had received steroid therapy. His family history indicated that his mother had colon cancer. The patient's lower leg pain increased gradually, and night pain developed. Abnormal findings were identified on plain radiographs, and he was referred to the authors' institute where he presented with tenderness on the proximal part of the right lower leg.

Plain radiographs showed a periosteal reaction of the posterior diaphysis and a sclerotic shadow in the meta-diaphysis of the right tibia (Fig. 4a). MR images showed a low signal intensity area of 15 cm on T1-weighted images (Fig. 4b) and a high signal intensity area on T2-weighted images in the diaphysis of the right tibia. A bone scan showed an abnormal high-uptake in the right meta-diaphysis of the tibia. Histological diagnosis indicated a high

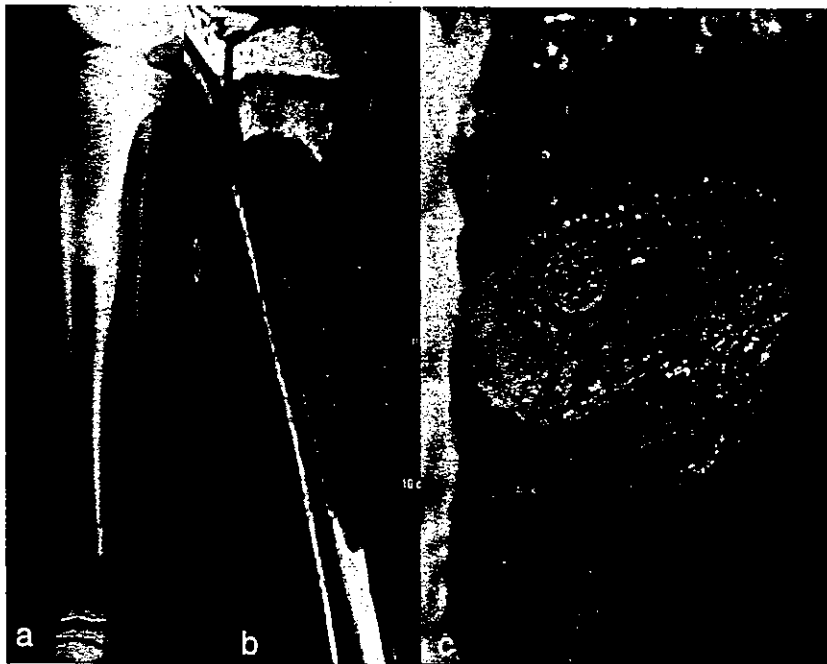
suspicion of benign tumor with a small possibility of osteosarcoma. There was no extra-skeletal tumor protrusion, and the diagnosis was unclear.

Tumor excision with a wide surgical margin without preoperative chemotherapy was performed in this patient. The residual epiphyseal bone segment measured 2 cm in thickness. After tumor excision, the vascularized fibula, which was 4 cm longer than the tibia defect, was transferred antero-medially. The vascularized fibula was inserted in the pasteurized resected tibia (Fig 4c), and both ends of the fibula were inserted in the residual tibia. Osteosynthesis was by means of metal plates with screws. Histological diagnosis after examination of the resected specimen was a low-grade osteosarcoma. Postoperative chemotherapy was administered according to the modified NECO95J protocol.<sup>4</sup> Partial weight bearing was started 11 weeks after operation. Full weight bearing was permitted from 3 months after operation. To date, the patient has survived more than 5 years without relapse after the operation. He can walk without external support (Fig. 5a). The bone union is excellent (Fig. 5b). The leg length discrepancy was 3 cm. Evaluation



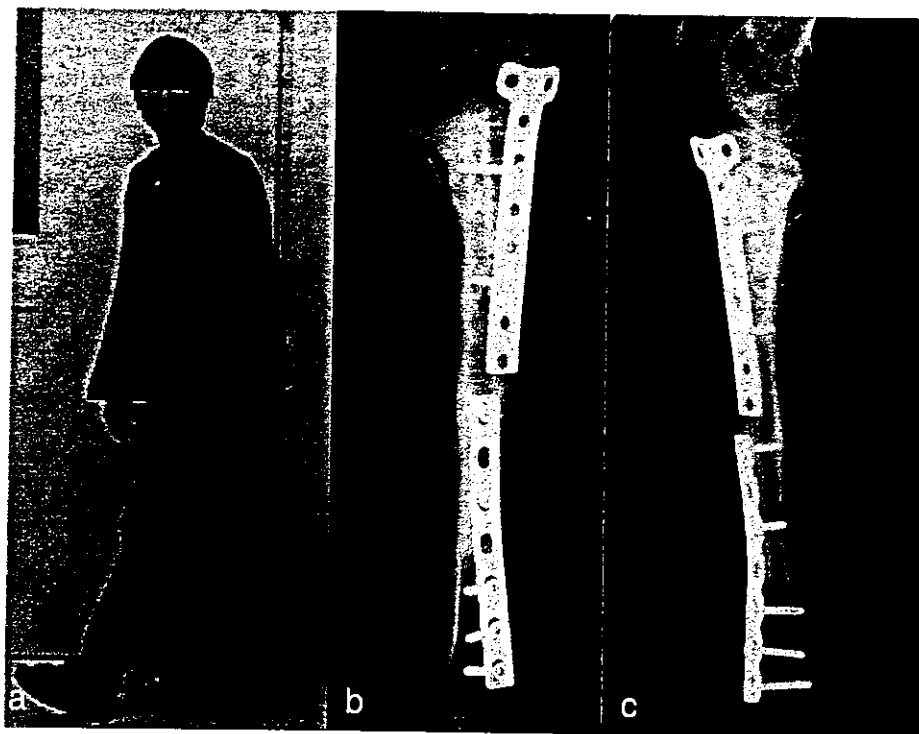
Ozaki T, et al.

Fig. 3. Case 1. Radiograph taken at 5 years after operation. The junction site of bone healed completely. (a) Antero-posterior view; (b) lateral view.



Ozaki T, et al.

Fig. 4. Case 2. (a) Radiograph showed periosteal reaction of the posterior proximal meta-diaphysis of the tibia and sclerotic shadow in the proximal meta-diaphysis of the right tibia. (b) Magnetic resonance images showed a low signal intensity area (T1-weighted images). (c) The fibula end protrudes from the pasteurized tibia.



Ozaki T, et al.

Fig. 5. Case 2. Five years after operation. (a) The patient, a high-school student at age 17 years, is shown using the knee brace. However, he can walk without further external supports. (b) Anterior-posterior view of plain radiograph. (c) Lateral view of plain radiograph.

scores at last follow-up, according to the method of Enneking *et al.*,<sup>11</sup> were 5 for pain, 3 for function, 4 for emotional acceptance, 4 for support, 4 for walking, 4 for gait; 24 (80%) in total.

### Discussion

Cappana *et al.*, in 1991, reported that contralateral vascularized fibula anastomosis was performed after excision of the tibial sarcoma.<sup>7</sup> Their reconstruction procedure was characterized by a combination of an external allograft with an inner, vascularized free fibular flap.<sup>7,12</sup> In 1996, Wuisman *et al.* reported ipsilateral vascularized fibula transfer with implantation of allograft after excision of tibial sarcoma.<sup>8</sup> The author of the current report published the results of ipsilateral vascularized fibula and implantation of allograft shell in 12 cases.<sup>13</sup> The subsequent debate on the relative usefulness of the ipsilateral fibula graft versus the contralateral fibula graft continues.

Ipsilateral fibula transfer is an easy technique that can be completed in a relatively short operation time, and does not require vessel anastomosis. Volume reduction of the lower leg due to antero-medial shift of the fibula facilitates skin closure after tumor excision. However, careful control of alignment at the operative site is necessary to prevent malalignment of the lower leg. In cases of vascularized fibula transfer, valgus deformity of the donor site ankle is known to occur after fibulectomy,<sup>14,15</sup> especially in children younger than 10–12 years.<sup>16,17</sup>

A tibiofibular syndesmotic screw efficiently prevents ankle valgus.<sup>5</sup>

We think that the fibula alone is inadequate to withstand compression and torsion stresses of weight bearing. And it is thought that a shell implant with plate and screws is a reasonable structural supplement for the fibula. Internal plate fixation is preferable to external fixation for osteosynthesis. In a previous report,<sup>13</sup> patients with fixation by screws or Kirschner wire had fracture or deformity of the junction, but patients with plate fixation had no such complications at the junction. A long plate with several screws is better than a minimal osteosynthesis using small fragment screws.<sup>12</sup> The risk of infection may be increased because patients usually receive postoperative chemotherapy and the pasteurized bone is not as strong as against infection. However, pasteurized bone, in general, has fewer complications and faster bone union than allograft bone does.<sup>10,13</sup>

Both cases in the current report illustrate reconstruction of the tibia with vascularized fibula transfer and pasteurized bone. The authors consider the method to be excellent for tibial reconstruction because it is a simple, speedy, and safe technique with an economical use of recycled bone.

### References

1. Spina V, Torricelli P, Montanari N, Manfredi M, Picci P, Sangiorgi L, *et al.* The epiphyseal involvement of metaphyseal bone sarcomas in patients with fertile growth plates. A magnetic resonance assessment. *Radiol Med (Torino)* 1994; 88(3): 190–7.

2. Ozaki T, Inoue H, Taguchi K, Sugihara S. Gadolinium-DTPA enhanced magnetic resonance imaging of bone and soft tissue sarcomas in comparison with pathological findings. *Acta Med Okayama* 1992; 46(6): 471-7.
3. Bielack S, Kempf-Bielack B, Schwenger D, Birkfellner T, Delling G, Ewerbeck V, et al. [Neoadjuvant therapy for localized osteosarcoma of extremities. Results from the Cooperative osteosarcoma study group COSS of 925 patients.] *Klin Padiatr* 1999; 211(4): 260-70.
4. Isu K, Yamawaki S, Beppu Y, Umeda T, Kawaguchi T, Tatezaki S, et al. Prognostic results from multi-institute study of adjuvant chemotherapy for osteogenic sarcoma. *J Jpn Orthop Assoc* 1999; 73(Suppl): 1134-5.
5. Fragniere B, Wicart P, Mascard E, Dubousset J. Prevention of ankle valgus after vascularized fibular grafts in children. *Clin Orthop* 2003; 408: 245-51.
6. Han CS, Wood MB, Bishop AT, Cooney WP, 3rd. Vascularized bone transfer. *J Bone Joint Surg Am* 1992; 74(10): 1441-9.
7. Capanna R, Bufalini C, Campanacci M. A new technique for reconstructions of large metadiaphyseal bone defects. A combined graft (allograft shell plus vascularized fibula). *Orthop Traumatol* 1993; 2: 159-77.
8. Wusiman P, Gruenert J, Langer M. Ipsilateral, pedicled fibula transfer in the treatment of malignant tibia tumor. *Op Orthop Traumatol* 1996; 8(2): 142-52.
9. Kawai A, Naito N, Sugihara S, Ozaki T, Morimoto Y, Inoue H. Mesna, adriamycin, ifosfamide, dacarbazine (MAID) chemotherapy for high grade soft tissue sarcomas. *Orthop Surg* 2000; 51(5): 509-13.
10. Manabe J, Kawaguchi N, Matsumoto S. Pasteurized autogenous bone graft for reconstruction after resection of malignant bone and soft tissue tumors: imaging features. *Semin Musculoskelet Radiol* 2001; 5(2): 195-201.
11. Enneking WF, Dunham W, Gebhardt MC, Malawar M, Pritchard DJ. A system for the functional evaluation of reconstructive procedures after surgical treatment of tumors of the musculoskeletal system. *Clin Orthop* 1993; 286: 241-6.
12. Manfrini M, Gasbarrini A, Malaguti C, Ceruso M, Innocenti M, Bini S, et al. Intraepiphyseal resection of the proximal tibia and its impact on lower limb growth. *Clin Orthop* 1999; 358: 111-9.
13. Ozaki T, Hillmann A, Wuisman P, Winkelmann W. Reconstruction of tibia by ipsilateral vascularized fibula and allograft. 12 cases with malignant bone tumors. *Acta Orthop Scand* 1997; 68(3): 298-301.
14. Weiland AJ, Moore JR, Daniel RK. Vascularized bone autografts. Experience with 41 cases. *Clin Orthop* 1983; 174: 87-95.
15. Weiland AJ, Weiss AP, Moore JR, Tolo VT. Vascularized fibular grafts in the treatment of congenital pseudarthrosis of the tibia. *J Bone Joint Surg Am* 1990; 72(5): 654-62.
16. Omokawa S, Tamai S, Takakura Y, Yajima H, Kawanishi K. A long-term study of the donor-site ankle after vascularized fibula grafts in children. *Microsurgery* 1996; 17(3): 162-6.
17. Dean GS, Kime RC, Fitch RD, Gunneson E, Urbaniak JR. Treatment of osteonecrosis in the hip of pediatric patients by free vascularized fibular graft. *Clin Orthop* 2001; 386: 106-13.