

表 1 グルタミン酸受容体とサブユニット

1. グルタミン酸受容体
a) イオンチャンネル (Na および Ca チャンネル) に連結
• NMDA 受容体
• AMPA 受容体
• KA 受容体
b) metabotropic 受容体
• L-AP 4 受容体
• ACPD 受容体
• その他
2. サブユニット構成
a) NMDA 受容体サブユニット (4 量体)
• NR1
• NR 2 A, NR 2 B, NR 2 C, NR 2 D (それぞれ NR 1 との組み合わせで発現)
b) AMPA 受容体サブユニット
• GluR1, GluR 2, GluR 3, GluR 4
c) KA 受容体サブユニット
• GluR 5, GluR 6, KA1, KA 2
d) metabotropic 受容体 (L-AP 4 受容体, ACPD 受容体など)
グループ I (mGluR1, mGluR 5)
Gq シグナル系: protein kinase C を介し, phosphatidylinositol 4,5-bisphosphate 水酸化促進
シナプス後膜に存在, 神経興奮閾値低下
グループ II (mGluR 2, mGluR 3) およびグループ III (mGluR 4, mGluR 6, mGluR 7, mGluR 8)
Gi/Go シグナル系: adenylate cyclase を抑制, シナプス前膜に存在, 神経伝達物質放出を抑制

(Baudry ら<sup>2)</sup>, 2001)

これらの受容体はいくつかのサブユニットの組み合わせによって構成されている (表 1 の 2)。NMDA 受容体については、グリシン結合部位, Na, Ca イオンチャンネル, Mg 結合部位などが解明されている。

グルタミン酸受容体を構成するサブユニット構成は年齢特異的であり, また, けいれんの結果変動することが知られている (表 2)<sup>3,4)</sup>。けいれんによる神経損傷の程度や抗てんかん薬の有効性が年齢依存性である理由のひとつとして, 年齢によるサブユニット構成の違いがあげられている。

けいれんによる過剰な神経電気活動時には, イオンチャンネルに連結した NMDA 受容体や AMPA/KA 受容体を介して細胞外 Ca<sup>++</sup>が細胞内に流入する。また, L-AP 4 受容体や ACPD 受容体などの metabotropic 受容体においては phosphatidylinositol 4,5-bisphosphate/protein kinase C 系を介して Ca<sup>++</sup>が小胞体より細胞質内へ

表 2 成長やけいれんに伴う受容体の变化

グルタミン酸受容体サブユニットの変化
1. 年齢による違い (Sanchez ら) <sup>3)</sup>
NMDA 受容体: 新生時期では NR 2 B が NR 2 A に比べて多い。NR 2 B を主体とする NMDA 受容体では NR 2 A を主体とする受容体に比べて興奮持続時間が長く, 細胞内への Ca 流入が多い。
AMPA/KA 受容体: 新生時期では大脳皮質・海馬で GluR 2 が少ない。GluR 2 を欠く AMPA/KA 受容体では Ca 透過性が比較的高い。
2. けいれん後の変化 (Treiman ら) <sup>4)</sup>
海馬における mGluR 2/3, mGluR 5 の増加
海馬 CA1, CA 3 領域における GluR 2 の減少

放出される。通常は, エネルギー依存性ポンプによる Ca<sup>++</sup>の細胞外への排出および Ca/Mg ATPase を介する小胞体への取り込み促進によって細胞質内 Ca<sup>++</sup>濃度は適正に保たれている。しかし, 低血糖や虚血においてはエネルギー不足により細胞質内 Ca<sup>++</sup>濃度が上昇, さらに活性酸素やフリーラジカルなどが関与して細胞傷害が生じると考えられている<sup>5)</sup>。

Ca<sup>++</sup>による細胞傷害の発生機序については専門書を参照されたい。

#### まとめ

けいれん時に起こる広義の脳代謝異常, すなわち低酸素血症などによるエネルギー異常, および特異的代謝異常, すなわち興奮性アミノ酸の過剰による細胞質内イオン, とくに Ca<sup>++</sup>濃度の変動と神経細胞傷害について簡単にまとめた。とくに, グルタミン酸過剰刺激による神経細胞傷害については, けいれんに続発する脳障害を予防するために今後さらなる検討が進められると思われる。

#### 文献

- 1) Wasterlain CG, Mazarati AM, Naylor D, et al: Short-term plasticity of hippocampal neuropeptides and neuronal circuitry in experimental status epilepticus. *Epilepsia* 43 (Suppl 5): 20-29, 2002
- 2) Baudry M, Bi X: Neurotransmitters and Receptors. In Wyllie E (ed): *The Treatment of Epilepsy. Principles and practice*, Lippincott Williams and Wilkins, Philadelphia, pp 25-32, 2001
- 3) Sanchez RM, Jensen FE: Maturational aspects of epilepsy mechanisms and consequences for the im-

mature brain. *Epilepsia* 42 : 577-585, 2001

- 4) Treiman DM : Therapy of status epilepticus in adults and children. *Curr Opin Neurol* 14 : 203-210, 2001

- 5) Heinemann U, Buchheim K, Gabriel S, et al : Coupling of electrical and metabolic activity during epileptiform discharges. *Epilepsia* 43 (Suppl 5) : 168-173, 2002

\* \* \*



ELSEVIER

Brain & Development 26 (2004) 542–544

**BRAIN &  
DEVELOPMENT**

Official Journal of  
the Japanese Society  
of Child Neurology

www.elsevier.com/locate/braindev

### Case report

## Acute dysautonomia: complete recovery after two courses of IVIg

Mamiko Ishitobi\*, Kazuhiro Haginoya, Taro Kitamura, Mitsutoshi Munakata,  
Hiroyuki Yokoyama, Kazuie Inuma

*Department of Pediatrics, Tohoku University School of Medicine, 1-1 Seiryō-machi, Aoba-ku, Sendai 980-8574, Japan*

Received 17 June 2003; received in revised form 2 February 2004; accepted 24 February 2004

#### Abstract

An 11-year-old boy presented with acute dysautonomia manifesting as severe orthostatic hypotension following fever. Serial orthostatic tests with measurement of the coefficient of variation in the R–R intervals showed improvement after one course and complete recovery after two courses of intravenous high-dose immunoglobulin therapy (IVIg). Repeated courses of IVIg should be considered to treat this disorder if spontaneous remission does not occur.

© 2004 Elsevier B.V. All rights reserved.

**Keywords:** Acute dysautonomia; Orthostatic hypotension; Intravenous high-dose immunoglobulin therapy

Acute dysautonomia is a rare disorder, characterized by acute dysfunction of the autonomic nervous system with a history of preceding infection [1,2]. Acute dysautonomia has recently been recognized as a type of neuroimmunologic disorder. The pathogenesis remains unclear, but may involve acute inflammatory neuropathy caused by an immune mediated mechanism, similar to Guillain–Barré syndrome [2,3]. Recovery from acute dysautonomia tends to be gradual and frequently incomplete, and early therapeutic intervention is necessary in patients with progressive disability [1,2]. Acute dysautonomia has been successfully treated with intravenous high-dose immunoglobulin therapy (IVIg) [4–8]. We treated an 11-year-old boy who developed severe orthostatic hypotension after an episode of fever and recovered after two courses of IVIg.

#### 1. Case report

A previously healthy 11-year-old boy developed high fever of 40 °C in September 2001 (Fig. 1). He complained of headache and dizziness at that time. His condition was treated as a common cold. The fever ceased 3 days later, but he suffered from sustained dizziness. Blood tests showed no abnormalities, but his blood pressure decreased from

88/46 mmHg to 68/42 mmHg at 4 min after standing. The diagnosis was orthostatic hypotension. He was treated with vasopressors, anti-inflammatory drugs, antidepressants, etc., but with no effect. Two months after the onset, he was referred to our hospital for further evaluation and treatment.

Serial measurements of the coefficient of variation in the R–R intervals (CVR–R) were made using a multi-function electrocardiograph (FDX-4520; Fukuda Denshi, Japan) during the orthostatic test monitored with a continuous non-invasive blood pressure tonometry system (JENTOW-7700; Colin Corporation, Japan). The orthostatic test was performed after resting for more than 15 min, and systolic and diastolic blood pressures were recorded every 10 to 15 s. The CVR–R was also measured at rest.

The orthostatic test demonstrated severe orthostatic hypotension (Fig. 2a). Immediately after standing, his heart rate suddenly rose to 140 beats/min, and his systolic blood pressure to higher than 140 mmHg. Seven minutes later, the systolic blood pressure sharply fell to lower than 80 mmHg, and he felt dizziness and loss of vision, and was unable to remain standing. He then lay down, but his heart rate and blood pressure did not recover to those measured before standing for 13 min. CVR–R was severely low at 2.05% (normal lower limit 3.0% in control subjects aged 10–19 years old) (Fig. 1).

He had a good appetite, and had no constipation or diarrhea. His hands were always cold and wet, but physical examination demonstrated no other abnormalities. He had no

\* Corresponding author. Fax: +81-22-717-7290.  
E-mail address: mamiko@ped.med.tohoku.ac.jp (M. Ishitobi).

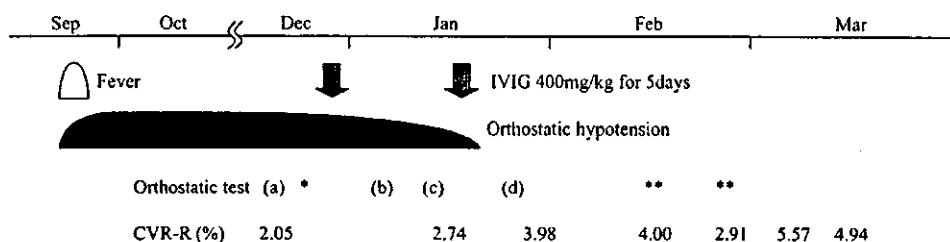


Fig. 1. Clinical course and timing of orthostatic tests and treatment. Coefficient of variation in the R-R intervals (CVR-R) showed gradual improvement after two courses of intravenous high-dose immunoglobulin therapy. As for orthostatic tests, \* showed similar pattern to (a), and \*\* to (d). Refer to the results of orthostatic tests in Fig. 2.

vesicorectal problems. Neurological examination also demonstrated no abnormalities, including the cranial nerves, motor and sensory systems, and deep tendon reflexes. The ocular fundi were also normal. Motor and sensory nerve conducting velocities in the median nerves were within the normal range. Metaiodobenzylguanidine scintigraphy, which utilizes the noradrenaline analog metaiodobenzylguanidine for detection of autonomic dysfunction in the heart, showed no abnormalities. No abnormalities were found in blood and urine tests, including serum levels of

antiganglioside antibodies. Cerebrospinal fluid (CSF) testing on admission showed normal levels of protein (18 mg/dl) and cell count (1/ $\mu$ l). Blood examination showed that immunoglobulin G antibody for human herpes virus 6 (HHV-6) was highly positive (1:160, normal < 1:10), and immunoglobulin M antibody for HHV-6 and polymerase chain reaction amplification of HHV-6 deoxyribonucleic acid were negative. Other virus antibody titers were negative.

The diagnosis was acute dysautonomia. He was treated with IVIg (400 mg/kg body weight for five consecutive

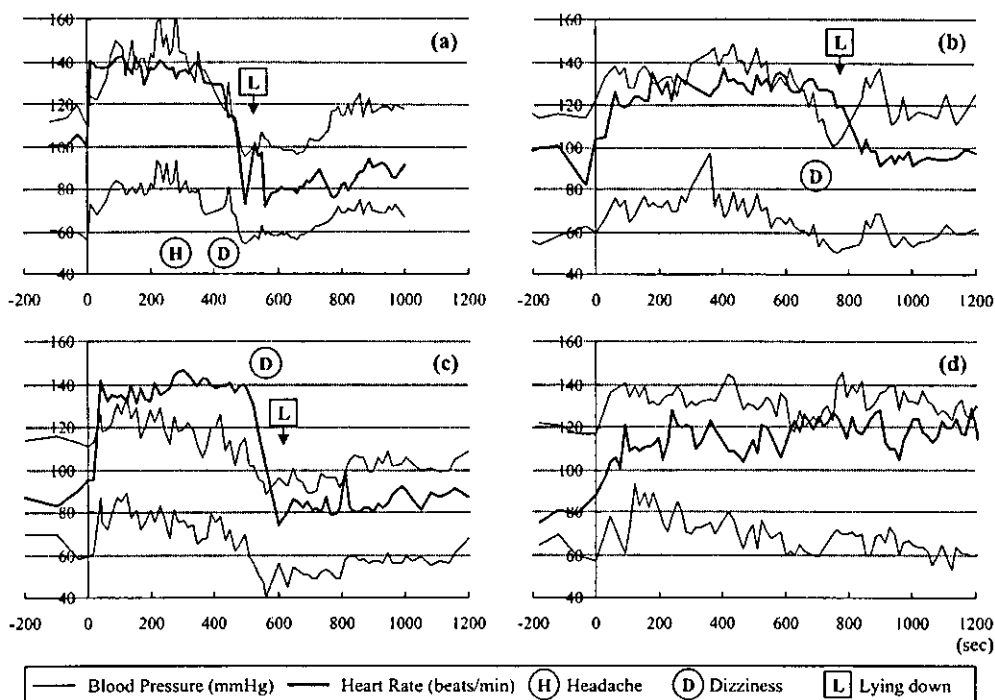


Fig. 2. Results of orthostatic tests. The timing of orthostatic tests was shown in Fig. 1. (a) Before treatment, the orthostatic test showed severe orthostatic hypotension, with sudden rises in blood pressure and heart rate immediately after standing, followed by impulsive falls in both 7 min after standing. Recovery of blood pressure and heart rate was poor after lying down. (b) The orthostatic test showed slight improvement after one course of intravenous high-dose immunoglobulin therapy, when he could remain standing for as long as 13 min. Changes in blood pressure and heart rate were less severe than before treatment, and recovery after lying down was prompt. (c) One week later, the orthostatic test showed a similar pattern to that before treatment. (d) The orthostatic test showed complete recovery after a second course of treatment.

days). The orthostatic test then showed his condition had slightly improved (Fig. 2b). He could remain standing for as long as 13 min. The changes in blood pressure and heart rate were less severe than before treatment, and recovery after lying down was prompt. However, one week later, the orthostatic test showed similar results to those before treatment (Fig. 2c), and CVR–R was still abnormally low at 2.74%. Another course of IVIg was given. The orthostatic test showed complete recovery (Fig. 2d) and the CVR–R returned to normal values (3.98%) (Fig. 1). He has had no complaints for more than one year.

## 2. Discussion

Acute dysautonomia can be considered as an uncommon variant of Guillain–Barré syndrome [5–8], because of the relatively common association of autonomic symptoms in Guillain–Barré syndrome, and because of the elevation of CSF protein in acute dysautonomia [6–8]. The level of CSF protein in our patient was normal, but the absence of any abnormality might be due to the late timing of the CSF examination, two months after the onset.

Our patient required two courses of IVIg to resolve his symptoms. The orthostatic test showed only slight improvement after the first course. Only one week later, the orthostatic test showed worsening of the symptoms and abnormally low CVR–R. However, temporary improvement was apparently observed after the first course, and a few reports have suggested that two courses of IVIg are necessary for effectiveness in cases of Guillain–Barré syndrome [9,10]. He showed complete and permanent recovery after the second course of treatment. The present case indicates that a second course of IVIg should be considered in patients with severe acute dysautonomia, especially if signs of improvement are observed after the first course.

Serial measurements of CVR–R and the orthostatic test using a tonometry system were useful for the evaluation of autonomic function in a child with acute dysautonomia. These methods are non-invasive and easy to carry out even in pediatric patients.

## References

- [1] Young RR, Asbury AK, Corbett JL, Adams RD. Pure pandysautonomia with recovery. Description and discussion of diagnostic criteria. *Brain* 1975;98:613–36.
- [2] Suarez GA, Fealey RD, Camilleri M, Low PA. Idiopathic autonomic neuropathy: clinical, neurophysiologic, and follow-up studies on 27 patients. *Neurology* 1994;44:1675–82.
- [3] Vernino S, Low P, Fealey RD, Stewar JD, Farrugia G, Lennon VA. Autoantibodies to ganglionic acetylcholine receptors in autoimmune autonomic neuropathies. *N Engl J Med* 2000;343:847–55.
- [4] Heafield MT, Gammage MD, Nightingale S, Williams AC. Idiopathic dysautonomia treated with intravenous gammaglobulin. *Lancet* 1996;347:28–9.
- [5] Mericle RA, Triggs WJ. Treatment of acute pandysautonomia with intravenous immunoglobulin. *J Neurol Neurosurg Psychiatry* 1997;62:529–31.
- [6] Feldman EL, Bromberg MB, Blaivas M, Junck L. Acute pandysautonomic neuropathy. *Neurology* 1991;41:746–8.
- [7] Quan D, Rich MM, Bird SJ. Acute idiopathic dysautonomia: electrophysiology and response to intravenous immunoglobulin. *Neurology* 2000;54:770–1.
- [8] Meilof JF, Kwa VI, Vermeulen M, Tiessens G. Isolated ataxia and autonomic dysfunction: a new variant of Guillain–Barré syndrome? *J Neurol Neurosurg Psychiatry* 1998;64:689.
- [9] Farcas P, Avnun L, Frisher S, Herishanu YO, Wirguin I. Efficacy of repeated intravenous immunoglobulin in severe unresponsive Guillain–Barré syndrome. *Lancet* 1997;350:1747.
- [10] Ohtsuka T, Munakata M, Kato R, Yokoyama H, Haginoya K, Iinuma K, et al. A child with Guillain–Barré syndrome with successful treatment with two series of high-dose IVIG (in Japanese). *Shonika Rinsho* 2000;53:1819–23.



## Clinical efficacy of zonisamide in childhood epilepsy after long-term treatment: a postmarketing, multi-institutional survey

Kazuie Iinuma\*, Kazuhiro Haginoya

Department of Pediatrics, Tohoku University School of Medicine, 1-1 Seiryō-machi, Aoba-ku, Sendai, Miyagi 980-8574, Japan

### KEYWORDS

Zonisamide;  
Epilepsy;  
Japan;  
Pediatric;  
Efficacy

**Summary** Postmarketing data about the effectiveness of zonisamide in childhood epilepsy was collected from 759 children with various forms of epilepsy (ages 3 months–15 years) to compare the long-term efficacy of zonisamide in the treatment of epilepsy in intellectually normal versus intellectually disabled children. The follow-up period was 6 months–3 years; 291 children (245 intellectually normal, 46 intellectually disabled) received zonisamide as monotherapy. The remaining patients received additional antiepilepsy drugs (AEDs); mean numbers of additional AEDs were 1.6 and 2.9 for intellectually normal and intellectually disabled groups, respectively. Effectiveness could not be evaluated in 30 of the 759 patients because of very rare or irregular seizure frequency. In the 729 patients evaluated, 78% of intellectually normal patients and 43% of intellectually disabled patients showed  $\geq 50\%$  reduction in the number of seizures ( $P < 0.001$ ). Improvement rates seen in the intellectually normal group were almost the same for patients with generalized (82%) and partial (77%) epilepsies, whereas in the intellectually disabled group, the improvement rate was higher for partial (50%) than generalized (36%) epilepsies ( $P < 0.01$ ).

These results are consistent with the known phenomenon that intellectually disabled children are likely to have more intractable seizures than children with normal intelligence.

© 2004 Published by Elsevier Ltd on behalf of BEA Trading Ltd.

### Introduction

Zonisamide is a new drug with broad-spectrum antiepilepsy activity against partial as well as generalized seizures. The drug has been commercially licensed in Japan since 1989. Before licensure, randomized, controlled trials of zonisamide were

performed by 4 authors;<sup>1–4</sup> 3 studies were of treatment in adults,<sup>1–3</sup> and 1 study examined pediatric treatment.<sup>4</sup> The observation period of these studies was 12–16 weeks in adults, and 8 weeks in children. All studies were confined to zonisamide treatment of generalized seizures. Postmarketing research, performed at 25 institutions over a 5-year period, investigated the clinical effectiveness and safety of zonisamide for the treatment of childhood epilepsy. The purpose of this postmarketing study was to compare the long-term efficacy of zonisamide in the treatment of epilepsy in intellectually nor-

\*Corresponding author. Tel.: +81 22 717 7284;  
fax: +81 22 717 7290.  
E-mail address: kiinuma@ped.med.tohoku.ac.jp (K. Iinuma).

mal children to that in intellectually disabled children.

## Methods

### Patients and study design

A total of 759 patients were included in the study. All were under 15 years of age. Ages of patients distributed as follows: less than 1 year, 20 patients (3%); 1–5 years, 213 patients (28%); 6–10 years, 282 patients (37%); and 11–15 years, 244 patients (32%). Of the study subjects, 418 were evaluated as intellectually normal, and 341 were intellectually disabled, with scores less than 50 based on their intelligent quotient (IQ) or development quotient (DQ). The IQ was evaluated by Tanaka-Binet method (Japanese edition of the Stanford-Binet Intelligence Scale), and in a few cases, by Wechsler Intelligence Scale for Children—Revised. The DQ was evaluated by the Tsumori-Inage method and Enjoji method (both are evaluated by interviewing parents, similar to the Denver Developmental Screening Test). The observation period of the study was between 6 months and 5 years.

Overall improvement in seizure control was evaluated in both the intellectually normal and the intellectually disabled groups. In the intellectually normal group, approximately 15% of patients had temporal lobe epilepsy and approximately 55% had non-temporal lobe epilepsy. Generalized epilepsies were found in less than 20% of this group. In contrast, in intellectually disabled patients, approximately 7% had temporal lobe epilepsy and 35% non-temporal lobe epilepsy. Generalized epilepsy was found in almost one-half of this study group's subjects.

A total of 729 patients out of the initial 759 patients were included in the final evaluation. Thirty patients were eliminated from analysis because of loss to follow-up due to adverse effects, change of address, too few seizures to evaluate, or other reasons. Of the intellectually normal group, 401 patients completed the study; of the intellectually disabled group, 328 completed the study (Table 1).

**Table 2** Number of AEDs.

Number of AEDs	Number of patients
Intellectually normal (mean 1.6)	
Zonisamide monotherapy	245 (61%)
2 AEDs	112 (28%)
3 AEDs	44 (11%)
4 AEDs	12 (3%)
Intellectually disabled (mean 2.9)	
Zonisamide monotherapy	46 (14%)
2 AEDs	67 (20%)
3 AEDs	128 (39%)
4 AEDs	64 (20%)
5 AEDs	32 (10%)

### Evaluation of safety and efficacy

The efficacy of zonisamide in the treatment of seizures was evaluated on the basis of improvement over a minimum 5-month period of observation following the initiation of treatment. Patients who were observed less than 5 months were not included in the efficacy analysis. Statistical analysis was performed using the chi-square method. Doses of zonisamide varied from 2 mg/kg per day to more than 10 mg/kg per day, and about 70% of patients received 2–8 mg/kg per day of zonisamide.

Zonisamide was regarded as effective for seizure control if the seizure frequency was reduced by  $\geq 50\%$  compared to baseline seizure frequency measured before treatment began. The improvement rate was defined as the percentage of the total number of patients meeting this efficacy standard. Adverse effects were recorded for all patients.

Sixty-one percent of the patients in the intellectually normal group were treated with zonisamide monotherapy (Table 2). Twenty-eight percent of the patients were treated with zonisamide and 1 other antiepilepsy drug. In contrast, zonisamide monotherapy was given to only 14% of the patients in the intellectually disabled group. Zonisamide was given together with 2 other antiepilepsy drugs

**Table 1** Number of patients (final evaluation).

	Epilepsies			Total
	Generalized	Partial	Unclassified	
Intellectually normal	67	331	3	401
Intellectually disabled	152	170	6	328
Total	219	501	9	729

Thirty patients were excluded because of interruption of follow-up by adverse effects, changes of address, etc.

in 39% of this group's patients. The mean number of AEDs, including zonisamide, was 1.61 in the intellectually normal group and 2.94 in the intellectually disabled group.

## Results

### Efficacy

The overall improvement rating for generalized seizures is shown in Table 3. The characteristics of the seizures were different for the 2 groups. Generally speaking, improvement was significantly beneficial for persons of normal intelligence (80%,  $P < 0.001$ ), notably for tonic (89%,  $P < 0.001$ ), and generalized tonic-clonic seizures (87%,  $P < 0.01$ ), as well as other seizure types (80%,  $P < 0.05$ ). For all categories of partial seizures, the improvement

**Table 3** Overall improvement rating: generalized seizures.

Seizure type	Improved (reduction $\geq 50\%$ of seizure frequency)	
	Intellectually normal	Intellectually disabled
Absence	3/4 (75%)	None
Atypical absence	4/8 (50%)	6/19 (32%)
Myoclonic seizure	3/6 (50%)	23/43 (53%)
Tonic seizure	16/18 (89%) <sup>***</sup>	28/77 (36%)
GTC	26/30 (87%) <sup>**</sup>	21/37 (57%)
Others	19/23 (83%) <sup>*</sup>	14/28 (50%)
Total	71/89 (80%) <sup>***</sup>	92/204 (45%)

\* $P < 0.05$ , \*\* $P < 0.01$ , \*\*\* $P < 0.001$  between the intellectually normal and the intellectually disabled groups, respectively; GTC = generalized tonic-clonic.

**Table 4** Overall improvement rating: partial seizures.

Seizure type	Improved (reduction $\geq 50\%$ of seizure frequency)	
	Intellectually normal	Intellectually disabled
SPS	73/89 (82%) <sup>***</sup>	27/39 (69%)
CPS	146/170 (86%) <sup>***</sup>	74/123 (60%)
SGS	131/150 (87%) <sup>***</sup>	70/103 (68%)
Others	11/13 (85%) <sup>***</sup>	3/5 (60%)
Total	361/422 (86%) <sup>***</sup>	174/270 (64%)

SPS = simple partial seizure; CPS = complex partial seizure; SGS = secondarily generalized seizure.  
<sup>\*\*\*</sup> $P < 0.001$  between the intellectually normal and intellectually disabled groups.

rating was significantly higher ( $P < 0.001$ ) in the intellectually normal group (86%) than in the intellectually disabled group (64%) (Table 4).

Table 5 compares the improvement rating according to the classification of epilepsy syndromes. The improvement rating was higher ( $P < 0.001$ ) in the intellectually normal group (78%) than in the intellectually disabled group (43%). In the intellectually disabled group, patients with partial epilepsy showed a slightly better response than those with generalized epilepsy (50% versus 36%,  $P < 0.01$ ).

Table 6 shows the improvement rating for patients with various types of generalized epilepsies. Primary generalized epilepsy was better controlled by zonisamide ( $P < 0.001$ ) in intellectually normal patients (91%) than in intellectually disabled patients (58%). The improvement rating data for partial epilepsies is shown in Table 7. Only temporal lobe epilepsy did not show a significant difference in the improvement rating between the 2 groups.

**Table 5** Overall improvement rating.

	Syndrome	Improved	Unimproved	Total
Intellectually normal	Generalized	55 (82%) <sup>***</sup>	12 (18%)	67 (100%)
	Partial	256 (77%)	75 (23%)	331 (100%)
	Unclassified	3 (100%)	0 (0%)	3 (100%)
	Total	314 (78%) <sup>***</sup>	87 (22%)	401 (100%)
Intellectually disabled	Generalized	54 (36%)	98 (64%)	152 (100%)
	Partial	85 (50%)	85 (50%)	170 (100%)
	Unclassified	2 (33%)	4 (67%)	6 (100%)
	Total	141 (43%)	187 (57%)	328 (100%)

<sup>\*\*\*</sup> $P < 0.001$  between the intellectually normal and the intellectually disabled groups.



**Table 6** Overall improvement rating: generalized epilepsies.

	Epilepsies	Improved	Unimproved	Total
Intellectually normal	PGE	43 (91%) <sup>***</sup>	4 (9%)	47 (100%)
	West syndrome	1 (100%)	0	1 (100%)
	LGS	3 (50%)	3 (50%)	6 (100%)
	Other SGE	5 (56%)	4 (44%)	9 (100%)
	Unclassified GE	3 (75%)	1 (25%)	4 (100%)
	Total	55 (82%) <sup>***</sup>	12 (18%)	67 (100%)
Intellectually disabled	PGE	11 (58%)	8 (42%)	19 (100%)
	West syndrome	7 (33%)	14 (67%)	21 (100%)
	LGS	7 (21%)	26 (79%)	33 (100%)
	Other SGE	26 (40%)	39 (60%)	65 (100%)
	Unclassified GE	3 (21%)	11 (79%)	14 (100%)
	Total	54 (36%)	98 (64%)	152 (100%)

PGE = primary generalized epilepsy; LGS = Lennox-Gastaut syndrome; SGE = secondarily generalized epilepsy; GE = generalized epilepsy.

<sup>\*\*\*</sup>  $P < 0.001$  between the intellectually normal and the intellectually disabled groups.

**Table 7** Overall improvement rating: partial epilepsies.

	Epilepsies	Improved	Unimproved	Total
Intellectually normal	TLE	36 (65%)	19 (35%)	55 (100%)
	Non-TLE	177 (79%) <sup>***</sup>	47 (21%)	224 (100%)
	Others	43 (83%) <sup>***</sup>	9 (17%)	52 (100%)
	Total	256 (77%) <sup>***</sup>	75 (23%)	331 (100%)
Intellectually disabled	TLE	12 (50%)	12 (50%)	24 (100%)
	Non-TLE	61 (51%)	59 (49%)	120 (100%)
	Others	12 (46%)	14 (54%)	26 (100%)
	Total	85 (50%)	85 (50%)	170 (100%)

TLE = temporal lobe epilepsy.

<sup>\*\*\*</sup>  $P < 0.001$  between the intellectually normal and the intellectually disabled groups.

Table 8 shows the relationship between improvement rates and age of epilepsy onset. In any age group, the improvement rating was greater ( $P < 0.001$ ) in the intellectually normal group (78%) than in the intellectually disabled group (43%).

### Safety

Adverse effects were experienced by 21% of the intellectually normal patients, and by 28% of the intellectually disabled patients (see Table 9). The

**Table 8** Overall improvement rating.

Age of onset (years)	Improved (reduction $\geq 50\%$ of seizure frequency)		
	Intellectually normal	Intellectually disabled	Total
<1	12/14 (86%)	1/6 (17%)	13/20 (65%)
1–5	60/83 (72%)	52/120 (43%)	112/203 (55%)
6–10	140/170 (82%)	46/100 (46%)	186/270 (69%)
11–15	102/134 (76%)	42/102 (41%)	144/236 (61%)
Total	314/401 (78%) <sup>***</sup>	141/328 (43%)	455/729 (62%)

<sup>\*\*\*</sup>  $P < 0.001$  between the intellectually normal and the intellectually disabled groups.

**Table 9** Adverse effects of zonisamide.

	Patients experiencing adverse effects (%)	Patients experiencing no adverse effect (%)	Total
Intellectually normal	86 (21%)	332 (79%)	418 (100%)
Intellectually disabled	96 (28%)	245 (72%)	341 (100%)
Total	182 (24%)	577 (76%)	759 (100%)

**Table 10** Adverse effects of zonisamide: monotherapy vs. combination therapy.

Age of onset (years)	Zonisamide monotherapy	Zonisamide combination therapy	Total
<1	2/14 (14%)	3/6 (50%)	5/20 (25%)
1-5	13/71 (18%)	34/142 (24%)	47/213 (22%)
6-10	15/112 (13%)	48/170 (28%)	63/282 (22%)
11-15	14/70 (20%)	53/174 (30%)	67/244 (27%)
Total	44/267 (16%) <sup>***</sup>	138/492 (28%)	182/759 (24%)

<sup>\*\*\*</sup>  $P < 0.001$  (monotherapy vs. combination therapy).

incidence of adverse events was slightly higher in the intellectually disabled group, but there is no significant difference between these groups. In total, 24% of the 759 patients in this study experienced some adverse effects.

In Table 10, a comparison of adverse events observed with zonisamide monotherapy (16%) versus combined therapy (28%) demonstrates that fewer adverse effects were observed in the monotherapy group ( $P < 0.001$ ). There were no significant differences in adverse events between age groups, except that in the combined therapy group of patients under 1 year of age, the incidence of adverse effects was increased (50%).

## Discussion and conclusions

Before the commercial licensing of zonisamide in Japan, a placebo-controlled study in children showed that the percentage of patients with a 50% or higher decrease in seizure frequency was 50.0% and 43.8%, by zonisamide and valproate, respectively.<sup>4</sup> This study was done by 8 weeks of observation. Our study of long-term observation showed that the overall improvement rate was 62%, which was slightly higher than the placebo-controlled study results. The patients evaluated before launch had more frequent seizures—more than 4 times a month. After commercial licensing, zonisamide was also administered to many patients having infrequent seizures. The difference of the efficacy of zonisamide before and after the licensure is likely due to the background seizure

frequency of the patients. In intellectually normal children, the overall improvement rate was thought to be quite high (78%); furthermore, patients with generalized epilepsy in the intellectually normal group showed 82% improvement.

It has generally been thought that zonisamide is more efficacious for partial epilepsy than generalized epilepsy.<sup>5</sup> It was reported that patients who had some temporal lobe abnormalities verified by EEG, computed tomography, or positron emission tomography responded well to zonisamide.<sup>6</sup> In that report, zonisamide was effective for partial epilepsy as well as generalized epilepsy with temporal lobe lesions. In the present study, however, zonisamide demonstrates efficacy for generalized epilepsy equal to or greater than its efficacy for partial epilepsy. The patients with generalized epilepsy who responded well to zonisamide might have had some temporal lobe abnormalities.

In comparing the efficacy of zonisamide for intellectually normal and disabled patients, zonisamide was more effective for intellectually normal patients. In general, intellectually disabled children have various kinds of central nervous system disturbances. These disturbances relate to the severity of seizures in epileptic patients with intellectual disability. However, even for intellectually disabled patients, zonisamide had good efficacy for seizure control. Zonisamide can be recommended for the treatment of both partial and generalized seizures in intellectually disabled children with epilepsy.

Treatment-emergent adverse effects were observed to have almost the same incidence in the normal intelligence and the intellectually disabled

groups. Zonisamide monotherapy demonstrated less frequent adverse effects than zonisamide combined therapy. Combined antiepilepsy therapy often induces adverse effects more frequently in any antiepilepsy drug, not only zonisamide.<sup>7</sup>

In the treatment of epileptic children with zonisamide, anhidrosis accompanied by elevated body temperature has been reported, especially during summer.<sup>8,9</sup> Moreover, Shimizu et al. reported a case of an intellectually disabled 2-year-old boy demonstrating a heat stroke-like episode associated with zonisamide treatment.<sup>10</sup> This patient showed hyperpyrexia and oligohidrosis. In the present study, cases with anhidrosis were not reported by the doctors. However, anhidrosis or oligohidrosis is often difficult to observe, especially by intellectually disabled patients. Hyperpyrexia and oligohidrosis should be carefully monitored during zonisamide treatment.

## References

1. Seino M, Ohkuma T, Miyasaka M, et al. Evaluation of the drug efficacy of AD-810 (zonisamide). Results of double-blind study in comparison with carbamazepine (in Japanese). *J Clin Exp Med* 1988;144:275-91.
2. Schmidt D, Jacob R, Loiseau P, et al. Zonisamide for add-on treatment of refractory partial epilepsy: a European double-blind trial. *Epilepsy Res* 1993;15:67-73.
3. Wilder BJ, Ramsay RE, Browney T, Sackellares JC. A multicenter double-blind, placebo controlled study on zonisamide on medically refractory patients with complex seizures. *Epilepsia* 1985;26:545.
4. Oguni H, Hayashi K, Fukuyama Y, Iinuma K. Phase III study of a new antiepilepsy AD-810, zonisamide in childhood epilepsy (in Japanese). *Jpn J Pediatr* 1988;41:439-50.
5. Yamatogi Y, Ohtahara S. Current topics of treatment. In: Ohtahara S, Roger J, editors. *New trends in pediatric epileptology*. 1991. p. 136-48.
6. Iinuma K, Handa I, Fueki N, Yamamoto K, Kojima A, Haginoya K. Effects of zonisamide (AD-810) on refractory epilepsy in children: special reference to temporal lobe abnormalities. *Curr Ther Res* 1988;43:281-90.
7. Guberman A. Monotherapy or polytherapy for epilepsy? *Can J Neurol Sci* 1998;25:S3-8.
8. Fujita Y, Okubo O, Noguchi Y, Nishimura A, Fuchigami T, Harada K. Zonisamide-induced hidropoietic disorder in patients with childhood epilepsy. *J Nihon Univ Med Assoc* 1995;54:658-62.
9. Okumura A, Hayakawa F, Kuno K, Watanabe K. Oligohidrosis caused by zonisamide. *No To Hattatsu* 1996;28:44-7 (in Japanese).
10. Shimizu T, Yamashita Y, Sato M, et al. Heat stroke-like episode in a child caused by zonisamide. *Brain Dev* 1997;19:366-8.

## Clinical Research

# Dynamic Cortical Activity during Spasms in Three Patients with West Syndrome: A Multichannel Near-infrared Spectroscopic Topography Study

Mitsutoshi Munakata, Kazuhiro Haginoya, Mamiko Ishitobi, Osamu Sakamoto, Ikuko Sato, Taro Kitamura, Mieko Hirose, Hiroyuki Yokoyama, and Kazuie Inuma

Department of Pediatrics, Tohoku University School of Medicine, Sendai, Japan

**Summary:** *Purpose:* To investigate spatial and temporal cortical activity during clusters of naturally occurring epileptic spasms in patients with West syndrome (WS) by using multichannel near-infrared spectroscopy (mNIRS).

*Methods:* Conventional magnetic resonance imaging (MRI) and interictal and ictal single-photon emission computed tomography (SPECT) were carried out in three patients with WS. Thereafter, cortical hemodynamics during naturally occurring epileptic spasms were measured by mNIRS with simultaneous video/electroencephalographic (EEG) monitoring.

*Results:* Ictal SPECT revealed multiple hyperperfused areas within the cortex. With the use of mNIRS, an increase in regional cerebral blood volume (CBV) was observed in these areas, which is representative of cortical activation. The increase in CBV was accompanied by an increase in the concentrations of

both oxy- and deoxyhemoglobin. The following heterogeneous regional changes in CBV during ictus were observed: (a) transient increases that were synchronized with spasms; (b) a gradual increase during an ictal event that fluctuated in synchrony with spasms; and (c) a combination of transient and gradual increases. An increase in regional CBV occurred in multiple areas that were activated either simultaneously or sequentially during an ictal event. Topographic changes in CBV were closely correlated with the phenotype of the spasm.

*Conclusions:* During ictal events, multiple cortical areas were activated simultaneously or sequentially. The pattern of cortical activation closely affected the phenotype of the spasm, which suggested that the cortex was involved in the generation of spasms. **Key Words:** West syndrome—Infantile spasm—Near-infrared spectroscopy.

West syndrome (WS) is an age-dependent epileptic syndrome that occurs during infancy. WS is characterized by clustering epileptic spasms, electroencephalographic (EEG) hypsarrhythmia, and arrested psychomotor development (1,2). Although the pathophysiology of WS remains unknown, subcortical structures such as the lentiform nuclei and brainstem are thought to be involved (3,4). In addition, magnetic resonance imaging (MRI) and functional neuroimaging have revealed that a considerable number of children with WS possess focal cortical abnormalities (5–7). Surgical resection of the affected area can eliminate the spasms (8), suggesting (at least in such patients) that the abnormal cortex may play a crucial role in the pathogenesis of spasms in patients with WS.

Positron emission tomography (PET) and single-photon emission computed tomography (SPECT) have suggested that abnormal cortical areas are hyperperfused during ictal periods, implying that these areas of the cortex are activated during a cluster of spasms (9,10). However, because of the insufficient time resolution of PET and SPECT for rapidly progressing and repeatedly occurring spasms, it is impossible to discriminate between the cerebral perfusion changes during spasms and those at intervals of spasms, and postictal changes might contaminate the results. A different neuroimaging modality with superior time resolution is thus required to delineate the time course of cortical activity during the progression of the ictal events of WS.

Recently, multichannel near-infrared spectroscopy (mNIRS) has been used to investigate higher brain function because changes in regional cerebral blood volume (CBV), which can be measured by using mNIRS, are correlated closely with the topology of cortical activity (11,12). The relatively good time resolution of mNIRS

Accepted June 6, 2004.

Address correspondence and reprint requests to Dr. M. Munakata at Department of Pediatrics, Tohoku University School of Medicine, 1-1 Seiryō-machi, Aoba-ku, Sendai 980-8574, Japan. E-mail: muna@ped.med.tohoku.ac.jp

TABLE 1. Clinical characteristics of patients

	Case 1	Case 2	Case 3
Sex	female	female	male
Gestational age at birth (weeks)	35	37	40
Age (months) at onset	3	7	5
Age (months) at examination	3	8	6
Seizure type	symmetrical spasms followed by asymmetrical spasms (L>R)	asymmetrical spasms (L>R) followed by symmetrical spasms	partial seizure followed by symmetrical spasms

overcomes the aforementioned limitation of PET and SPECT, and therefore it might be a useful method for observing spatial and temporal changes in cortical activity during ictus in patients with epilepsy (13). Here, we used mNIRS to assess the involvement of the cerebral cortex in ictal events in patients with WS.

## METHODS

### Patients

We studied three patients with WS. The clinical characteristics of the patients are summarized in Table 1.

#### Case 1

A girl (the first of twins) was born after 35 weeks of gestation; pregnancy and delivery were uncomplicated. The mother had Crohn's disease, but no family history of epilepsy was known. The first seizure occurred at age 3 months. During the ictal period, the girl exhibited brief extension of the upper and lower limbs, which was associated with upward rolling of the eyes. Initially, the spasms were symmetrical but became asymmetrical toward the end of a cluster in association with weak extension of the left upper limbs. An interictal EEG recording revealed hypsarrhythmia. The results of conventional MRI, retinal observation, and blood analyses (including lactate and amino acid analyses) were normal. Despite treatment for 2 weeks with vitamin B<sub>6</sub> and valproate (VPA), the infantile spasms remained. Although subsequent treatment with adrenocorticotrophic hormone (ACTH) eliminated the spasms and the hypsarrhythmia, a brief tonic seizure without clustering occurred 1 month later.

#### Case 2

A girl was born after 37 weeks of gestation; pregnancy was uncomplicated. The first seizure was noted at age 7 months. During the ictal period, the girl exhibited brief spasms in clusters. Hypsarrhythmia was noted in an EEG recording. Vitamin B<sub>6</sub> and VPA were found to be ineffective, and she was referred to our hospital at age 8 months. MRI revealed a small lesion of unknown etiology at the posterior lateral aspect of the left lateral ventricle, whereas retinal observation and blood analyses were normal. Then

ACTH treatment was carried out, and the spasms ceased, with an EEG improvement.

#### Case 3

A boy was born after 40 weeks of gestation; pregnancy was uncomplicated. The first seizure was noted at age 5 months. During the ictal period, he exhibited brief extension of the upper limbs with head-nodding. At age 6 months, he could no longer control the movements of his head, and he was referred to our hospital. Hypsarrhythmia was noted in an interictal EEG. The MRI, retinal observation, and metabolic parameters were normal. ACTH treatment was carried out after vitamin B<sub>6</sub> and VPA were found to be ineffective. After the ACTH treatment, the hypsarrhythmia disappeared, and the spasms ceased.

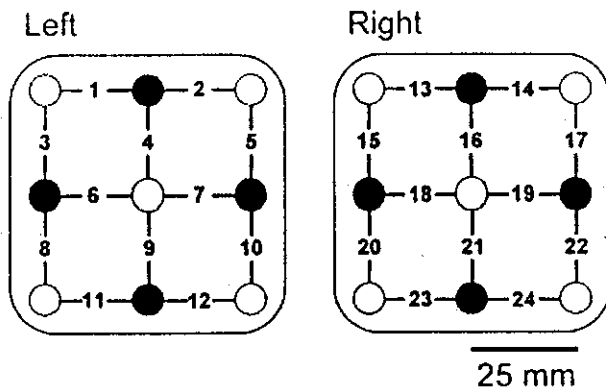
### Methods

Within 2 weeks of admission to the Tohoku University Hospital and before the initiation of ACTH therapy, interictal and ictal SPECT and ictal mNIRS with video-EEG monitoring were carried out in each of the three aforementioned patients. We received informed consent from the parents of the patients for the following examinations.

For ictal SPECT, as soon as the attending pediatrician noticed the occurrence of spasms, [<sup>99m</sup>Tc]-ethyl cysteinate dimer (ECD) was injected intravenously. The fixation of [<sup>99m</sup>Tc]-ECD within the brain after injection required several minutes (14). Because multiple spasms occurred during this period, the SPECT images obtained represented mixed cerebral blood flow (CBF) during the multiple spasms. For the interictal SPECT study, [<sup>99m</sup>Tc]-ECD was injected while the patient was conscious. Both ictal and interictal SPECT images were acquired at 30 min after the injection of [<sup>99m</sup>Tc]-ECD by using a MULTI-SPECT 3 (Siemens, Gerfahldt, Germany). The patient was sedated with diazepam (DZP) during the scanning. The method that we used to construct a tomogram of CBF has been described elsewhere (10).

NIRS is based on the fact that near-infrared light can propagate through biologic material with scattering, and the absorption during propagation is inversely related to hemoglobin (Hb) concentrations in tissues (15). By using two specific wavelengths of near-infrared light (see later), the relative changes in oxy- and deoxy-Hb concentrations can be calculated separately (11). The summation of oxy- and deoxy-Hb concentrations gives the change in total Hb (total-Hb) concentrations, which is representative of changes in CBV (16).

In the present study, a mNIRS system (ETG 100; Hitachi Medical Corporation, Tokyo, Japan) was used. After the placement of selected scalp electrodes for digital EEG monitoring (EEG2100; Nihon Kohden, Tokyo, Japan), two optode arrays for mNIRS were fixed to the scalp by using a tubular net bandage and surgical tape. Based on the SPECT results, the arrays were placed bilaterally symmetrically with the center of each array located approximately



**FIG. 1.** Configuration of optode arrays. Each array consisted of alternately arranged light-emitting (*solid circles*) and light-detecting (*open circles*) optodes. Absorption of near-infrared light (780 and 840 nm) was measured among adjoining emitting and detecting optodes, thereby producing 12 recording channels per hemisphere (channels 1–12, right hemisphere; 13–24, left hemisphere). The gray area illustrates the extent of the topographic image that was constructed by using spatial spline interpolation across the recording channels.

over the frontal or central area (10–20 system). The attachment for the arrays was fabricated specifically for infants to minimize discomfort (Hitachi Medical Corporation). Each array comprised four light-emitting and five light-detecting optodes that were arranged alternately with a spacing of 25 mm (Fig. 1). The absorption of backscattered light at wavelengths of 780 and 840 nm was measured between adjoining optodes, thereby producing 12 measurement channels per hemisphere. The sampling interval was 0.5 s. For off-line analysis, baseline values of oxy-, deoxy-, and total-Hb were aligned to the period that immediately preceded the ictal period (unless otherwise stated). Topographic images of the changes in regional CBV were constructed by using spline interpolation. The spatial resolution of the images was limited by interoptode distance.

## RESULTS

Figure 2A shows the results of the interictal (Fig. 2A, a–d) and ictal SPECT (Fig. 2A, e–h) for case 1. During ictus, a prominent increase in regional CBF was noted in the right anterior frontal lobe (arrow in Fig. 2A, c), which was surrounded by a relatively hypoperfused area (arrowhead). The contralateral cortex also was hyperperfused with a predominant increase in regional CBF in the left frontal area (Fig. 2A, e and f). In addition, an increase in regional CBF during ictus was observed in subcortical structures such as the bilateral lentiform nuclei, cerebellum, and brainstem (Fig. 2A, g and h).

In case 1, 19 spasms were recorded during mNIRS monitoring. Figure 2B shows representative topographic maps of the spatial changes in total-Hb concentrations (which reflect regional changes in CBV) in the bilateral frontal

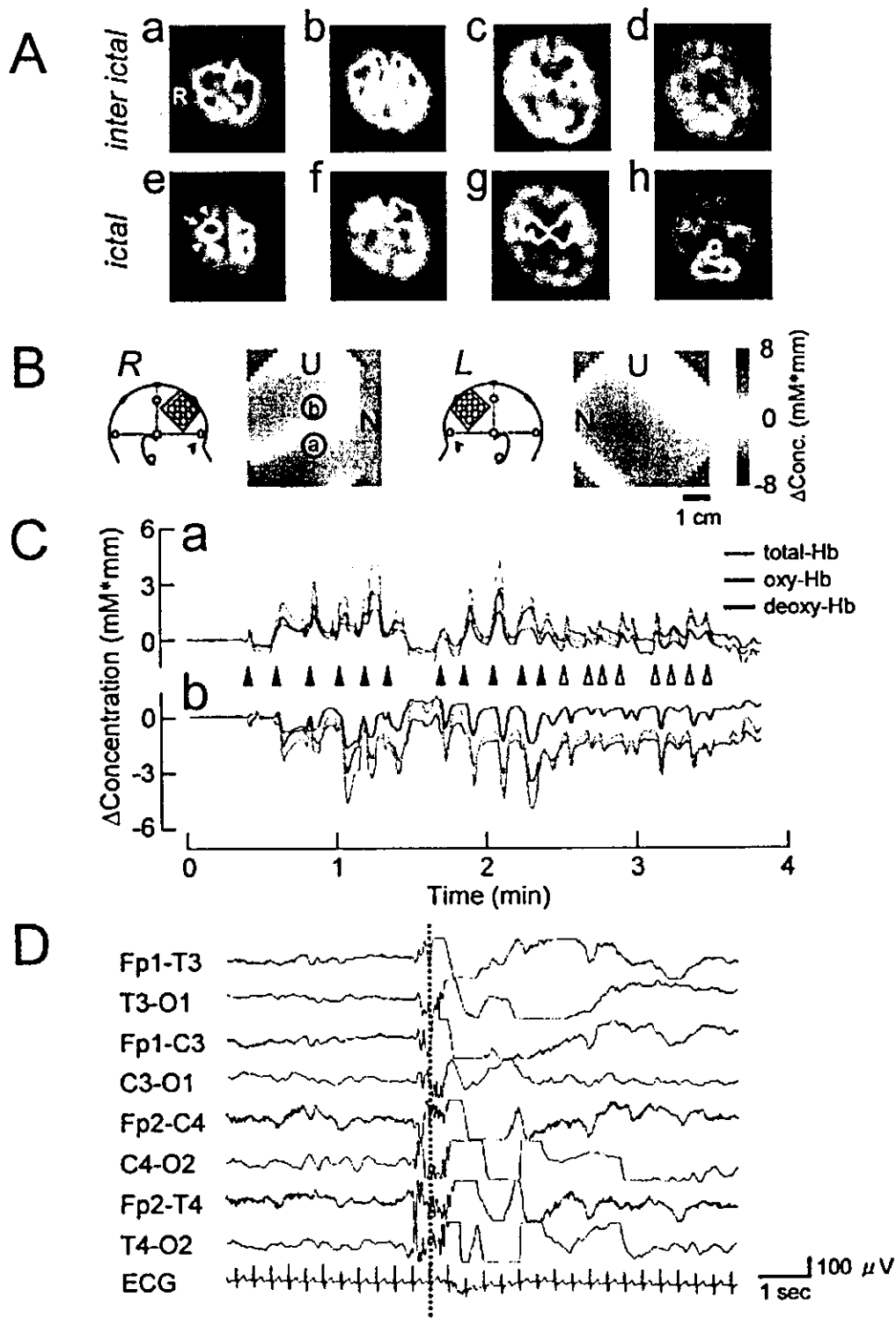
area during spasms. A focal increase in CBV occurred in the right hemisphere, whereas a simultaneous decrease in CBV occurred in the adjacent area. In the left hemisphere, CBV increased in a relatively diffuse manner. Figure 2C, a and b, illustrate the time course of changes in total-, oxy-, and deoxy-Hb concentrations during a cluster of spasms in the right hemisphere at the channels indicated by (a) and (b) in Figure 2B. In Figure 2C, a, the increase in regional CBV was transient, and the increase was synchronized with the spasm (arrowheads). In addition, a peripheral decrease in CBV (Fig. 2C, b) also was synchronized with the spasm. The first 11 spasms were intensely tonic and symmetrical (solid arrowheads in Fig. 2C); thereafter, the spasms became weak and asymmetrical (open arrowheads), and the spasms were associated with extension of the left arm. Intense spasms tended to be correlated with high total-Hb concentrations.

Figure 2D shows representative ictal EEG recordings during a spasm. A focal spike in the right hemisphere preceded each spasm. After this, fast waves occurred with right-hemisphere dominance; these waves were superimposed with high-voltage slow waves and were followed by desynchronization. The dotted line in Figure 2D indicates the onset of the spasm as determined by surface electromyography (EMG).

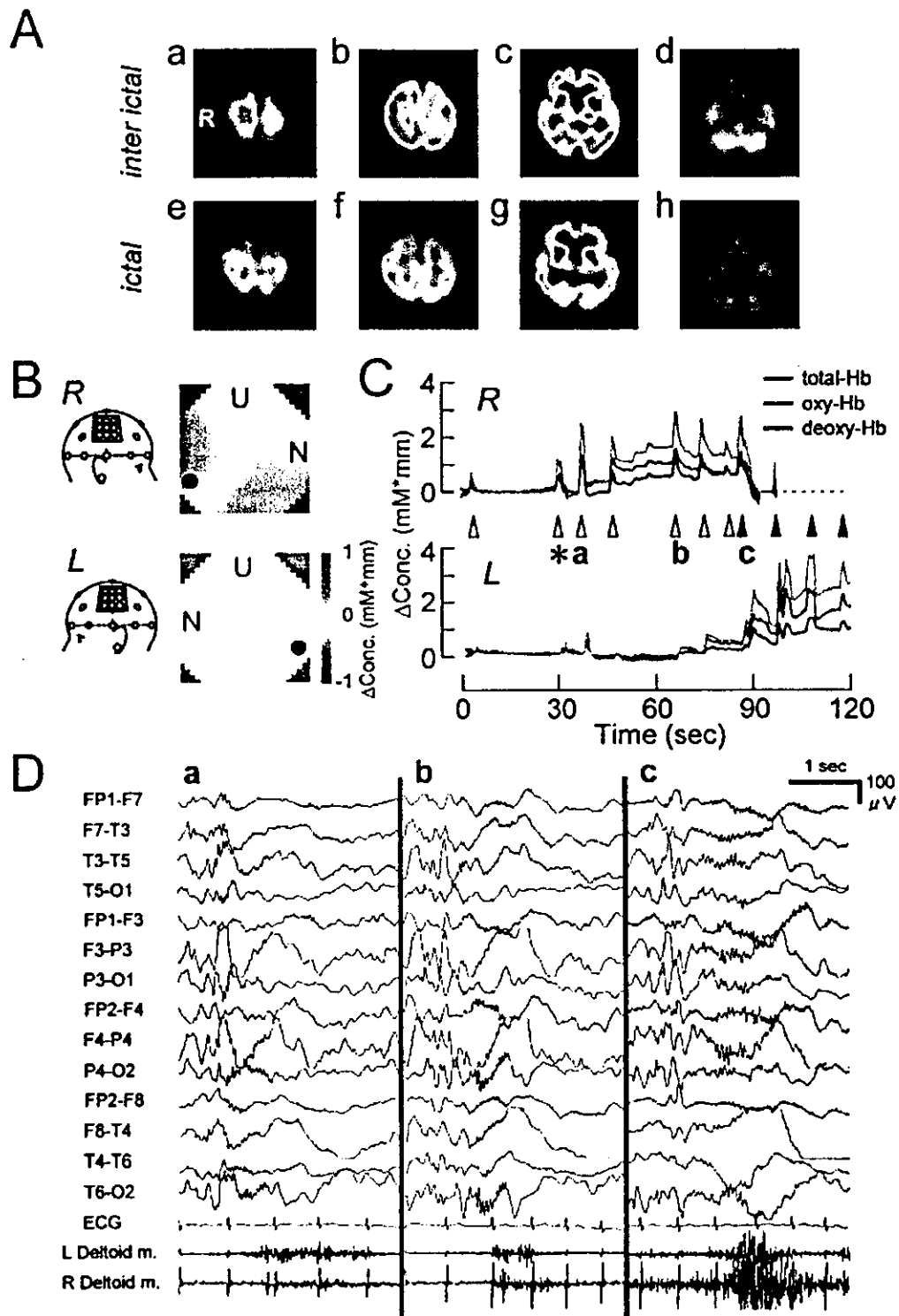
Figure 3A shows the results of interictal (Fig. 3A, a–d) and ictal (Fig. 3A, e–h) SPECT for case 2. During ictus, a bilateral increase in regional CBF was observed in the parietooccipital cortex, along with an increase in regional CBF in the bilateral lentiform nuclei. Consequently, for case 2, the optode arrays for mNIRS were placed symmetrically bilaterally, with the center of each array located over the central area (10–20 system), as illustrated in the insets in Figure 3B.

Figure 3B shows topographic maps of the regional CBV changes around the right and left central areas during a spasm for case 2 at the time point indicated by an asterisk in Figure 3C. A focal increase in CBV was seen in the posterior region of the right topographic map. A slight increase in CBV was observed also in the left homologous site. Figure 3C shows the time course of changes in total-, oxy-, and deoxy-Hb concentrations during a cluster of spasms in the right (R) and left (L) hemispheres at the same points in the corresponding hemispheres (solid circles in Fig. 3B). The spasms gradually became more intense during the progression of a cluster, and continuous recording in the right hemisphere became impossible after the eighth spasm, owing to the development of intense motion (broken line in Fig. 3C). Initially, the transient increase in CBV was synchronized with spasms in the right hemisphere; thereafter, a periodic increase in CBV in the left hemisphere gradually became obvious.

Figure 3D, a–c, shows an ictal EEG and surface EMG recordings that were made at the bilateral deltoid muscle;

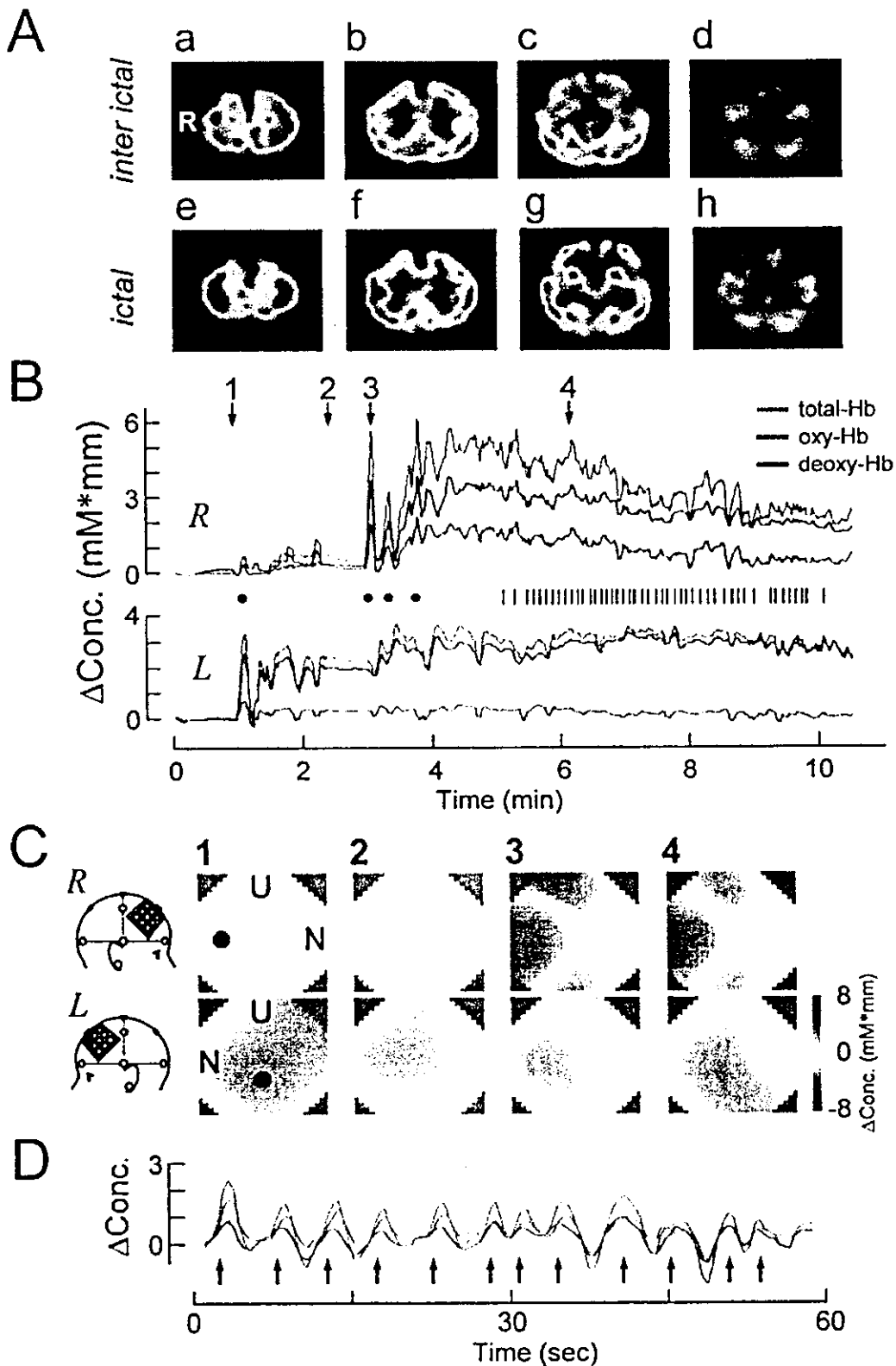


**FIG. 2.** Results for case 1. **A:** Results of [<sup>99m</sup>Tc]-ethyl cysteinyl dimer (ECD) single-photon emission computed tomography (SPECT) during interictal and ictal periods. Displays are transverse SPECT images parallel to the orbitomeatal plane that were obtained during interictal (a–d, in order from top to bottom of brain) and ictal (e–h) periods. The *arrow* and *arrowheads* in panel e indicate a hyper- and hypoperfused area of cortex, respectively. R, right. **B:** Representative topographic changes in regional cerebral blood volume (CBV) as inferred from changes in total hemoglobin (Hb) concentrations during spasms. U, upper; N, nasal. Insets illustrate the placement of the optode arrays and electroencephalography (EEG) electrodes. R, right, L, left. The time course of changes in ictal Hb concentrations at the recording channels that are indicated by (a) and (b) in B, are shown in panels Ca and b, respectively. **C:** The time course of changes in oxy-, deoxy-, and total-Hb concentrations at the points indicated by (a) and (b) in B are illustrated in panels Ca and b, respectively. *Arrowheads*, the occurrence of spasms. Initially, spasms were symmetrical (*solid arrowheads*), and were followed by asymmetrical, weak spasms in the left upper limbs (*open arrowheads*). **D:** Ictal EEG recorded simultaneously with multichannel near-infrared spectroscopy (mNIRS). The *broken line* indicates the onset of a spasm.



**FIG. 3.** Results for case 2. **A:** Results of SPECT during interictal (a–d) and ictal (e–h) periods. **B:** Topographic changes in cerebral blood volume (CBV; total-Hb concentrations) during a spasm. Insets illustrate the location of the optode arrays. The *solid circles* indicate the sites at which changes in Hb concentrations are illustrated in **C**. **C:** The time course of changes in Hb concentrations at the points is indicated by the *solid circles* in **B**. *Arrowheads*, The occurrence of spasms. Spasms were initially weak (*open arrowheads*), and subsequently transformed into massive tonic spasms (*solid arrowheads*) that prevented stable recording from the right hemisphere (*dashed line*). \*Time at which the topographic changes in CBV are depicted in **B**. **D:** Ictal EEG during spasms. Panels a–c correspond to the spasms indicated by a–c in **C**. Initially, short discharges of fast waves occurred predominantly in the right hemisphere. A surface EMG revealed that the spasm in the left hemisphere occurred earlier and was more intense than that in the right hemisphere (a). Thereafter, fast waves became evident in the left hemisphere during the progression of the ictus (b, c), and intensity of spasms increased in the right hemisphere. Note that the laterality of regional changes in CBV was closely correlated with the fast waves and the intensity of the spasms.





**FIG. 4.** Results for case 3. **A.** Results of SPECT during interictal (a–d) and ictal periods (e–h). **B.** The time course of changes in Hb concentrations at the points indicated by the *solid circles* in **C**. During the ictal period, atypical slight truncal movement was observed initially (*solid circles*), after which weak spasms occurred frequently (vertical bars). Topographic changes in cerebral blood volume (CBV) at the times corresponding to numbers 1–4 are illustrated in **C**. **C:** Topographic changes in CBV at the times indicated by numbers 1–4 in **B**. **D:** The time course of changes in Hb concentrations at the points indicated by the *solid circles* in **C** for a different ictal event are shown on an expanded time scale. Traces depicting oxy-, deoxy-, and total-Hb concentrations were realigned to time 0. *Arrows*, The occurrence of spasms. Concentrations of oxy-, deoxy-, and total-Hb fluctuated in concert with the occurrence of the spasms.

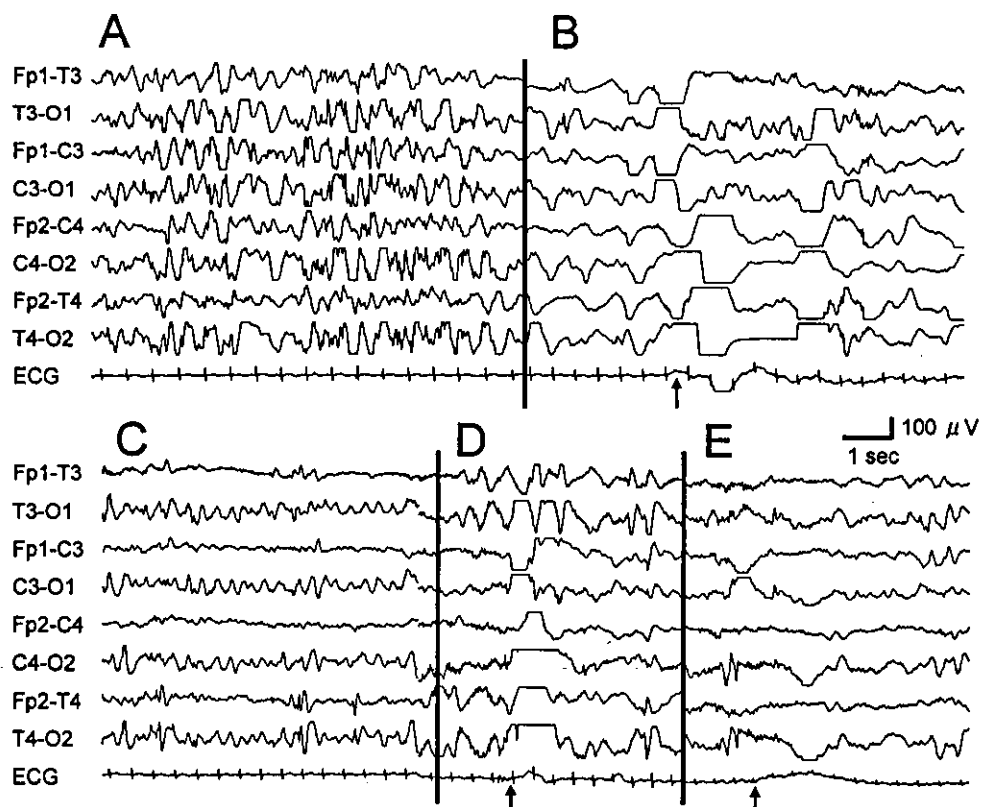
the corresponding times for the mNIRS data are indicated in Figure 3C, a–c. As noted in the surface EMG, initially spasms occurred slightly earlier in the left side of the body; thereafter, spasms occurred simultaneously in both sides.

Figure 4A shows the results of interictal (Fig. 4A, a–d) and ictal (Fig. 4A, e–h) SPECT for case 3. During ictus, an increase in regional CBF occurred in the right parietofrontal cortex, along with increases in regional CBF in subcortical structures. The interictal EEG during sleep for case 3 revealed symmetrical hypsarrhythmia (Fig. 5A). About 4 minutes before the initiation of clinically obvious spasms, case 3 awoke, and the hypsarrhythmia became irregular slow waves. Thereafter, a diffuse high-voltage slow wave that was led by the left hemisphere was noted, and this was followed by theta waves in the same hemisphere (Fig. 5B). At this time, slight truncal movement occurred (arrow in Fig. 5B). In the corresponding time period, a sudden increase in regional CBV occurred in the left hemisphere (number 1 in Fig. 4B and C), which was sustained. In the EEG (Fig. 5C), the theta activity became rhythmic and was observed bilaterally with an increased spike frequency in the right midtemporal area. During this period, a slight increase in regional CBV was noted in the right hemisphere (number 2 in Fig. 4B and C), and the patient did not exhibit any

movement. Thereafter, a focal increase in regional CBV occurred suddenly several times in the right hemisphere (number 3 in Fig. 4B and C), which was accompanied by atypical slight truncal movement. The truncal movement was considered to be an ictal phenomenon, because a high-voltage slow wave was noted in the EEG that was recorded at the same time (Fig. 5D). Thereafter, a gradual focal increase in regional CBV was seen in the right hemisphere, which reached a maximum value at which weak but clinically obvious spasms occurred (short vertical bars in Fig. 4B). The spatial distribution of the gradual increase in CBV is shown in Fig. 4C. The corresponding ictal EEG comprised diffuse small fast waves that were followed by a slow wave (Fig. 5E). Figure 4D shows the changes in regional CBV that were recorded from the same channel in the right hemisphere as that depicted in Figure 4C (solid circle) during a different cluster of spasms in the same patient at a magnified time scale. Fluctuations in total-, oxy-, and deoxy-Hb concentrations were synchronized with the spasms.

## DISCUSSION

In the present study, we used mNIRS to measure ictal changes in regional CBV during naturally occurring



**FIG. 5.** Interictal and ictal EEG for case 3. **A:** Interictal EEG showing hypsarrhythmia. **B:** Approximately 4 min after the attenuation of hypsarrhythmia, atypical truncal movement was noted, and focal rhythmic theta discharges emerged in the left occipital area. **C:** The theta discharge propagated to the right hemisphere, and an increase in the number of spikes was seen around recording channel T4. **D:** The theta activity changed to high-voltage slow waves, and atypical truncal movement occurred again. **E:** Ictal movement became a typical tonic spasm. *Arrows in B, D, and E indicate the occurrence of ictal events (atypical movements or spasms), as determined by video-recording the patient during the EEG monitoring.*

spasms in patients with WS. Considering the multiple etiologies (1) and heterogeneity of cortical involvement in WS (5,10), limited scope exists for the generalization of our observations. Nevertheless, our results have revealed some remarkable properties of the dynamic nature of cortical activity during epileptic spasms.

Intracranial propagation of near-infrared light is affected by multiple age-dependent factors, such as the optical properties of the scalp, skull, cerebrospinal fluid, and brain. In the adult head, the propagation of light through the brain is largely confined to the cortical gray matter, whereas in the neonatal head, light passes mainly through the cortex, although light may penetrate the subcortical white matter (17,18). Although subcortical structures, especially the lentiform nuclei, were activated during the ictal period in the present cases, the concomitant absorption change in such the deep brain areas was thought to be small with the short interoptode distance in the present study (18). However, further investigation is required to clarify how intracranial propagation of light changes with age.

Experiments using mNIRS have revealed that a tight coupling exists between hemodynamics and neuronal activity in the cortex. Habitual tasks or physiological stimuli evoke a focal increase in CBV (total-Hb concentrations) within a functionally corresponding area of the cortex (11,12). The increase in CBV is a result of the dilatation of regional microvessels, which is regulated locally by astrocytes that respond to neuronal activation (19). Because the activity-dependent CBV increase is much greater than the local oxygen demand, the change in CBV is usually accompanied by an increase in oxy-Hb concentrations, whereas deoxy-Hb concentrations decrease (20,21). Although ictal cortical hemodynamics are heterogeneous among the types of seizure, an increase in CBV together with an increase in both oxy- and deoxy-Hb concentrations has been noted during generalized convulsive seizures (22,23). The increase in deoxy-Hb concentrations is thought to reflect large oxygen consumption, implying the presence of intense neuronal activation. However, activity-related changes in deoxy-Hb concentrations may be modified by maturation processes in cerebral hemodynamics: normal adults tend to show a decrease in deoxy-Hb concentrations during physiological stimuli, whereas young infants tend to exhibit an increase in deoxy-Hb concentrations (24,25). In patients with WS, CBV increased with a marked increase in deoxy-Hb concentrations. Although the increase in deoxy-Hb concentrations suggests an expansion in oxygen consumption during intense epileptic cortical discharges, cerebral immaturity may affect the extent of the increase in deoxy-Hb concentrations in infants.

The use of mNIRS in the present study revealed that regional changes in CBV during the ictal period were highly dynamic and were distributed focally. We were able to

identify three different patterns of regional increases in CBV: (a) repetitive transient increases that were synchronized with spasms (these were observed in case 1); (b) a gradual fluctuating increase during a cluster that was synchronized with spasms (case 3); and (c) a periodic transient increase that also contained elements that resembled a gradual increase (case 2). The ictal short discharges of fast waves, which were prominent in cases 1 and 2, might be the events within the EEG recordings that were associated with a transient increase in regional CBV. The fast waves occurred immediately before the onset of each spasm and were the result of focal cortical discharges, which are thought to give rise to the spasms (26,27). In cases 1 and 2, a transient increase in CBV began immediately before a spasm, at the time at which fast waves emerged. The intensity and laterality of the increase in regional CBV was correlated with the amplitude of the fast waves. Therefore we believe that a focal transient increase in regional CBV reflects the ictal cortical discharge that produces fast waves.

The pathophysiologic basis for the gradual increase in CBV during a cluster of spasms remains unknown. One explanation is that gradual increases in CBV might be indicative of the presence of an epileptogenic area that is activated subclinically before the spasms, which subsequently dominates the entire ictal event. Previous clinical studies using single-channel NIRS reported the preictal hemodynamic change in pediatric cases with generalized seizures and with WS (23,28). The progressive increase in CBV may result from frequent periodic or sustained cortical discharge, which might in turn cause an accumulation of blood. Alternatively, it is possible that the gradual increase in CBV resulted from the combined activity of simultaneously progressing partial seizures (29), rather than from spasms, and that the increase in CBV masked an initial transient increase. To elucidate the involvement of the aforementioned pathophysiologic mechanisms, further investigations using more advanced mNIRS (e.g., a wider recording area and greater spatial resolution) are required.

In the area surrounding the region of largely increased CBV, a decrease in regional CBV was found that might have corresponded to the hypoperfused area that was noted in the ictal SPECT. The decrease in regional CBV occurred repeatedly with each spasm, suggesting that this was neither ictal exhaustion nor a postictal decrease in regional CBF, which is observed in other types of epilepsy (30). The decrease in regional CBV was caused predominantly by a change in the concentration of oxy-Hb, which suggests that the arterial blood supply was reduced; this might indicate the existence of a local steal phenomenon (31).

In the present study, mNIRS revealed that ictal cortical activation occurred in multiple cortical regions that were activated simultaneously or sequentially during the

progression of an ictal event. In cases 1 and 2, bilateral homologous sites were activated, whereas in case 3, unilateral cortical discharge that caused a partial seizure appeared to facilitate contralateral cortical activation that resulted in a single ictal event (24). Although single unilateral cortical discharges lead to bilateral spasms, presumably via subcortical structures (32), the pattern of activation of multiple cortical areas might affect the laterality and intensity of spasms. The mechanism by which multiple cortical areas interact during an ictal event is not known. Pinard et al. (33) reported that complete corpus callosotomy of a patient with WS resulted in asymmetrical spasms and unilateral hypersarrhythmia, and they suggested that the secondary generalization might have been caused by transcallosal propagation. Alternatively, it is possible that subcortical structures mediate such cortical interaction (2).

The analysis of changes in regional CBV in the present study suggested that spasms might have originated within the cortex in the present cases. However, it is unlikely that focal cortical activation generated the spasms autonomously, because the spasms were bilaterally tonic and repetitive, and ictal SPECT revealed symmetrical hyperperfusion of subcortical structures. It is likely that subcortical structures are involved in the propagation of spasms (9,10). Thus cortical activation may subsequently activate the subcortical effectors that ultimately produce spasms. Nevertheless, it should be noted that a possibility exists that subcortical primary lesions can cause epileptic spasms in some WS patients (23,34). If so, the properties of spasms in WS patients may be the result of a mutual interaction between cortical and subcortical structures via an unknown, age-dependent mechanism (2).

In conclusion, dynamic ictal cortical activity was recorded during clusters of spasms by using mNIRS. During ictal events, multiple cortical areas were activated simultaneously or sequentially. The pattern of cortical activation strongly influenced the phenotype of the infantile spasm, which suggested that the cortex was involved in the generation of spasms. Finally, the results of the present study exemplify how mNIRS can provide useful information in studies of seizure semiology.

## REFERENCES

1. Watanabe K. West syndrome: etiological and prognostic aspects. *Brain Dev* 1998;20:1-8.
2. Dulac O. What is West syndrome? *Brain Dev* 2001;23:447-52.
3. Fukuyama Y, Shionaga A, Iida Y. Polygraphic study during whole night sleep in infantile spasms. *Eur Neurol* 1979;18:302-11.
4. Chugani HT, Shewmon DA, Sankar R, et al. Infantile spasms, II: lenticular nuclei and brain stem activation on positron emission tomography. *Ann Neurol* 1992;31:212-9.
5. Chugani HT, Shields WD, Shewmon DA, et al. Infantile spasms, I: PET identifies focal cortical dysgenesis in cryptogenic cases for surgical treatment. *Ann Neurol* 1990;27:406-13.
6. Metsähonkala L, Gaily E, Rantala H, et al. Focal and global cortical hypometabolism in patients with newly diagnosed infantile spasms. *Neurology* 2002;58:1646-51.
7. Chiron C, Dulac O, Bulteau C, et al. Study of regional cerebral blood flow in West syndrome. *Epilepsia* 1993;34:707-15.
8. Asano E, Chugani DC, Juhasz C, et al. Surgical treatment of West syndrome. *Brain Dev* 2001;23:668-76.
9. Chugani HT, Rintahaka PJ, Shewmon DA. Ictal patterns of cerebral glucose utilization in children with epilepsy. *Epilepsia* 1994;35:813-22.
10. Haginoya K, Munakata M, Yokoyama H, et al. Mechanism of tonic spasms in West syndrome viewed from ictal SPECT findings. *Brain Dev* 2001;23:496-501.
11. Maki A, Yamashita Y, Ito Y. Spatial and temporal analysis of human motor activity using noninvasive NIR topography. *Med Phys* 1995;22:1997-2005.
12. Watanabe E, Maki A, Kawaguchi F, et al. Non-invasive assessment of language dominance with near-infrared spectroscopic mapping. *Neurosci Lett* 1998;256:49-52.
13. Watanabe E, Nagahori Y, Mayanagi Y. Focus diagnosis of epilepsy using near-infrared spectroscopy. *Epilepsia* 2002;43(suppl 9):50-5.
14. Holman BL, Hellman RS, Goldsmith SJ, et al. Biodistribution, dosimetry, and clinical evaluation of technetium-99m ethyl cysteinate dimer in normal subjects and in patients with chronic cerebral infarction. *J Nucl Med* 1989;30:1018-24.
15. Jöbsis FF. Noninvasive, infrared monitoring of cerebral and myocardial oxygen sufficiency and circulatory parameters. *Science* 1977;198:1264-7.
16. Wyatt JS, Cope M, Delpy DT, et al. Quantitation of cerebral blood volume in human infants by near-infrared spectroscopy. *J Appl Physiol* 1990;68:1086-91.
17. Faris F, Thorniley M, Wickramasinghe Y, et al. Non-invasive in vivo near-infrared optical measurement of the penetration depth in the neonatal head. *Clin Phys Physiol Meas* 1991;12:353-8.
18. Fukui Y, Ajichi Y, Okada E. Monte Carlo prediction of near-infrared light propagation in realistic adult and neonatal head models. *Appl Opt* 2003;42:2881-7.
19. Anderson CM, Nedergaard M. Astrocyte-mediated control of cerebral microcirculation. *Trends Neurosci* 2003;26:340-4.
20. Kato T, Kamei A, Takashima S, et al. Human visual cortical function during photic stimulation monitoring by means of near-infrared spectroscopy. *J Cereb Blood Flow Metab* 1993;13:516-20.
21. Obrig H, Wolf T, Doge C, et al. Cerebral oxygenation changes during motor and somatosensory stimulation in humans, as measured by near-infrared spectroscopy. *Adv Exp Med Biol* 1996;388:219-24.
22. Sokol DK, Markand ON, Daly EC, et al. Near infrared spectroscopy (NIRS) distinguishes seizure types. *Seizure* 2000;9:323-7.
23. Haginoya K, Munakata M, Kato R, et al. Ictal cerebral haemodynamics of childhood epilepsy measured with near-infrared spectrophotometry. *Brain* 2002;125:1960-71.
24. Meek JH, Firbank M, Elwell CE, et al. Regional hemodynamic responses to visual stimulation in conscious infants. *Pediatr Res* 1998;43:840-3.
25. Yamada H, Sadato N, Konishi Y, et al. A rapid brain metabolic change in infants detected by fMRI. *Neuroreport* 1997;8:3775-8.
26. Panzica F, Franceschetti S, Binelli S, et al. Spectral properties of EEG fast activity ictal discharges associated with infantile spasms. *Clin Neurophysiol* 1999;110:593-603.
27. Watanabe K, Negoro T, Okumura A. Symptomatology of infantile spasms. *Brain Dev* 2001;23:453-66.
28. Adelson PD, Nemoto E, Scheuer M, et al. Noninvasive continuous monitoring of cerebral oxygenation pericratically using near-infrared