

表2 心筋収縮蛋白のアイソフォームから見た CMG 細胞の表現型

	心房筋		心室筋			CMG 細胞
	胎仔型	成獣型	胎仔型	新生仔型	成獣型	
α -アクチン	skeletal	cardiac	skeletal > cardiac	skeletal	cardiac	skeletal > cardiac
ミオシン重鎖	α 型 > β 型	α 型	β 型 > α 型	α 型 > β 型	α 型	β 型 > α 型
ミオシン軽鎖	2a	2a	2v	2v	2v	2v

表3 CMG 細胞由来再生心筋細胞の受容体発現と受容体刺激による効果

受容体の種類	α 受容体			β 受容体		ムスカリン受容体	
	α 1A	α 1B	α 1D	β 1	β 2	M1	M2
受容体のサブクラス							
発現時期	最終分化誘導前より(漸増)	最終分化誘導前より(不変)	最終分化誘導前より(漸減)	最終分化誘導後1週より	最終分化誘導後1週より	最終分化誘導後1週より	最終分化誘導後1週より
シグナル伝達の確認	ERK 活性化	ERK 活性化	ERK 活性化	cAMP 上昇	cAMP 上昇	IP3 上昇	IP3 上昇
確認出来た作用	肥大作用			心拍数上昇, 心収縮力増強			

M2 受容体を発現し、神経とシナプスを形成する。CMG 細胞ではノルエピネフリンの α 1 受容体を最終分化前より発現し、ノルエピネフリンの β 1, β 2 受容体、アセチルコリン M1, M2 受容体を心筋細胞の形質獲得後には発現していた。また、これらの受容体は細胞内シグナル伝達機構も有していた⁹⁾(表3)。

3) サイトカインを用いた心筋細胞再生の促進
骨髄由来の幹細胞が、心筋細胞に分化することが判明してから、様々なサイトカインを用いて心筋再生を促進する試みがなされてきた。なかでも顆粒球コロニー増殖因子 (granulocyte-colony-stimulating factor: G-CSF) は、骨髄から末梢血中への幹細胞の動員を促進することによって、障害心筋領域での心筋再生が増加する作用があると

期待された。G-CSF が心筋再生に及ぼす影響を確認するために、我々は共同研究により致死量の放射線照射を行い、宿主の骨髄細胞を死滅させたマウスに EGFP (enhanced green fluorescence protein) を発現する全骨髄細胞を移植した後に心筋梗塞を作成し、G-CSF の投与の有無により骨髄細胞から再生される心筋細胞がどのように変化するのかを調査した。その結果、心筋梗塞作成後 10 日間 G-CSF を投与したマウスでは、梗塞巣周辺において EGFP を発現する心筋細胞、すなわち骨髄由来の再生心筋細胞が 166 倍に増加していた。また、骨髄中の幹細胞から心筋細胞が分化誘導されることが報告されて以来、造血幹細胞と骨髄間質細胞のどちらが再生心筋細胞の由来となっているかが、しばしば議論されてきた。我々は、再生心

《略語一覧》

G-CSF (granulocyte-colony-stimulating factor ; 顆粒球コロニー増殖因子)
EGFP (enhanced green fluorescence protein)

筋細胞へと分化した多能性幹細胞がいずれの由来であるかを調べるために放射線照射を行い、骨髄細胞を死滅させたマウスの骨髄中に、心筋細胞に分化した際にEGFPを発現するように遺伝子導入を行ったCMG細胞(骨髄間質細胞由来)を移植し、心筋梗塞を作成した後にG-CSFを投与したモデルでは、心筋梗塞巣の周囲に多くのEGFP陽性心筋細胞が認められた。これらの結果からG-CSFは心筋梗塞巣において、骨髄幹細胞からの心筋再生を促進し、心機能を改善する効果があること、これらの再生心筋細胞は造血幹細胞ではなく骨髄間質細胞より分化している可能性が高いことが示された¹⁰⁾。

おわりに

成人の組織内に存在する多能性幹細胞の分化能が研究されるに従い、これらは組織再生の有力な材料であり、これまで不可能と考えられていた心筋組織の再生が実現の可能性を帯びてきた。しかし、心筋の再生に関してはまだ動物モデルのみの報告も少なくなく、ヒトに臨床応用するにはまだ解決すべき課題も多く残されている。

循環器領域における再生医療の分野でも、心筋再生治療に関する研究は着実に進んでおり、実際に骨髄細胞、筋芽細胞などを用いた臨床試験が欧米では次々に行われている。これらの臨床試験においては心機能が改善されたなど、おおむね良好な結果が報告されているようである。しかし、これらの細胞移植研究において、心機能改善の機序に関してはリモデリングの防止や血管新生の促進など、さまざまなメカニズムが考えられており、心筋再生自体が心機能の改善に、どの程度貢献しているのかは未だ不明である。

原疾患を問わず、重篤な心不全に陥った心臓をよみがえらせるためには、心筋組織の再生が不可

欠である。今後、各種の多能性幹細胞から心筋が再生される機序がより詳細に解明され、臨床応用にたどり着く日が来ることが切望されている。

文献

- 1) Runicki MA, et al : MyoD or Myf-5 is required for the formation of skeletal muscle. *Cell* 75 : 1351-1359, 1993
- 2) Komuro I, Izumo S : Csx : a murine homeobox-containing gene specifically expressed in the developing heart. *Proc Natl Acad Sci USA* 90:8145-8149, 1993
- 3) Lints TJ, et al : Nkx-2.5 : a novel murine homeobox gene expressed in early heart progenitor cell and their myogenic descendants. *Development* 119 : 969, 1993
- 4) Kuo CT, et al : GATA4 transcription factor is required for ventral morphogenesis and tube formation. *Genes Dev* 11 : 1061-1072, 1997
- 5) Lin Q, Schwarz J, Bucana C, Olson EN : Control of mouse cardiac morphogenesis and myogenesis by transcription factor MEF2C. *Science* 276 : 1404-1407, 1997
- 6) Firulli AB, et al : Heart and extra-embryonic mesodermal defects in mouse embryos lacking the bHLH transcription factor Hand1. *Nat Genet* 18 : 266-270, 1998
- 7) Leferovich JM, et al : Heart regeneration in adult MRL mice. *Proc Natl Acad Sci USA* 98 : 9830-9835, 2001
- 8) Makino S, et al : Cardiomyocytes can be generated from marrow stromal cells *in vitro*. *J Clin Invest* 103 : 697-705, 1999
- 9) Hakuno D, et al : Bone Marrow-Derived Regenerated Cardiomyocytes (CMG Cells) Express Functional Adrenergic and Muscarinic Receptors. *Circulation* 105 : 380-386, 2002
- 10) Kawada H, et al : Nonhematopoietic mesenchymal stem cells can be mobilized and differentiate into cardiomyocytes after myocardial infarction. *Blood* 104 : 3581-3587, 2004

A Novel Application of Myocardial Contrast Echocardiography to Evaluate Angiogenesis by Autologous Bone Marrow Cell Transplantation in Chronic Ischemic Pig Model

Hiroko Fujii, MD, PhD,*† Shinji Tomita, MD, PhD,*‡ Takeshi Nakatani, MD, PhD,§
Shinya Fukuhara, MD,|| Akihisa Hanatani, MD, PhD,† Yoshinori Ohtsu, MD,* Michiko Ishida, MD,†
Chikao Yutani, MD, PhD,|| Kunio Miyatake, MD, PhD, FACC,† Soichiro Kitamura, MD, PhD, FACC‡
Osaka, Japan

OBJECTIVES	We investigated the feasibility of myocardial contrast echocardiography (MCE) to evaluate regional perfusion after bone marrow cell transplantation.
BACKGROUND	The myocardial microvessels improved by cell transplantation are too small to visualize with conventional angiography.
METHODS	Fourteen mini-pigs from the Nippon Institute for Biological Science were used. The proximal left anterior descending coronary artery was ligated. One month later, nine pigs survived. Six pigs received autologous cell transplantation into the left ventricular anterior wall: bone marrow mononuclear cells (BMMNCs) (n = 3) and bone marrow stromal cells (BMSCs) (n = 3). The other three pigs received saline (control group, n = 3). The pigs were sacrificed one month later. Myocardial contrast intensity (MCI) with a contrast agent was measured using the SONOS 5500 system (Philips). Capillary density (CD) and MCI were measured at four areas: anteroseptum (nontransplanted infarct area), anterior wall (transplanted infarct area), septum (border zone), and lateral wall (normal). We compared the anteroseptum with the anterior wall by MCI and CD.
RESULTS	In the BMMNC and BMSC subsets, the CD of the anterior wall was higher than that of the anteroseptum (p < 0.001). There was a linear relation between MCI and CD (acoustic unit [AU ²] = 0.234 CD + 0.010, r = 0.92, p < 0.001). At one month after cell transplantation, MCI of the anterior wall increased in the BMMNC and BMSC subsets (p < 0.05), although it did not change in the control group. The ratio of wall thickness (systole/diastole) in the transplanted infarct area was larger than that in the nontransplanted infarct area (p < 0.01).
CONCLUSIONS	Myocardial contrast echocardiography is useful to evaluate regional perfusion, which was enhanced by bone marrow cell transplantation. (J Am Coll Cardiol 2004;43:1299–305) © 2004 by the American College of Cardiology Foundation

Several researches reported that bone marrow cell transplantation into the heart induced angiogenesis (1–4). Assessment of myocardial perfusion after therapy is important. For a long time, vascular density on histologic study has been used to evaluate the therapeutic effectiveness of cell transplantation on myocardial infarction (MI) in experimental studies (5). However, it is invasive and difficult to perform a biopsy of the targeted area in clinical examinations.

Microvessels induced by bone marrow cell transplantation are too small (<50 μm) to visualize using conventional angiography (2,6). Although previous studies have found bone marrow cell transplantation to be effective, concrete and objective evidence for this therapy in daily clinical examinations has not been demonstrated.

Myocardial contrast echocardiography (MCE) is a non-invasive and inexpensive tool to evaluate myocardial perfusion in the microvasculature (7,8), and it can be performed even at the bedside. The purposes of this study were to verify the feasibility of MCE and to evaluate angiogenesis after bone marrow cell transplantation in the chronic ischemic heart of pigs.

METHODS

Animal model. All animals received humane care in compliance with the "Principles of Laboratory Animal Care," formulated by the National Society for Medical Research, and the "Guide for the Care and Use of Laboratory Animals," prepared by the Institute of Laboratory Animal Resources and published by the National Institutes of Health (NIH Publication No. 86-23, revised 1985). All procedures were approved by the Animal Care Committee of the National Cardiovascular Center, Osaka, Japan.

Fourteen mini-pigs (weight 25 to 30 kg) from the Nippon Institute for Biological Science (NIBS; Nosan Corp., Japan) were used. The pigs were premedicated with ketamine hydrochloride (600 mg intramuscularly), stressyl (2 ml), and atropine (1.5 mg) (9). Anesthesia was induced

From the *Department of Regenerative Medicine and Tissue Engineering, †Department of Cardiovascular Medicine, ‡Department of Cardiovascular Surgery, §Department of Organ Transplantation, and ||Department of Pathology, National Cardiovascular Center, Osaka, Japan. This research was supported in part by a Health Science Research Grant from the Ministry of Health, Labor, and Welfare (Research for Cardiovascular Diseases [13C-1] and Research on the Human Genome, Tissue Engineering Food Biotechnology [12-007]) and by Grants-in-Aid for Scientific Research (B) and for Exploratory Research from the Japan Society for the Promotion of Science.

Manuscript received July 11, 2003; revised manuscript received September 1, 2003, accepted September 16, 2003.

Abbreviations and Acronyms

AU	= acoustic unit
BMMNC	= bone marrow mononuclear cell
BMSC	= bone marrow stromal cell
CD	= capillary density
MCE	= myocardial contrast echocardiography
MCI	= myocardial contrast intensity
MI	= myocardial infarction

using a ventilation mask with 1% to 3% isoflurane, oxygen at 10 l/min, and ketamine hydrochloride (12 to 15 mg/kg intravenously). The animals were intubated using a cuffed endotracheal tube and were ventilated with 50% oxygen to maintain end-tidal CO₂ between 30 and 35 mm Hg. Anesthesia was maintained with 0.5% to 1.0% isoflurane in oxygen at a flow rate of 3 to 4 l/min and fraction of inspired oxygen (FIO₂) at 50%. Electrocardiography was used to monitor the heart rate, rhythm, and ST-segment changes during the surgical procedure.

Under general anesthesia, a left lateral thoracotomy was performed. The left anterior descending coronary artery was double-ligated with 2-0 silk (2). Ventricular fibrillation and tachycardia were treated with xylocaine and a defibrillator. After the lungs were adequately inflated, the pericardium was closed using 4-0 prolene sutures, and the chest was closed with #1 prolene. A 10-ml volume of sternal bone marrow was aspirated for culture. The pigs were weaned from anesthetics, extubated, and kept warm in a pen. The surgical team administered analgesic to the pigs, if needed.

By one month after MI, 5 of the 14 pigs had died. The nine pigs that survived were randomized as follows. Six of the nine pigs were assigned to a cell transplantation group whose subsets were bone marrow mononuclear cells (BMMNCs) (n = 3) and bone marrow stromal cells (BMSCs) (n = 3). The other three pigs received saline (control group, n = 3) (9).

Cell preparation. BONE MARROW MONONUCLEAR CELLS. In the BMMNC subset, at one month after MI, immediately before cell transplantation, 50 to 100 ml of fresh bone marrow was aspirated and loaded onto Lymphoprep (AXIS-SHIELD PoC AS, Oslo, Norway) (2). The solution was centrifuged at 800g at 4°C for 20 min. A white layer was aspirated and washed with phosphate-buffered saline twice, and 1 × 10⁸ cells/ml was created.

BONE MARROW STROMAL CELLS. A 10-ml volume of bone marrow was aspirated from the sternum on the same day as MI and then cultured in cell culture medium: Iscove's modified Dulbecco's medium with 10% fetal bovine serum, penicillin G (100 U/ml), streptomycin (100 µg/ml), and amphotericin B (0.2 µg/ml) (9). The cells were incubated with 95% air and 5% CO₂ at 37°C for one month.

The cultured BMSCs were dissociated from the culture dish with 0.05% trypsin in phosphate-buffered saline, collected, and centrifuged at 570g. The cells were then sus-

ended to obtain a concentration of 1 × 10⁸ cells in 1.0 ml. This suspension was injected in the same pig as registered in this BMSC subset.

Under general anesthesia, we performed bone marrow cell transplantation after a median sternotomy. We longitudinally opened the pericardium, exposing the heart to visualize the left anterior descending and diagonal arteries, so that we could recognize where the anterior wall was. Bone marrow cells were autologously injected using a 27-gauge needle with a 1-ml syringe. We made sure that the tip of the needle was not intracavitary with negative pressure when using the syringe and then injected each 0.1-ml cell solution of 10⁸ cells/ml at each of the 10 sites on the left ventricular anterior free wall at the mid-ventricle.

Myocardial contrast echocardiography. A specialist in MCE performed MCE at two stages: one month after infarction (before cell transplantation) and one month after cell transplantation. A SONOS 5500 system (Philips, Andover, Massachusetts) was used (2,10). All imaging was performed at the mid-papillary muscle level of the left ventricle, under a closed-chest condition. The MCE imaging was performed in the second harmonic mode, in which ultrasound was transmitted at 1.8 MHz and received at 3.6 MHz. The mechanical index was set at 1.4 to 1.6. The maximal dynamic range was 60 dB. As a venous contrast agent, we used the second-generation microbubbles called YM-454 (Definity, Bristol-Myers Squibb Medical Imaging Inc., North Billerica, Massachusetts) (8). They are composed of a bilayer phospholipid shell and perfluoropropane. The mean size of gas-filled liposomes is about 2.5 µm. This agent was injected intravenously at a rate of 100 µl/min. We used the intermittent mode and the multiframe trigger method in MCE, and we set the trigger point at the end-systolic phase every 4 beats in this study.

Data were recorded on 1.25-cm videotape with an S-VHS recorder and on a 5-inch magnetic optical disk (11,12) and analyzed off-line using QuantiCon (Echotech 3D Imaging Systems, GmbH, Hallbergmoos, Germany). We put the region of interest on targeted areas and calculated their myocardial intensities. We subtracted the intensity of phase B from that of phase A at a target. Phase A occurred when the microbubbles sufficiently filled the myocardium, and phase B occurred when about 80% of microbubbles were destroyed by a series of three frames of the ultrasound beam within the end-systolic phase. We regarded this subtracted intensity as myocardial contrast intensity (MCI) for analysis. The acoustic unit (AU) was determined using the Acoustic densitometry software package (Philips), which displays intensities in dB (13). Acoustic densitometry provides an integrated on-line capability to measure, display, and analyze the average acoustic image intensity. Off-line densitometric systems that offer a "digital" solution for data storage using magnetic/optical disk media are also plagued with the problem of nonlinearity in the image data (13). We calculated AU² from dB using the equation: (y[AU] = 255 × 10^{-(60-x[dB])/20}), and we

Table 1. Capillary Density One Month After Cell Transplantation

Subset No.	Normal Area*	Nontransplanted Infarct Area†	Transplanted Infarct Area‡
BMMNC-1	1.98	0.768	1.60
BMMNC-2	2.14	0.576	2.44
BMMNC-3	0.92	0.704	1.28
BMSC-1	2.53	0.461	0.55
BMSC-2	2.10	0.384	1.47
BMSC-3	1.69	0.359	1.86
Control-1	2.91	0.218	0.26
Control-2	2.18	0.282	0.21
Control-3	2.62	0.346	0.36

Anatomic portion: *lateral wall, †anteroseptum, and ‡anterior wall.
 BMMNC = bone marrow mononuclear cell subset; BMSC = bone marrow stromal cell subset; control = control group.

assessed myocardial intensity using AU². We put the region of interest on four different target areas for measurement of intensity: anteroseptum (nontransplanted infarct area), anterior wall (transplanted infarct area), septum (border area), and lateral wall (normal area). At these four target areas, MCI and capillary density (CD) were measured and compared.

Wall thickness. To evaluate wall motion, we measured the wall thickness of the systolic and diastolic phases at the anteroseptum (nontransplanted infarct area), anterior wall (transplanted infarct area), and lateral wall (normal area). We calculated the wall thickness (systole/diastole) ratio and assessed the regional wall motion.

Histologic studies (CD). At one month after cell transplantation, we performed MCE to assess MCI, after which the heart was arrested with potassium chloride and excised for histologic study. The coronary arteries were then perfused with 10% formaldehyde (100 ml), and the heart was immersed in the formaldehyde for 20 days.

After fixation, a cube (5 × 10 × 10 mm) of tissue from each site, where MCE was evaluated, was embedded in paraffin and cut into 6-μm sections for staining with hematoxylin-eosin, as described in the manufacturer's specifications (Sigma Chemical Co., St. Louis, Missouri), and von Willebrand factor-related antigen (14). A pathologist and an orthopedist investigated bone formation and tumor-

Table 2. Myocardial Contrast Intensity (AU²) One Month After Cell Transplantation

Subset No.	Normal Area*	Nontransplanted Infarct Area†	Transplanted Infarct Area‡
BMMNC-1	0.496	0.146 (0.130)	0.460 (0.110)
BMMNC-2	0.553	0.167 (0.192)	0.635 (0.210)
BMMNC-3	0.201	0.149 (0.121)	0.127 (0.133)
BMSC-1	0.697	0.110 (0.179)	0.146 (0.217)
BMSC-2	0.401	0.124 (0.183)	0.450 (0.118)
BMSC-3	0.383	0.142 (0.192)	0.440 (0.101)
Control-1	0.710	0.092 (0.152)	0.127 (0.167)
Control-2	0.644	0.146 (0.171)	0.099 (0.142)
Control-3	0.764	0.130 (0.130)	0.121 (0.127)

Anatomic portion: *lateral wall, †anteroseptum, and ‡anterior wall. The numbers in parentheses indicate myocardial contrast intensity before cell transplantation.
 Abbreviations as in Table 1.

Table 3. Ratio of Wall Thickness (Systole/Diastole)

Subset No.	Normal Area*	Nontransplanted Infarct Area†	Transplanted Infarct Area‡
BMMNC-1	1.4	1.0	1.5
BMMNC-2	1.4	1.2	1.4
BMMNC-3	1.6	1.1	1.6
BMSC-1	1.4	1.0	1.3
BMSC-2	1.7	1.0	1.7
BMSC-3	1.7	1.2	1.4
Control-1	1.4	1.0	1.0
Control-2	1.4	1.0	1.0
Control-3	1.3	1.1	1.0

Anatomic portion: *lateral wall, †anteroseptum, and ‡anterior wall.
 Abbreviations as in Table 1.

igenic formation. An observer blinded to the treatment groups and subsets determined the CD of the anteroseptum (nontransplanted infarct area), anterior wall (transplanted infarct area), septum (border area), and lateral wall (normal area). Five fields of each section were randomly selected, and the CD was averaged and expressed as the number of blood vessels per mm² (15).

Statistical methods. Data are expressed as the mean value ± SD. Interstage comparisons in each group and intrastage differences between two groups were confirmed using the Mann-Whitney *U* test. Analysis System software (Statcel, OMS Publishing Company, Tokorozawa, Saitama, Japan) was used for these two analyses. Correlations were performed using logarithmic or linear regression analysis. Differences were considered significant at *p* < 0.05.

RESULTS

There was no critical arrhythmia before, during, or after cell transplantation. Heart rate and blood pressure were stable during transplantation. The nine pigs that survived for one month after MI completed the whole procedure.

Capillary density and MCI of normal, nontransplanted, infarct, and transplanted infarct areas. The CD of the normal area was 2.12 ± 0.58 (×10³/mm²) and that of the nontransplanted infarct area was 0.46 ± 0.19 (×10³/mm²) (Table 1). The MCI of the normal area was 0.54 ± 0.19 and that of the nontransplanted infarct area was 0.13 ± 0.02 (Table 2). Both the CD and MCI of the normal area were significantly higher than those of the nontransplanted infarct area (*p* = 0.00035 and *p* = 0.00035, respectively).

On the transplanted infarct area, the CD of the transplant group (including the BMMNC and BMSC subsets) was 1.53 ± 0.63 (×10³/mm²) and that of the control group was 0.27 ± 0.07 (×10³/mm²) (Table 1). On the same area, the MCI of the transplant group was 0.38 ± 0.20 and that of the control group was 0.12 ± 0.02 (Table 2).

The CD and MCI of the transplanted infarct area in the transplant group were significantly higher than those of the same area in the control group (*p* = 0.020 and *p* = 0.028, respectively).




Figure 1. Capillary formation at the anteroseptum and anterior wall. Number 1 represents the bone marrow mononuclear cell (BMMNC) subset; number 2 represents the bone marrow stromal cell (BMSC) subset; and number 3 represents the control group (magnification $\times 200$). The top row (1a, 2a, 3a) shows the findings of the anteroseptum (nontransplanted infarct area), and bottom row (1b, 2b, 3b) shows the findings of the anterior wall (transplanted infarct area). In the BMMNC and BMSC subsets, the anterior wall (1b, 2b) contained more capillaries than the anteroseptum (1a, 2a). In contrast, in the control group, both the anteroseptum (3a) and anterior wall (3b) contained very few capillaries.

Wall thickness ratio (systole/diastole) of normal, non-transplanted infarct, and transplanted infarct areas. The wall thickness systolic/diastolic ratio at the normal area was significantly larger than that at the nontransplanted infarct area (1.50 ± 0.18 and 1.07 ± 0.09 , respectively; $p = 0.0003$) (Table 3). In the cell transplant group, the wall thickness systolic/diastolic ratio at the transplanted infarct area was significantly larger than that at the nontransplanted infarct area (1.48 ± 0.15 and 1.08 ± 0.1 , respectively; $p = 0.004$), although there was no difference in the control group. Further, when we compared the systolic/diastolic ratio between the cell transplant group and control group at the transplanted infarct area, the ratio in the transplant group was significantly larger than that in control group (1.48 ± 0.15 and 1 ± 0 , respectively; $p = 0.02$) (Table 3).

Comparison of CD in nontransplanted and transplanted infarct areas. The histologic findings of the section stained for von Willebrand factor are shown in Figure 1. In both the BMMNC and BMSC subsets, the anteroseptum (nontransplanted infarct area) contained very few capillaries (Fig. 1 [1a and 2a]). In contrast, the anterior wall (transplanted infarct area) contained more capillaries than the anteroseptum (Figs. 1 [1b and 2b]). The size of the capillaries at the transplanted infarct area ranged from 5 to 20 μm , which varied more than that of the normal area (10 to 20 μm). Bone formation or tumorigenic formation was not observed at the transplanted area in any pig.

In the cell transplant group, the CD of the anterior wall was significantly larger than that of the anteroseptum ($p = 0.0081$) (Fig. 2A) (BMMNC subset, $p =$

0.025 ; BMSC subset, $p = 0.025$) (Fig. 2B). In the control group, the CD of both the anterior wall and anteroseptum was low, and there was no significant

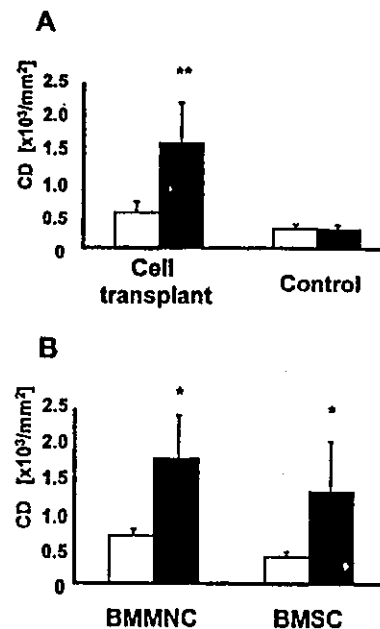


Figure 2. The capillary density (CD) of the anteroseptum (open bars) and anterior wall (solid bars). The CD of the anterior wall was higher than that of the anteroseptum in the cell transplant group (** $p = 0.0081$; A) ($*p = 0.025$ and $*p = 0.025$ for bone marrow mononuclear cell (BMMNC) and bone marrow stromal cell (BMSC) subsets, respectively; B), although there was no difference between the two areas in the control group (A).

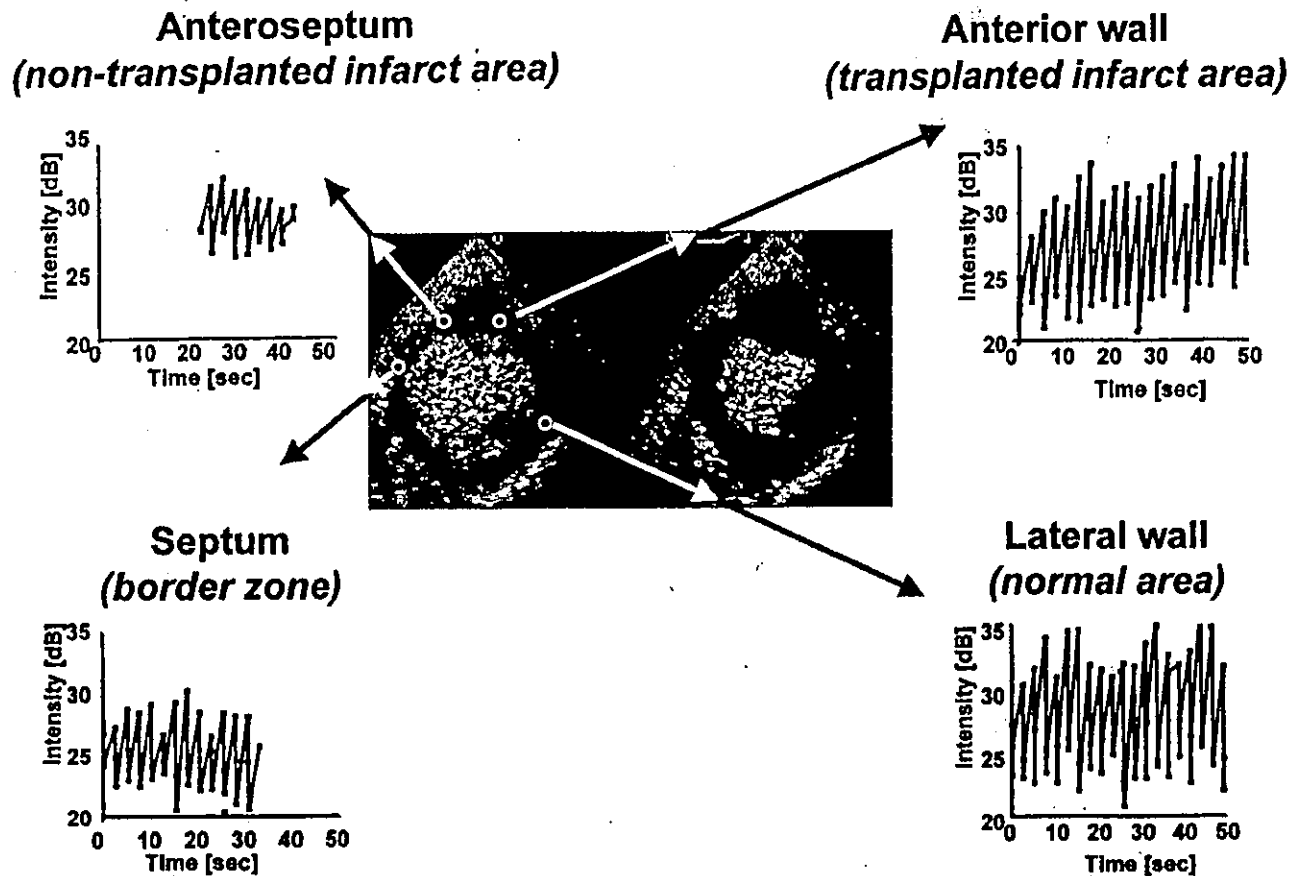


Figure 3. The myocardial contrast intensity (MCI) of the bone marrow mononuclear cell subset at one month after cell transplantation. The four graphs enable us to quantify MCI and to recognize the differences in the anteroseptum, anterior wall, septum, and lateral wall. The MCI in the anterior wall was higher than that in the anteroseptum.

difference between the two areas ($p = \text{NS}$) (Fig. 2A). The CD of the anteroseptum in the BMMNC subset was larger than that of the other subset or group ($p = 0.027$). **Relationship between MCI and CD.** Figure 3 shows typical graphs of the four target areas at one month after BMMNC transplantation. The MCI of the anterior wall (transplanted infarct area) was higher than that of the anteroseptum (nontransplanted infarct area). The MCI and CD of four target areas at the same stage were plotted (Fig. 4).

The MCI and histologic CD correlated well based on data derived from four areas of all pigs. When MCI was analyzed by decibel, MCI and CD were correlated logarithmically ($\text{dB} = 7.32\text{Log}[\text{CD}] + 5.89$; $r = 0.90$, $p < 0.001$) (Fig. 4A). There was a significant linear relation between MCI analyzed by AU^2 and CD ($\text{MCI} [\text{AU}^2] = 0.23 \text{CD} + 0.01$; $r = 0.92$, $p < 0.001$) (Fig. 4B).

Time course of MCI. In the control and cell transplant groups, there was the same time trend of MCI at the anteroseptum (nontransplanted infarct area), which slightly decreased ($p = \text{NS}$) (Fig. 5A). In contrast, the MCI of the anterior wall (transplanted infarct area) significantly in-

creased in the cell transplant group ($p = 0.018$), although it did not change in the control group ($p = \text{NS}$) (Fig. 5B).

DISCUSSION

The importance of this study is to establish a method to follow the effect of bone marrow cell transplantation not only in experimental studies but also in clinical examinations. Therefore, we performed MCE using Definity as the contrast agent and a commercially available ultrasound machine, based on the hypothesis that MCE would be a useful tool to assess the microcirculation after cell transplantation.

This study demonstrated that: 1) MCI measured by MCE was closely correlated with CD; 2) bone marrow cell transplantation increased blood perfusion at the infarct area; and 3) bone marrow cell transplantation into the heart was performed safely.

Relationship between MCI and CD for assessment of myocardial perfusion. The relationship between MCI and CD showed a strong correlation. This result indicates that MCE is as useful as CD for evaluating angiogenesis. In previous experimental studies, CD or microsphere analysis

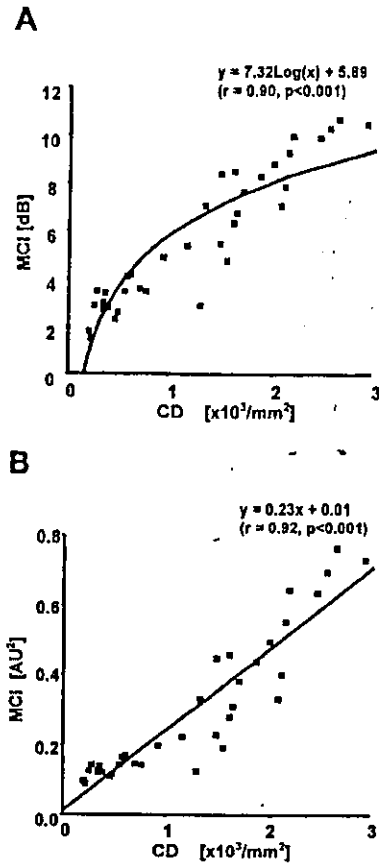


Figure 4. Relationship between myocardial contrast intensity (MCI) and capillary density (CD). (A) When MCI was evaluated by dB, a logarithmic relation was seen between MCI and CD. (B) When MCI was evaluated by AU², a linear relation was seen between them.

was generally used to assess angiogenesis (8,16). However, in clinical examinations, we cannot use these two methods. In contrast, MCE is a noninvasive and repeatable method to evaluate angiogenesis induced by bone marrow cell transplantation to the heart for clinical application.

The microsphere method reflects functional myocardial perfusion. There are several reports stating that MCI using MCE reflects myocardial perfusion using the microsphere method (11,17). Therefore, MCI reflects functional myocardial perfusion.

Recently, it was reported that MCI evaluated by AU² is proportional to the concentration of microbubbles (13). In this study, we proved that MCI evaluated by AU² is proportional to CD. This result indicates that the new microvessels created by bone marrow cell transplantation were functional.

Importance of angiogenesis by bone marrow cell transplantation. Bone marrow cell transplantation (BMMNCs and BMSCs) induced angiogenesis in the transplanted area, as proved by CD and MCI. The angiogenesis induced by bone marrow cell transplantation may make the residual cardiac muscle and transplant cells survive, which may contribute to improvement of contraction (1).

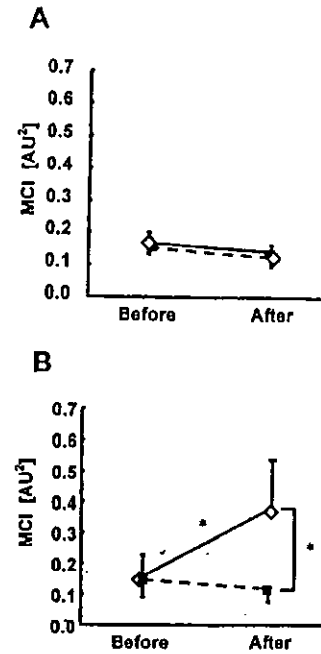


Figure 5. Time course of myocardial contrast intensity (MCI) in the anteroseptum and anterior wall before and after transplantation. The straight line indicates the cell transplant group (bone marrow mononuclear cell and bone marrow stromal cell subsets), and the dashed line indicates the control group. (A) At the anteroseptum (nontransplanted infarct area), there was no significant change between the groups or stages. (B) At the anterior wall (transplanted infarct area), the MCI of the cell transplant group significantly increased after transplantation (**p* = 0.018), although that of the control group did not change.

The BMMNC subset. The BMMNCs contain various kinds of cells, such as hematopoietic cells, fibroblasts, myogenic cells, and endothelial cells, and they can work beneficially in the ischemic myocardium (12). This study was consistent with our previous result (1). We observed angiogenesis, as described earlier, and did not see any bone formation. The BMMNCs have several advantages. Special facilities are not required because we can process them fresh by a clinically established protocol. This procedure is simple and can be performed safely.

The BMSC subset. The BMSCs were cultured by Caplan's method, as previously reported (9,18). The BMSCs can be isolated from the other cells in marrow by their tendency to adhere to the culture dish. Stromal cells were a heterogeneous population (1). Our study suggested that the BMSCs could include stem cells differentiating into endothelial cells due to an increase in CD and improvement of myocardial perfusion.

The potential mechanisms inducing angiogenesis after endothelial cell transplantation are formation of blood vessels by transplanted endothelial cells and stimulation of angiogenesis by growth factors such as vascular endothelial growth factor, beta-fibroblast growth factor, and insulin-like growth factor-1 (2), expressed or stimulated by transplanted endothelial cells (15).

The BMSCs can be cultured from only 10 ml of bone

marrow; however, it takes time to expand and requires culture facilities satisfying good manufacturing practice for clinical applications.

Effects of BMMNC and BMSC transplantation. The increases in CD and MCI after cell transplantation were recognized in both the BMMNCs and BMSCs. The BMSCs stimulated angiogenesis as fresh bone marrow cells (BMMNCs), as in our previous rat study (1). The significant increases in CD and MCI at the transplanted infarct area indicated that bone marrow cell transplantation improved regional perfusion where cells were injected in both BMMNC and BMSC subsets.

Wall motion after cell transplantation. In the cell transplant group, the regional wall motion of the transplanted infarct area was significantly improved after cell transplantation. This result indicates that improvement of perfusion after bone marrow cell transplantation is reflected in regional wall motion where bone marrow cells are transplanted.

Follow-up MCE after cell transplantation. The MCI using MCE enabled us to assess the effects of this therapy not only by comparing the transplanted infarct area with the nontransplanted infarct area, but also by comparing the transplanted infarct area before and after cell transplantation; therefore, it is useful for follow-up after this therapy.

Bone marrow cell transplantation for clinical application. Bone marrow cell transplantation was performed safely in our study. During the acute phase (perioperative period), there were no detrimental effects such as hypotension, arrhythmia, or hypoxemia. During the subchronic phase, there was no critical arrhythmia. There was no ectopic differentiation (bone formation) or tumorigenic formation at the transplant sites. From the point of view of clinical application, we regarded both the BMMNC and BMSC transplantations as feasible.

Study limitations. The sample size of this study is low at the subset level. The bone marrow cell transplantation group was composed of BMMNC and BMSC subsets, and not only was their wall motion statistically improved after cell transplantation, but also their CD and MCI were statistically higher than those in the nontransplanted area. This project is adequately powered by statistical analysis.

We measured CD and MCI only at one month after cell transplantation. It will be necessary to evaluate myocardial perfusion and especially cardiac function in the long term.

Conclusions. We proved that bone marrow cell transplantation improved the regional perfusion in the chronic ischemic heart. Because angiogenesis after cell transplantation is the most important factor that improves myocardial condition, MCI using noninvasive MCE could be a promising tool to evaluate functional perfusion after bone marrow cell transplantation in the clinical setting.

Acknowledgments

We thank Mr. K. Masuda, Ms. E. Takeda, and Dr. H. Ishibashi-Ueda for their technical assistance in the histologic study, as well as Ms. K. Hattori for her help in performing surgical procedures. We also thank Dr. H.

Ohgushi (Tissue Engineering Research Center, National Institute of Advanced Industrial Science of Technology, Japan) for the investigation of bone formation and tumorigenic formation.

Reprint requests: Dr. Soichiro Kitamura, President of National Cardiovascular Center, Chairman of Department of Cardiovascular Surgery, 5-7-1 Fujishirodai, Suita, Osaka, 565-8565 Japan. E-mail: skitamura@hsp.nccvc.go.jp.

Correspondence: Dr. Shinji Tomita, Cardiothoracic Surgical Unit, Auckland City Hospital, Private Bag 92024, Auckland, New Zealand. E-mail: shinjitomita@hotmail.com.

REFERENCES

1. Tomita S, Li RK, Weisel RD, et al. Autologous transplantation of bone marrow cells improves damaged heart function. *Circulation* 1999;100 Suppl II:II247-56.
2. Kamihata H, Matsubara H, Nishiue T, et al. Implantation of bone marrow mononuclear cells into ischemic myocardium enhances collateral perfusion and regional function via side supply of angioblasts, angiogenic ligands, and cytokines. *Circulation* 2001;104:1046-52.
3. Hulspas R, Quesenberry PJ. Characterization of neurosphere cell phenotypes by flow cytometry. *Cytometry* 2000;40:245-50.
4. Hamano K, Li TS, Kobayashi T, et al. Therapeutic angiogenesis induced by local autologous bone marrow cell implantation. *Ann Thorac Surg* 2002;73:1210-5.
5. Edelberg JM, Lee SH, Kaur M, et al. Platelet-derived growth factor-AB limits the extent of myocardial infarction in a rat model: feasibility of restoring impaired angiogenic capacity in the aging heart. *Circulation* 2002;105:608-13.
6. Feinstein SB, Shah PM, Bing RJ, et al. Microbubble dynamics visualized in the intact capillary circulation. *J Am Coll Cardiol* 1984;4:595-600.
7. Skyba DM, Jayaweera AR, Goodman NC, et al. Quantification of myocardial perfusion with myocardial contrast echocardiography during left atrial injection of contrast: implications for venous injection. *Circulation* 1994;90:1513-21.
8. Wei K, Jayaweera AR, Firoozan S, et al. Quantification of myocardial blood flow with ultrasound-induced destruction of microbubbles administered as a constant venous infusion. *Circulation* 1998;97:473-83.
9. Tomita S, Mickle DA, Weisel RD, et al. Improved heart function with myogenesis and angiogenesis after autologous porcine bone marrow stromal cell transplantation. *J Thorac Cardiovasc Surg* 2002;123:1132-40.
10. Linka AZ, Sklenar J, Wei K, et al. Assessment of transmural distribution of myocardial perfusion with contrast echocardiography. *Circulation* 1998;98:1912-20.
11. Mills JD, Fischer D, Villanueva FS. Coronary collateral development during chronic ischemia: serial assessment using harmonic myocardial contrast echocardiography. *J Am Coll Cardiol* 2000;36:618-24.
12. Galuto L, DeMaria AN, del Balzo U, et al. Ischemia-reperfusion injury at the microvascular level: treatment by endothelin A-selective antagonist and evaluation by myocardial contrast echocardiography. *Circulation* 2000;102:3111-6.
13. Alwyn D'Sa. *Acoustic Densitometry*. Andover, MA: Agilent Technologies, 2000.
14. Li RK, Weisel RD, Mickle DA, et al. Autologous porcine heart cell transplantation improved heart function after a myocardial infarction. *J Thorac Cardiovasc Surg* 2000;119:62-8.
15. Kim EJ, Li RK, Weisel RD, et al. Angiogenesis by endothelial cell transplantation. *J Thorac Cardiovasc Surg* 2001;122:963-71.
16. Asahara T, Masuda H, Takahashi T, et al. Bone marrow origin of endothelial progenitor cells responsible for postnatal vasculogenesis in physiological and pathological neovascularization. *Circ Res* 1999;85:221-8.
17. Firschke C, Linder JR, Wei K, et al. Myocardial perfusion imaging in setting of coronary artery stenosis and acute myocardial infarction using venous injection of a second-generation echocardiographic contrast agent. *Circulation* 1997;96:959-67.
18. Procop DJ. Marrow stromal cells nonhematopoietic tissues. *Science* 1997;276:71-4.

Bone Marrow Mononuclear Cell Transplantation Had Beneficial Effects on Doxorubicin-induced Cardiomyopathy

Michiko Ishida, MD,^{a,b} Shinji Tomita, MD, PhD, FAHA,^{a,b} Takeshi Nakatani, MD, PhD,^c Shinya Fukuhara, MD,^d Masaki Hamamoto, MD,^{a,b} Noritoshi Nagaya, MD,^e Yoshinori Ohtsu, MD,^a Michiharu Suga, MD, PhD,^a Chikao Yutani, MD, PhD,^d Toshikatsu Yagihara, MD, PhD,^b Kazuhiko Yamada, MD, PhD,^a and Soichiro Kitamura, MD, PhD^b

Background: Cell transplantation is a promising therapy for treating end-stage heart failure. Bone marrow mononuclear cells (BMMNC) have been used to enhance angiogenesis in ischemic heart disease. However, the effect of BMMNC transplantation in non-ischemic dilated cardiomyopathy is unknown. In this study, we evaluated the efficacy of BMMNC transplantation in doxorubicin-induced cardiomyopathy in a rat model.

Methods: Doxorubicin (15 mg/kg, IP) was introduced into 52 Lewis rats. They were divided into 3 groups at 4 weeks after injection: transplant group (TX, BMMNC [1×10^6] implantation, $n = 18$), control group (CN, saline injection, $n = 18$), and sham group (SH, thoracotomy, $n = 16$). At 4 weeks after surgery, we used echocardiography to measure systolic left ventricular diameter (LVDs), diastolic left ventricular diameter (LVDd), fractional shortening (FS), and left ventricular wall thickness/LVDs. We used a Langendorff apparatus to measure systolic, diastolic, and developed pressures. We used radioimmunoassay to measure circulating atrial natriuretic peptide concentration, and we performed histologic study, including electron-microscopic study.

Results: Left ventricular wall thickness/LVDs in the TX group was the largest of all groups ($p < 0.05$). Systolic and developed pressures in the TX group were the greatest ($p < 0.005$). Systolic left ventricular diameter, FS, and end-diastolic pressure in the TX group were smaller than in the SH group ($p < 0.05$). These cardiac parameters did not differ significantly between TX and CN groups, but secondary changes (decreased heart weight, developed ascites, and increased atrial natriuretic peptide concentration) caused by doxorubicin-induced heart failure were most attenuated in the TX group. In the TX group, vascular density was greatest ($p < 0.05$) in the left ventricular free wall and in the septum. In addition, electron microscopy showed that myocardium in the TX group was most maintained.

Conclusion: Bone marrow mononuclear cell transplantation had beneficial effects in doxorubicin-induced cardiomyopathy.

J Heart Lung Transplant 2004;23:436-445.

Cell transplantation is a promising therapy for end-stage heart failure, and has been investigated rigorously, especially in ischemic hearts.¹ Ischemic cardiomyopathy and idiopathic dilated cardiomyopathy (IDCM) are the major reasons for heart transplantation.² In Japan, patients with IDCM occupy 90% of the registration for heart transplantation,³ and heart

transplantation is limited because of the small number of donated hearts. Few reports of cell transplantation in an IDCM model have been published and include studies of fetal cardiomyocytes,⁴ heart cells,⁵ and skeletal myoblasts.⁶

Bone marrow mononuclear cell (BMMNC) transplantation has been investigated⁷⁻⁹ and used clinically for

From the ^aDepartment of Regenerative Medicine and Tissue Engineering, ^bDepartment of Cardiovascular Surgery, ^cDepartment of Organ Transplantation, ^dDepartment of Pathology, and ^eDepartment of Cardiology, National Cardiovascular Center, Osaka, Japan.

Submitted January 22, 2003; revised April 10, 2003; accepted May 8, 2003.

This research was supported in part by a Health Science Research Grant from the Ministry of Health, Labor, and Welfare (Research for Cardiovascular Diseases 13C-1 and Research on the Human Genome, Tissue Engineering Food Biotechnology 12-007) and by a grant-in-aid

for Scientific Research (B) and for Exploratory Research from the Japan Society for the Promotion of Science.

Reprint requests: Dr. Takeshi Nakatani, Department of Organ Transplantation, National Cardiovascular Center, 5-7-1 Fujishirodai, Suita, Osaka, Japan 565-8565. Telephone: +81-6-6833-5012; Fax: +81-6-6872-8160; E-mail: tnakatan@res.ncvc.go.jp

Copyright © 2004 by the International Society for Heart and Lung Transplantation. 1053-2498/04/\$-see front matter. doi:10.1016/S1053-2498(03)00220-1

ischemic heart disease.^{10,11} Bone marrow mononuclear cell transplantation is easy for clinical application because of its simplicity and autologous model. Therefore, this method does not involve the problems of ethics and immune rejection. The cells also are suitable cell sources because of their capacity for differentiation to multipotential progenitor cells and secretion of angiogenic growth factors. However, the efficacy of BMMNC transplantation in IDCM has never been investigated.

In this study, we examined the effect of BMMNC transplantation in doxorubicin-induced cardiomyopathic heart failure in a rat model.

METHODS

Animal Preparation

We used adult male Lewis rats (230–270 g). All procedures, approved by the Animal Care Committee of the National Cardiovascular Center, were performed under the guidelines published in the National Institutes of Health *Guide for the Care and Use of Laboratory Animals* (NIH Publication No. 85-23, revised 1985). The rats were maintained at 22°C with a 12-hour light/dark cycle and had free access to standard rodent chow and tap water.

Preparation of BMMNC

The rats were anesthetized with IM administration of ketamine hydrochloride (3 mg) and IP injection of sodium pentobarbital (10 mg) and heparin (100 U).⁷ After dislocation, both legs were cut and bone marrow was extracted with a 22-gauge needle. The bone marrow cells were transferred to a sterile tube containing phosphate-buffered solution (PBS). The cell suspension was loaded on a Percoll gradient (Lymphoprep, Amersham Biosciences; Piscataway, NJ). The cells were centrifuged at 800g for 20 minutes at 4°C. The top 66% of the total volume was transferred into a tube and then washed with PBS to remove the Percoll. The cell pellet was resuspended with PBS to obtain a concentration of 1×10^6 cells in 40 μ l.

Generation of Doxorubicin-induced Cardiomyopathy and BMMNC Transplantation

We induced heart failure with doxorubicin as described by Suzuki et al.⁶ Briefly, we administered doxorubicin hydrochloride (Sigma Chemical; St. Louis, MO) in 6 equal injections (each containing 2.5 mg/kg in 0.5 ml saline, IP) to 52 Lewis rats during a 2-week period at a total dose of 15 mg/kg. At 4 weeks after the final injection, the rats were divided randomly into 3 groups. Under general anesthesia, we intubated and ventilated the rats at a rate of 180 ml/min, with room air supplemented with oxygen (2 liter/min), using a ventilator (Shinano Medical; Matsuyama, Japan). The heart was exposed through a lateral thoracotomy. In the transplant group (TX, $n = 18$),

BMMNC ($1 \times 10^6/40 \mu$ l) were injected into the left ventricular free wall with a 31-gauge tuberculin syringe. To prevent leakage, we sutured the injection site with 6-0 prolene. In the control group (CN, $n = 18$), we injected 40 μ l PBS into the same region, and in the sham group (SH, $n = 16$), we performed only thoracotomy. We closed the chest with 3-0 prolene in 3 layers.

Measuring Heart Function

We performed echocardiography just before surgery and at 4 weeks after surgery. We used a Sonos 5500 (Hewlett-Packard, UT) equipped with a 7.5-MHz linear transducer. Each rat was anesthetized using a ventilation mask with 1.5% isoflurane and oxygen at 180 ml/min. The anterior chest wall was shaved, and 2-dimensional images and M-mode tracings were recorded from the parasternal short axis view at the level of the papillary muscles. From the M-mode tracings, we obtained the anatomical parameters in diastole and systole.¹² We measured left ventricular diastolic dimension (LVDd), left ventricular systolic dimension (LVDs), fractional shortening (FS), and left ventricular posterior wall thickness (LVPW)/LVDs.

At 7 weeks after surgery, we used a Langendorff apparatus to measure heart function.⁶ After echocardiography, the rat was anti-coagulated with intravenous heparin injection. A mid-line sternotomy was performed, and the heart was removed. The heart was suspended and perfused with filtered Krebs-Henseleit buffer (in NaCl, 118 mmol/liter; KCl, 4.7 mmol/liter; KH_2PO_4 , 1.2 mmol/liter; CaCl_2 , 2.5 mmol/liter; MgSO_4 , 1.2 mmol/liter; NaHCO_3 , 25 mmol/liter; and glucose, 11 mmol/liter; pH 7.4) and equilibrated with 5% CO_2 and 95% O_2 at a pressure of 100 mm Hg. A latex balloon was passed into the left ventricle through the mitral valve and connected to a pressure transducer (Model P231D, Gould Instrument System; Statham, USA), a transducer amplifier (Model AP-641G, Nihon Kohden; Tokyo, Japan), and a differentiator amplifier (Model EQ-601G, Nihon Kohden; Tokyo, Japan). After 20-minute stabilization at a left ventricular end-diastolic pressure of 10 mm Hg, we measured coronary flow in the empty-beating state without pacing. We adjusted the end-diastolic pressure of zero mm Hg by first increasing the balloon volume. We then increased the balloon size by adding water in 20- μ l increments until the total volume was 200 μ l. We recorded left ventricular systolic and diastolic pressures at each balloon volume without pacing and calculated the developed pressure. We weighed the heart, and after laparotomy collected and measured ascites fluid.

Measuring Atrial Natriuretic Peptide

Before harvesting the heart, 4 ml blood was drawn from the right carotid artery to measure the circulating atrial natriuretic peptide (ANP) concentration using radioim-

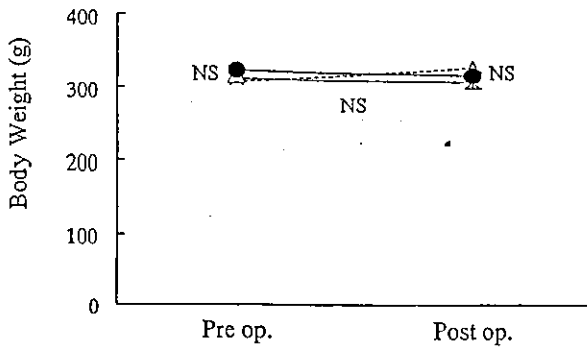


Figure 1. Body weight just before and at 4 weeks after surgery. Body weight after doxorubicin administration gradually decreased or stabilized, and we found no difference among the groups. In each group, body weight did not change from before to after surgery. ●, transplant group; δ, control group; X, sham group.

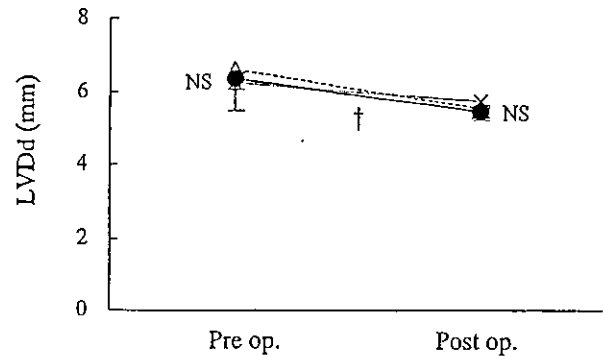


Figure 3. Diastolic left ventricular diameter (LVDd) just before, and at 4 weeks after surgery; LVDd was similar for the 3 groups. In each group, LVDd significantly decreased ($\dagger p < 0.05$). ●, transplant group; δ, control group; X, sham group.

munoassay after extraction with Sep-Pak C18 cartridges (Millipore, Waters; Milford, CT).¹³ We added and investigated normal rats without any procedures ($n = 5$) for ANP and histologic study as a fourth group.

Histologic Studies

At 4 weeks after surgery, we collected tissue samples (0.5 cm³) from the injection site (left ventricular free wall) and the remote area (septum) and fixed the samples in neutralized 10% formaldehyde for histologic study. The samples were embedded and cut to yield 6-μm sections, which were stained with hematoxylin and eosin, as described in the manufacturer's specifications (Sigma Chemical; St. Louis, MO). Sections also were stained for von Willebrand factor. A pathologist and an orthopediatrician investigated bone formation and tumorigenic formation.

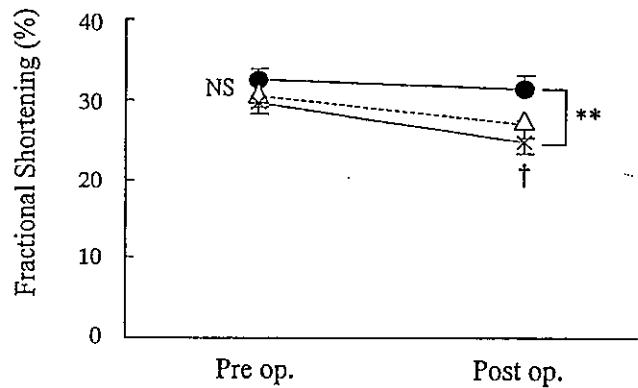


Figure 4. Fractional shortening (FS) just before and at 4 weeks after surgery. The FS was larger in the transplant group (●) than in the sham group (X), $**p < 0.01$, whereas FS did not differ between the control (δ) and sham groups. We found no significant difference between transplant and control groups. In the sham group, FS significantly decreased at 4 weeks after surgery ($\dagger p < 0.05$).

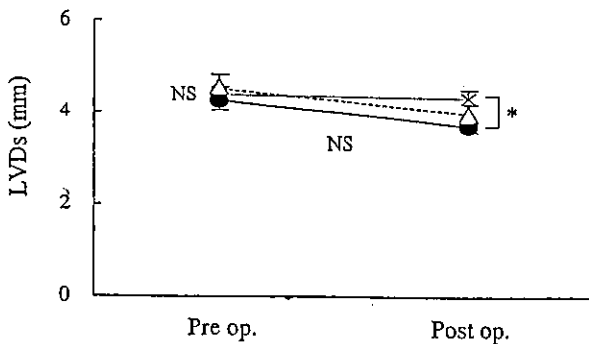


Figure 2. Systolic left ventricular diameter (LVDs) just before, and at 4 weeks after surgery. At 4 weeks after surgery, LVDs was smaller in the transplant group (●) than in the sham group (X), $*p < 0.05$, whereas LVDs in the control group (δ) did not differ from that in the sham group. We found no significant difference between transplant and control groups, and LVDs did not change significantly from before to after surgery in any group.

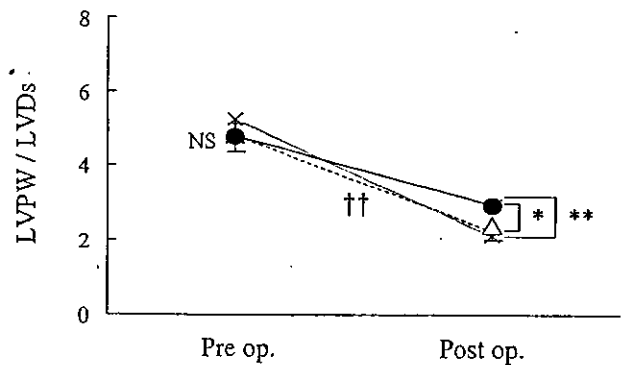


Figure 5. Left ventricular posterior wall thickness (LVPW)/LVDs just before, and at 4 weeks after surgery. The LVPW was the greatest in the transplant group (●, $*p < 0.05$, $**p < 0.01$) at 4 weeks after surgery, although it decreased significantly in all groups ($\dagger\dagger p < 0.01$). X, sham group; δ control group.

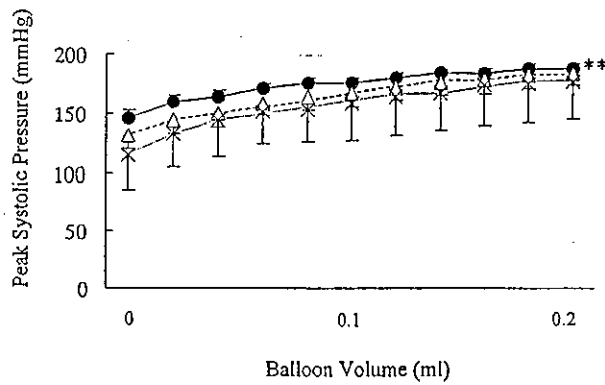


Figure 6. Changes in peak systolic pressure: heart function measured using a Langendorff apparatus at 4 weeks after surgery. Peak systolic pressure was greatest in the transplant group (●), $**p < 0.005$. X, sham group; δ control group.

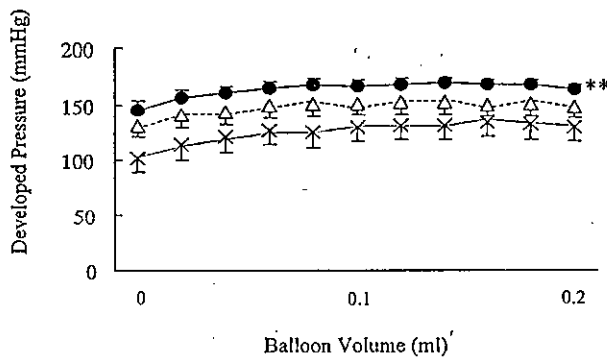


Figure 7. Developed pressure was greatest in the transplant group (●), $**p < 0.0001$. X, sham group; δ control group.

Measuring Vessel Numbers

An observer masked to the treated groups used light microscopy at $\times 10$ magnification to investigate positive vessel staining for von Willebrand factor in the left

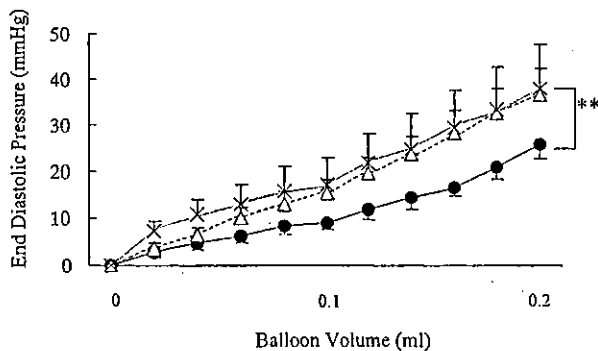


Figure 8. End-diastolic pressure was smaller in the transplant group (●) than in the sham group (X), $**p < 0.0001$. End-diastolic pressure did not differ between the control (δ) and sham groups or between the transplant and control groups, $p = 0.06$.

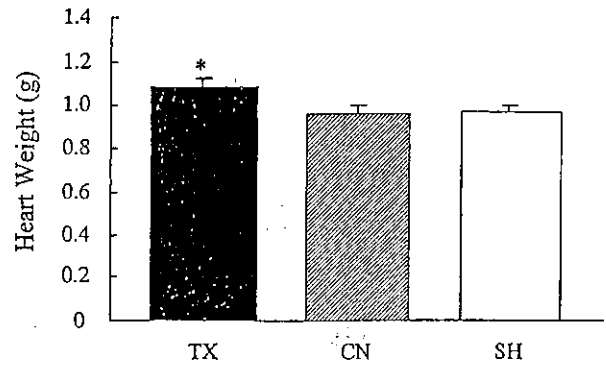


Figure 9. Heart weight at 4 weeks after surgery was greatest in the transplant group (TX), $*p < 0.05$. SH, sham group; CN, control group.

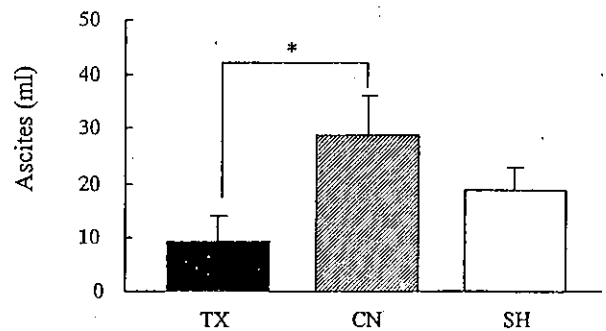


Figure 10. The amount of ascites at 4 weeks after surgery was less in the transplant (TX) group than in the control (CN) group, $*p < 0.05$. SH, sham group.

ventricular free wall (transplant area) and in the septum (remote area) of all groups. Ten high-power fields in each area were selected randomly, and the number of vessels in each was averaged and expressed as the number of vessels per high-power field (HPF).¹⁴

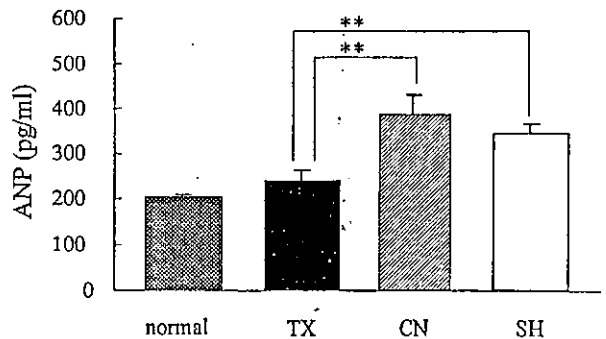


Figure 11. Before harvesting the heart, 4 ml blood was drawn from the right carotid artery to measure circulating atrial natriuretic peptide (ANP) concentration by radioimmunoassay. Blood was sampled in normal rats using the same method as that used in controls (CN). The ANP concentration in the transplant group (TX), which did not differ from that in the normal rats, was significantly less than that in CN and sham (SH) groups, $**p < 0.01$.

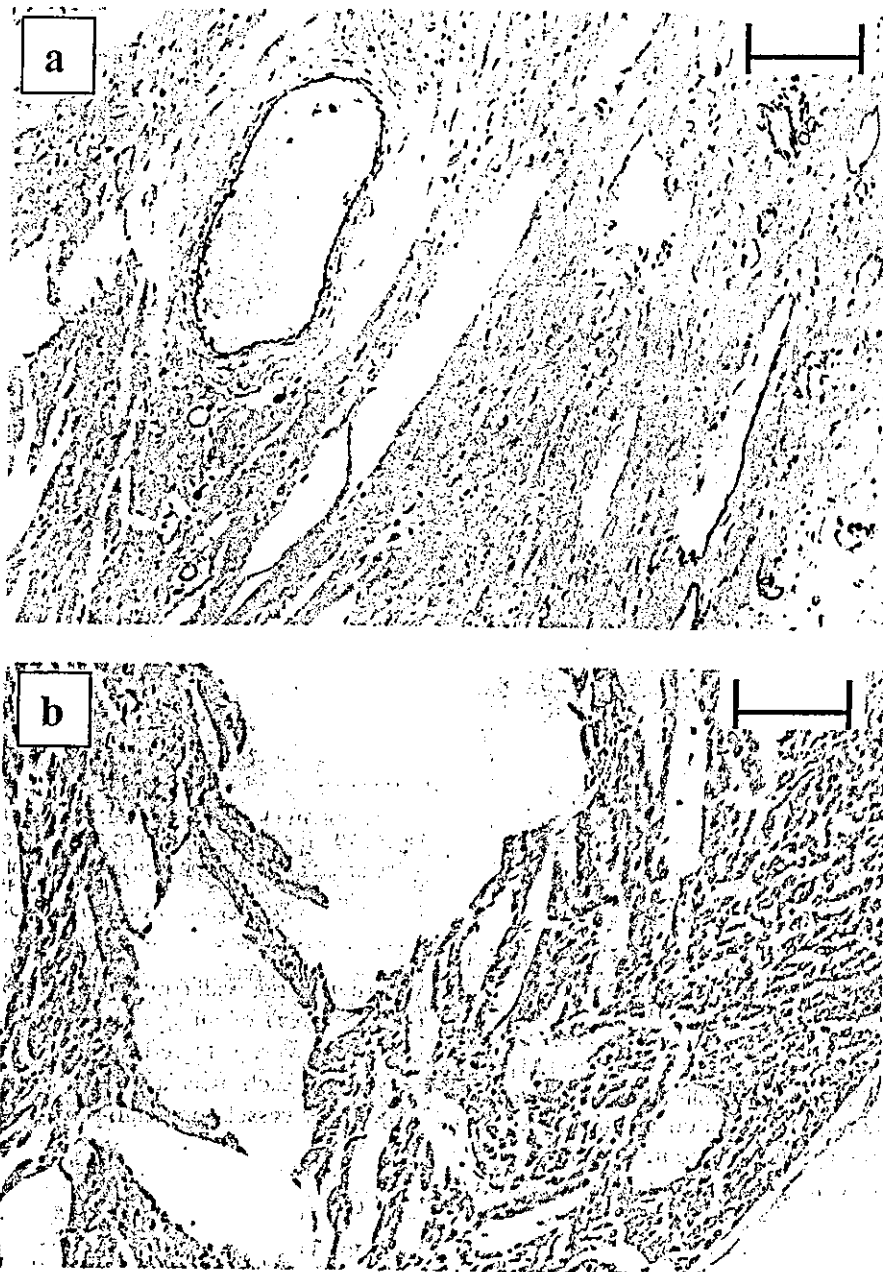


Figure 12. Vessels of the left ventricular free wall (transplant area) stained with von Willebrand factor. a, the transplant group (magnification, $\times 200$); b, the control group (magnification, $\times 200$); and c, the sham group (magnification, $\times 200$). The bar indicates 100 μm . We observed more vessels in the transplant group compared with the control and sham groups. The diameter of most vessels was $< 50 \mu\text{m}$.

Electron Microscopic Study

The samples ($n = 2$ in each group) taken from the injection site were fixed with 3% glutaraldehyde in 0.1 mol/liter cacodylate buffer (pH, 7.2) for 2 hours at 4°C .¹⁵ These samples were then washed several times with the same buffer and post-fixed with 20% osmium tetroxide for 2 hours at 4°C . After this double fixation, the specimens were washed with 0.1% sodium acetate, stained en bloc with 2% uranyl

acetate, washed again with 0.1% sodium acetate, dehydrated through a graded ethanol series, and finally embedded in Spurr's low viscosity resin. Representative areas of each lesion were sectioned at approximately 1 μm thick and stained with toluidine blue solution. Selected areas were trimmed further for thin sectioning and stained with 30% uranyl acetate in 30% ethanol, followed by treatment with Reynolds' lead citrate. The ultra-thin sections were

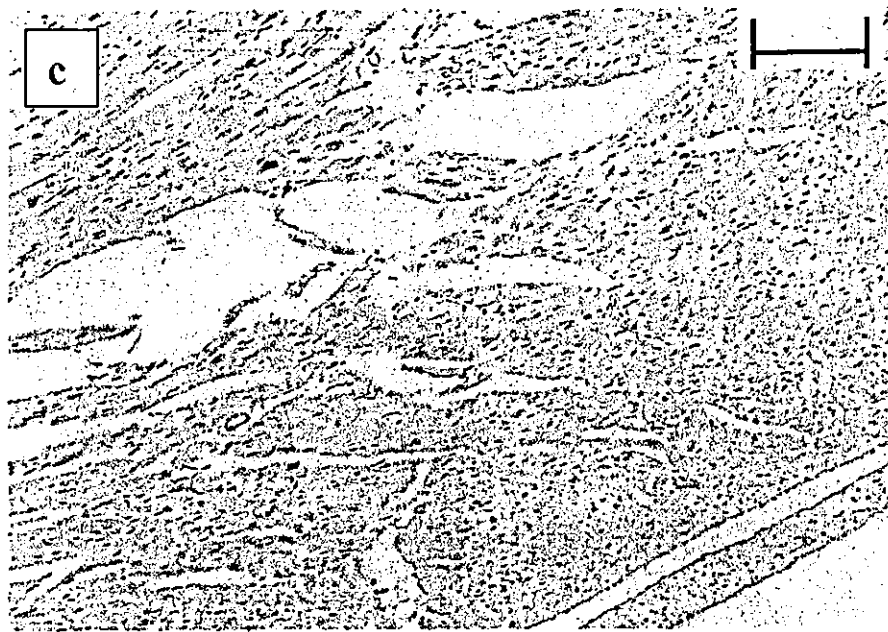


Figure 12. (Continued).

mounted on Veco-R-300 grids, and examined under a Hitachi H-600 electron-microscope operating at 100 kV.

Two pathologists, masked to the treated groups, evaluated and scored cardiotoxicity induced by doxorubicin.¹⁶ The inflammatory change (infiltrating cell number) and vascularity (vessel number) were also counted at $\times 1,000$ magnification. Severity degree was scored as zero = none, 1 = mild, 2 = moderate, and 3 = severe. Eight characteristics of cardiotoxicity were scored with the degree.

Statistical Analysis

All data were expressed as mean \pm standard error. In body weight, heart weight, echocardiographic data, ascites, and

ANP concentration, we measured used non-repeated analysis of variance to compare groups, followed by Bonferroni's multiple comparison test. We used Student's paired *t*-test to compare the data before and after surgery in each group. We analyzed the data that we measured with the Langendorff apparatus using repeated analysis of variance for comparing among groups, followed by Bonferroni's multiple comparison test. We considered $p < 0.05$ as a significant difference.

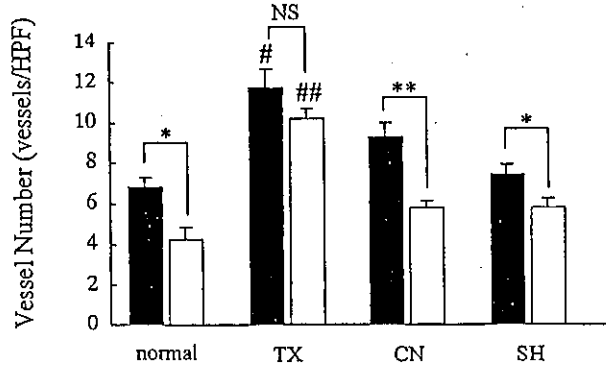


Figure 13. Vessel numbers in the left ventricular free wall (solid bar, transplant area; # $p < 0.05$) and in the septum (open bar, remote area; ## $p < 0.0001$) were greatest in the transplant group (TX). In the other groups, but not into the TX group, the number of vessels in the left ventricular free wall was greater than the number in the septum (* $p < 0.05$, ** $p < 0.005$). CN, control group; SH, sham group.

Table 1. Electron Microscopic Findings

Group	TX	CN	SH
Number of animals	2	2	2
Electron microscopic findings			
1. Loss of myofibrils	1	1	1
2. Fragmentation and sparsity of myofibrils	0	1	1
3. Proliferation of mitochondria	1	2	3
4. Degeneration of mitochondria	1	2	3
5. Widening of intercalated disc	0	0	1
6. Dilatation of endoplasmic reticulum and T tubules	1	2	2
7. Interstitial fibrosis	0	0	0
8. Lipofuscin deposits	0	0	0
Total score	4	8	11
Vessel number	5	3	2
Infiltrating cell number	1	0	0
Irregularity of nucleus	-	-	+

Severity degree: 0, none; 1, mild; 2, moderate; 3, severe.

Total score is sum of scores from 1 to 8.

Infiltrating cell number and vessel number: count number in the field of magnification ($\times 1,000$) -, none; +, yes.

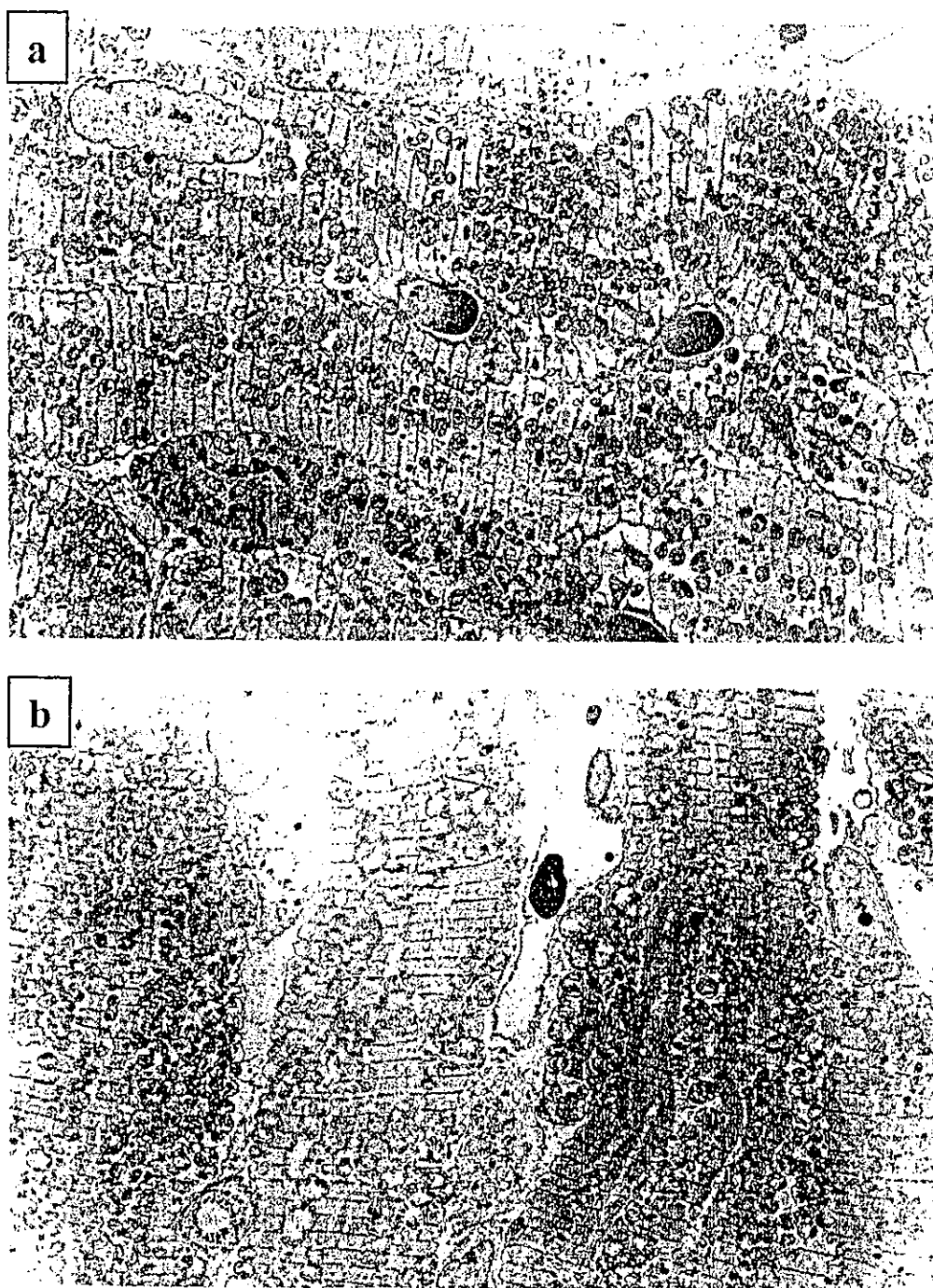


Figure 14. Ultrastructure of myocardium at the injection site. a, the transplant group (magnification, $\times 1,000$): myofibrils were almost well organized. Proliferation of mitochondria was mild. We saw minor change in dilatation of endoplasmic reticulum and T tubules. b, control group (magnification, $\times 1,000$): metamorphic myofibrils were recognized, and endoplasmic reticulum and T tubules were dilated moderately. Proliferation of mitochondria was moderate. c, the sham group (magnification, $\times 1,000$): Metamorphic myofibrils were recognized, and endoplasmic reticulum and T tubules were dilated moderately. Mitochondria proliferated severely, and severe degeneration of mitochondria was observed. We found widened intercalated discs and irregular nuclei.

RESULTS

Mortality Rate

No rats died before surgery. During the 4-week period after surgery, the total mortality rate was

11.5% (16.7% in the TX group, 5.6% in the CN group, and 12.5% in the SH group, $p =$ not significant). At 4 weeks after surgery, we used echocardiography and a Langendorff apparatus to measure heart function in

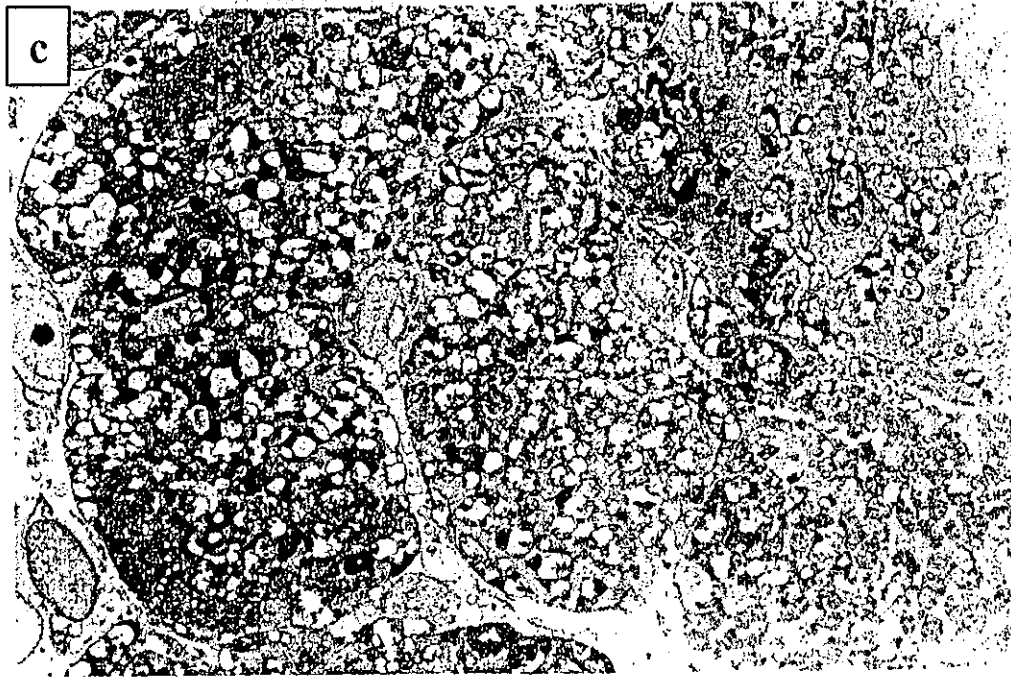

Figure 14. (Continued).

the TX ($n = 15$), CN ($n = 17$), and SH ($n = 14$) groups.

Body Weight

Body weight after doxorubicin administration gradually decreased or stabilized, and we found no difference among the groups. In no group did body weight change significantly from just before to 4 weeks after surgery (Figure 1).

Echocardiography

At 4 weeks after surgery, LVDs in the TX group (3.7 ± 0.1 mm) was smaller than that in the SH group (4.3 ± 0.2 mm, $p = 0.015$), whereas LVDs in the CN group (4.0 ± 0.2 mm) did not differ significantly from that in the SH group ($p = 0.2$). We found no significant difference between TX and CN groups ($p = 0.3$). In no group did LVDs change significantly from before to after surgery (Figure 2).

In each group, LVDd decreased significantly after transplantation ($p < 0.05$, Figure 3). Diastolic left ventricular diameter was similar in the 3 groups.

At 4 weeks after surgery, FS in the TX group ($31.4\% \pm 1.7\%$) was greater than that in the SH group ($24.7\% \pm 1.6\%$, $p = 0.007$), whereas FS in the CN group ($27.3\% \pm 2.2\%$) was not significantly different from that in the SH group ($p = 0.3$). We found no significant difference between the TX and CN groups ($p = 0.1$). In the SH group, FS significantly decreased at 4 weeks after surgery (at 8 weeks after the doxorubicin injection, $p = 0.02$, Figure 4).

Transplant group LVPW/LVDs (2.9 ± 0.2 mm) was the largest of all groups (SH group, 2.1 ± 0.1 mm, $p = 0.005$, and CN group, 2.4 ± 0.2 mm, $p = 0.04$) at 4 weeks after surgery. The CN group did not differ significantly from the SH group ($p = 0.3$). The LVPW/LVDs decreased significantly in all groups compared with before surgery ($p < 0.01$, Figure 5).

Langendorff Apparatus

Heart rate during the assessment did not differ among all groups. Systolic pressure in the TX group was greater than that in the SH group ($p < 0.0001$) and in the CN group ($p = 0.0034$). Systolic pressure in the CN group was not greater than in the SH group ($p = 0.08$, Figure 6). Developed pressure in the TX group was greater than that in the SH group ($p < 0.0001$) and in the CN group ($p < 0.0001$). Developed pressure in the CN group was greater than that in the SH group ($p = 0.0007$, Figure 7). End-diastolic pressure in the TX group was less than that in the SH group ($p < 0.0001$), whereas end-diastolic pressure in the CN group was not less than that in the SH group ($p = 0.07$). The TX group did not differ from the CN group, with a p value of 0.06 (Figure 8).

Heart Weight and Amount of Ascites

The hearts in the TX group were heavier than those in the SH group ($p = 0.021$) and in the CN group ($p = 0.038$). The CN group did not differ from the SH group ($p = 0.8$, Figure 9). The amount of ascites in the TX

group was less than that in the CN group ($p = 0.019$). The TX group did not differ significantly from the SH group ($p = 0.3$, Figure 10).

ANP Concentration

The ANP concentration in the TX group (241.1 ± 19.8 pg/ml), which was not statistically different from that in the normal rats (209.3 ± 9.9 pg/ml, $p = 0.4$), was significantly less than that in the CN group (388.5 ± 41.8 pg/ml, $p = 0.0003$) and in the SH group (344.7 ± 20.4 pg/ml, $p = 0.052$, Figure 11).

Histologic Study

In the hematoxylin and eosin staining, the area of the injection was indistinguishable from other areas, but some rats were distinguished with an inflammatory change in the epicardium caused by the injections. We found no cartilage or bone formation at the transplantation sites.

Vessel Number

In the left ventricular free wall (transplant area), the number of vessels in the TX group (11.7 ± 0.98 vessels/HPF, at $\times 100$ magnification) was larger than in the CN group (9.3 ± 0.8 vessels/HPF, $p = 0.039$) or in the SH group (7.5 ± 0.48 vessels/HPF, $p = 0.0007$, Figure 12). In the transplanted area, we saw much smaller vessels. The diameter of most vessels was < 50 μm . In the septum (remote area), the number of vessels in the TX group (10.2 ± 0.47 vessels/HPF) was larger ($p < 0.0001$) than the number in the CN group (5.8 ± 0.34 vessels/HPF) or in the SH group (5.8 ± 0.43 vessels/HPF). In normal, CN, and SH groups, the number of vessels in the left ventricular free wall was larger than the number in the septum (normal, $p = 0.018$; CN, $p = 0.003$; and SH, $p = 0.047$; Figure 13). In the TX group, we observed more venules than in the CN and SH groups.

Electron Microscopic Study

Table 1 shows semi-quantitative scoring for electron microscopic findings in the 3 groups. We found a trend for the total score in the TX group to be the smallest of all.

In the TX group, myofibrils were almost well-organized. Proliferation of mitochondria was mild. Minor changes included dilatation of the endoplasmic reticulum and the T tubules (Figure 14a).

In contrast, in the SH and the CN groups, we recognized metamorphic myofibrils, and endoplasmic reticulum and T tubules were dilated moderately. Proliferation of mitochondria was severe in the SH group and moderate in the CN group. We found widened intercalated discs and irregular nuclei in the SH group (Figure 14, b and c).

In order, we observed many more vessel in the TX, in the CN, and then in the SH group. The infiltrating cell number was zero or 1 in all groups.

DISCUSSION

We used doxorubicin-induced cardiomyopathy as the model of IDCM. In electron microscopic study, cardiotoxicity was moderate in the hearts of the SH group. We succeeded in creating a heart failure model.

In this study, we showed that BMMNC transplantation had beneficial effects on non-ischemic heart failure, especially for systolic function. The function study, in which we used a Langendorff apparatus, demonstrated the greatest peak systolic pressure and developed pressure (the parameters of systolic function) in the TX group. An increase in systolic pressure without the parallel increase in end-diastolic pressure in the TX group, with increasing balloon volume, suggested that transplantation maintained elasticity instead of stiffness, which also could be changed by inflammation, changes in vasculature, or extracellular matrix. As demonstrated by LVPW/LVDs, transplantation prevented the left ventricular wall from remodeling and may support myocardial reserve for contraction. Although part of the cardiac function data (LVDd, LVDs, FS, and end-diastolic pressure) did not show a significant difference between the TX and the CN groups, it is obvious that results in the TX group were superior to those of the SH group, whereas results in the CN group were similar to those in the SH group.

In addition, secondary changes (decreased heart weight, developed ascites,¹⁷ increased ANP concentration, and destruction of myocardium) caused by doxorubicin-induced heart failure were attenuated by BMMNC transplantation.

Regarding the possible underlying mechanism for improved non-ischemic heart failure after cell transplantation, several paracrine factors released from transplanted cells have been suggested.^{4,5} In the ischemic heart model, BMMNC transplantation works as an enhancer for angiogenic ligands beta fibrogenic growth factor (bFGF), vascular endothelial growth factor (VEGF),⁹ insulin-like growth factor 1,¹⁸ and angiopoietin 1 and cytokines (interleukin-1 β and tumor necrosis factor- α).⁸

In this study, BMMNC transplantation increased blood vessel density not only in the left ventricular free wall (transplant area) but also in the septum (remote area), and we found no significant difference between the 2 areas. In the normal and SH groups, we showed significant difference between the left ventricular free wall and the septum, suggesting that vascular density was originally greater in the left ventricular free wall than in the septum, and the difference was greater in the CN group, suggesting

that the injection itself induced angiogenesis at the injection site.¹⁹ Electron microscopic study showed that the structure of myocardium in the TX group clearly was maintained, with many more vessels than in the SH or CN groups.

Considering previous reports^{4,5,8,9,18} and our observations, the possible mechanism by which BMMNC transplantation was beneficial in doxorubicin-induced cardiomyopathy may have been the following: The BMMNC transplantation induced angiogenesis in the whole heart. Microcirculation improved by angiogenesis could contribute to preserving myocardium. Preserved myocardium might have contributed to preventing deterioration of cardiac function.

This study had several limitations. We did not label transplanted BMMNC for identification, because labeling technique may compromise cell function.²⁰ Our main aim was to verify the efficacy of BMMNC transplantation. Further studies of dose response, fate of transplanted cells, and long-term effect should be conducted.

In conclusion, BMMNC transplantation had beneficial effects in non-ischemic heart failure: doxorubicin-induced cardiomyopathy in rats.

The authors thank Dr. Ohgushi (Tissue Engineering Research Center, National Institute of Advanced Industrial Science of Technology, Japan) for investigating bone formation and tumorigenic formation, K. Hattori for her help in feeding the rats, and Mr. Masuda for his technical assistance in the histologic study.

REFERENCES

1. Menasche P, Hagege AA, Scorsin M, et al. Myoblast transplantation for heart failure. *Lancet* 2001;357:279-80.
2. Hosenpud JD, Bennett LE, Keck BM, Fiore B, Boucek MM, Novick RJ. The Registry of the International Society for Heart and Lung Transplantation: fifteenth official report—1998. *J Heart Lung Transplant* 1998;17:656-68.
3. Hori M, Yamamoto K, Kodama K, et al. Successful launch of cardiac transplantation in Japan. Osaka University Cardiac Transplant Program. *Jpn Circ J* 2000;64:326-32.
4. Scorsin M, Hagege AA, Dolizy I, et al. Can cellular transplantation improve function in doxorubicin-induced heart failure? *Circulation* 1998;98(suppl 19):II151-5.
5. Yoo KJ, Li RK, Weisel RD, et al. Heart cell transplantation improves heart function in dilated cardiomyopathic hamsters. *Circulation* 2000;102(suppl 3):III204-9.
6. Suzuki K, Murtaza B, Suzuki N, Smolenski RT, Yacoub MH. Intracoronary infusion of skeletal myoblasts improves cardiac function in doxorubicin-induced heart failure. *Circulation* 2001;104(suppl 1):I213-7.
7. Hamano K, Li TS, Kobayashi T, Kobayashi S, Matsuzaki M, Esato K. Angiogenesis induced by the implantation of self-bone marrow cells: a new material for therapeutic angiogenesis. *Cell Transplant* 2000;9:439-43.
8. Kamihata H, Matsubara H, Nishijue T, et al. Implantation of bone marrow mononuclear cells into ischemic myocardium enhances collateral perfusion and regional function via side supply of angioblasts, angiogenic ligands, and cytokines. *Circulation* 2001;104:1046-52.
9. Fuchs S, Baffour R, Zhou YF, et al. Transendocardial delivery of autologous bone marrow enhances collateral perfusion and regional function in pigs with chronic experimental myocardial ischemia. *J Am Coll Cardiol* 2001;37:1726-32.
10. Tateishi-Yuyama E, Matsubara H, Murohara T, et al. Therapeutic angiogenesis for patients with limb ischemia by autologous transplantation of bone-marrow cells: a pilot study and a randomized controlled trial. *Lancet* 2002;360:427-35.
11. Strauer BE, Brehm M, Zeus T, et al. Repair of infarcted myocardium by autologous intracoronary mononuclear bone marrow cell transplantation in humans. *Circulation* 2002;106:1913-8.
12. Pollick C, Hale SL, Kloner RA. Echocardiographic and cardiac Doppler assessment of mice. *J Am Soc Echocardiogr* 1995;8:602-10.
13. Miyata A, Kangawa K, Matsuo H. Molecular forms of atrial natriuretic peptides in rat tissues and plasma. *J Hypertens Suppl* 1986;4:2:89-11.
14. Kim EJ, Li RK, Weisel RD, et al. Angiogenesis by endothelial cell transplantation. *J Thorac Cardiovasc Surg* 2001;122:963-71.
15. Takaichi S, Yutani C, Fujita H, Yamamoto A. Ultrastructural studies on the phenotypic modulation of human intimal smooth muscle cells. *Atherosclerosis* 1993;100:197-211.
16. Sekiguchi M, Haze K, Hiroe M, Konno S, Hirohara K. Interrelation of left ventricular function and myocardial ultrastructure as assessed by endomyocardial biopsy: comparative study of hypertrophic and congestive cardiomyopathies. *Recent Adv Stud Cardiac Struct Metab* 1976;12:327-34.
17. Siveski-Iliskovic N, Hill M, Chow DA, Singal PK. Probucol protects against Adriamycin cardiomyopathy without interfering with its antitumor effect. *Circulation* 1995;91:10-5.
18. Kveiborg M, Flyvbjerg A, Eriksen EF, Kassem M. Transforming growth factor-beta1 stimulates the production of insulin-like growth factor-I and insulin-like growth factor-binding protein-3 in human bone marrow stromal osteoblast progenitors. *J Endocrinol* 2001;169:549-61.
19. Saito T, Pelletier MP, Shennib H, Gaiad A. Nitric oxide system in needle-induced transmural myocardial revascularization. *Ann Thorac Surg* 2001;72:129-36.
20. Fukuhara S, Tomita S, Nakatani T, et al. Comparison of cell labeling procedures for bone marrow cell transplantation to treat heart failure: long-term quantitative analysis. *Transplant Proc* 2002;34:2718-21.

Granulocyte-Colony Stimulating Factor Enhanced the Recruitment of Bone Marrow Cells into the Heart

Time Course Evaluation of Phenotypic Differentiation in the Doxorubicin-induced Cardiomyopathic Model

Objective: We traced and evaluated bone marrow-derived cells after granulocyte-colony stimulating factor (G-CSF) treatment in the doxorubicin-induced cardiomyopathic heart in the time course. **Methods:** C57BL/6 male mice received doxorubicin (15 mg/kg, i.p.). At 1 week after administration of doxorubicin, the mice were irradiated (900 cGy) followed by transplantation of bone marrow cells (BMT) derived from transgenic mice expressing green fluorescent protein (GFP) (1×10^6) via a tail vein (BMT). G-group (n=22) received G-CSF (50 μ g/kg/day \times 8 days, s.c.) after BMT, while C-group (n=17) received saline. At 4 and 7 weeks after BMT, heart sections were fixed to evaluate bone marrow-derived GFP cells (BMD-GFP) with immunostaining for Troponin I (TnI), atrial-natriuretic peptide (ANP), connexin 43, von Willebrand factor, and Ki67. **Result:** There were migrated BMD-GFP in the whole heart of all animals. In the time course, migrated BMD-GFP increased in G-group. At 7 weeks the number of migrated BMD-GFP in G-group (56.2 ± 15.6 /HPF) was larger than that in C-group (18.9 ± 10.7 /HPF) ($p < 0.05$). TnI- and connexin 43-positive BMD-GFP were spindle-shaped. Von Willebrand factor-positive BMD-GFP showed thinner-shape. ANP- and Ki67-positive BMD-GFP showed oval-shape. The numbers of these positive cells derived from BMD-GFP, not different between the 2 groups, did not change from 4 to 7 weeks. **Conclusion:** The migration of BMD-GFP into the heart increased from 4 to 7 weeks after BMT by G-CSF. However, cardiomyocytes and endothelial cells originating from BMD-GFP were very few and neither increased nor changed in their shapes and numbers in the short term. (*Jpn J Thorac Cardiovasc Surg* 2004; 52: 451–455)

Key words: granulocyte-colony stimulating factor, bone marrow cells, doxorubicin-induced cardiomyopathy, migration, phenotypic change

Yosuke Hisashi MD,¹ Shinji Tomita MD,^{1,2} Takeshi Nakatani MD,³ Shinya Fukuhara MD,¹ Chikao Yutani MD,⁴ and Soichiro Kitamura MD.²

Cell-based therapy is a promising treatment for end-staged heart failure. In contrast to the exogenous-cell transplantation, regeneration of myocardium by endogenous-stem cell was reported.¹

From Departments of ¹Regenerative Medicine and Tissue Engineering, ²Cardiovascular Surgery, ³Organ Transplantation, and ⁴Pathology, National Cardiovascular Center, Osaka, Japan.

Received for publication December 18, 2003.

Accepted for publication May 10, 2004.

Address for reprints: Shinji Tomita, MD, Department of Regenerative Medicine and Tissue Engineering, National Cardiovascular Research Institute, 5-7-1 Fujishirodai, Suita, Osaka 565-8565, Japan.

Orlic et al. applied granulocyte-colony stimulating factor (G-CSF) and stem-cell factor to enhance regeneration of myocardium by endogenous-stem cells.² In addition, we proved that a source of cardiac-stem cell was bone marrow in the infarction model.³ However, the mechanism of endogenous-stem cells is unknown in detail.

In this study, we traced and evaluated bone marrow-derived cells after G-CSF treatment in the doxorubicin-induced cardiomyopathic heart in the time course.

Subjects and Methods

Animal model. C57BL/6 at 8 weeks (25 g) were purchased from a licensed vendor. All animals received