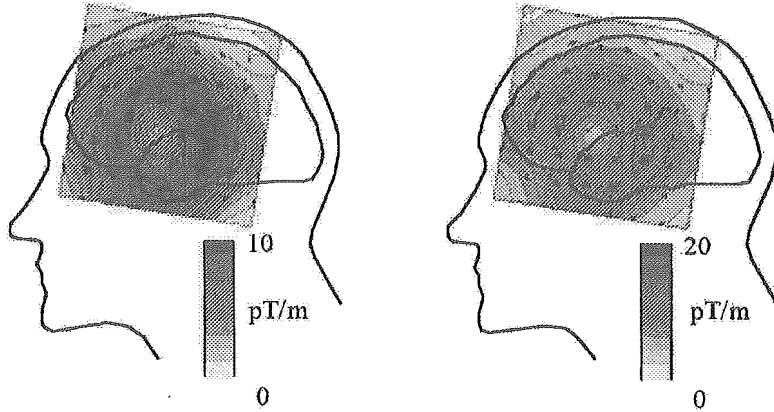


Left temporal lobe

Negative waveform pattern Positive waveform pattern



Right temporal lobe

Negative waveform pattern Positive waveform pattern

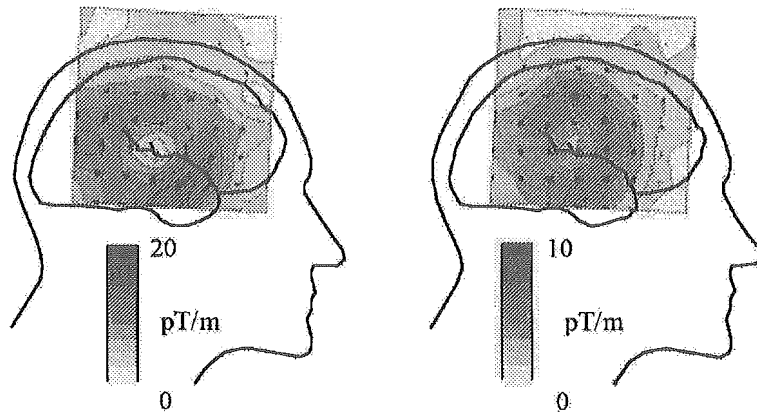


Fig. 2 Current-arrow maps at the peak in the epileptic waveforms in left and right temporal lobes